

A case report of haemothorax associated with asymptomatic pancreatic pseudo cyst

Gitartha Baruah^{1,*}, Anand Yannawar², Sanjay Gabhale³

¹Junior Resident, ²Assistant Professor, ³Senior Resident, Dr. D.Y. Patil Medical College, Hospital, & Research Centre, Pimpri, Maharashtra, India

***Corresponding Author: Gitartha Baruah**

Email: baruahgitartha@gmail.com

Abstract

Haemothorax is the presence of significant amount of blood in the pleural space. Pleural pathology is an uncommon complication of pancreatitis while massive haemothorax due to pathology in pancreas is extremely rare. The case report is about a 32 years old chronic alcoholic presented with breathlessness in the emergency department. On evaluating the case, we found a rare association of haemothorax with pancreatic pseudocyst. Also it is important to note that a significant number of pleural pathologies remain undiagnosed and an intra abdominal cause is often overlooked leading to delay in diagnosis.

Keywords: Haemothorax; Pancreatic pseudocyst.

Introduction

Haemothorax is the presence of significant amount of blood in the pleural space [1]. A haemothorax is considered when the haematocrit of the pleura fluid is equal to or more than 50% of the peripheral blood haematocrit [2]. Trauma is the most common cause while non-traumatic causes are distinctly uncommon. Comprehensive history taking, physical examination, thoracentesis and imaging studies are useful in diagnosing these conditions. An unusually overlooked cause of pleural pathology is an intra-abdominal process while haemothorax caused by pancreatic disease is highly rare [1,3].

Case Report

A 32 years old male patient reported to the emergency department with symptoms of breathlessness and cough since 3 days. There was no history of trauma, bleeding diathesis or intake of oral anticoagulant. On physical examination his RR was 28/min Spo2 95pc on room air, dull note on percussion and decreased breath sounds were noted on left thorax. Abdominal examination was insignificant. Chest radiograph showed massive left sided pleural effusion with deviation of trachea to the opposite side (Fig. 1). Accordingly, diagnostic thoracentesis was performed which revealed haemorrhagic pleural fluid. Fluid was sent for routine investigations. Pleural fluid protein was 5.4 gm%, LDH 2039 IU/L, Sugar 43 mg% and predominately neutrophilic. According to lights criteria, fluid was exudative and pleural fluid haematocrit was more than 50pc of peripheral blood haematocrit. After that chest tube drainage was planned and Pig tail catheter (16f) was introduced in left 6th inter costal space in mid axillary line. Total cumulative drainage over 5 days was 3000ml and the repeat chest x ray after 5 days showed minimal pleural effusion (Fig. 2). As the case had a history of chronic intake of alcohol, pleural fluid analysis for pancreatic amylase was done which came out to be 2812 IU/L. Further, CT abdomen & pelvis was done which revealed acute on chronic pancreatic pseudocyst & left sided pleural effusion with compression collapse of the under lying lung. (Fig. 3) The pancreatic pseudocyst was managed conservatively with

antibiotics as the size of the pseudocyst was very small. (17.2mm * 14.3mm)

He remained asymptomatic after 2 months of follow up with chest X-ray showing no abnormality and USG abdomen showing resolution of the pancreatic pseudocyst. Hence no surgical intervention was done for pancreatic pseudocyst.

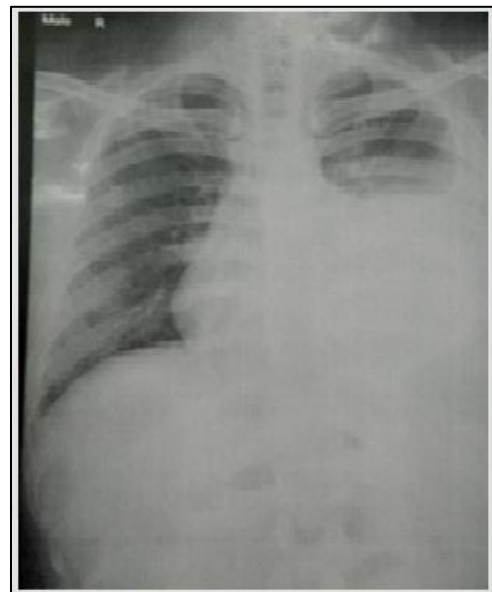


Fig. 1: Chest radiograph reveals massive left-sided pleural effusion

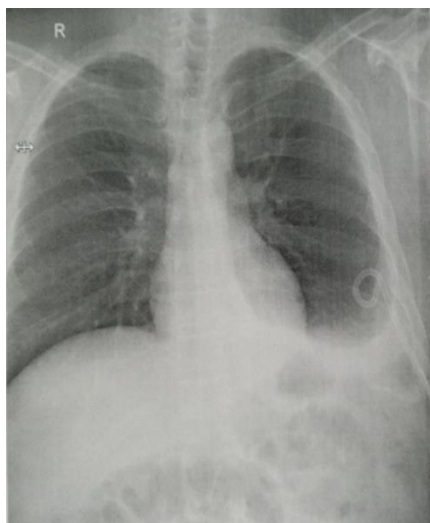


Fig. 2: Chest radiograph day 5 post pig tail insertion

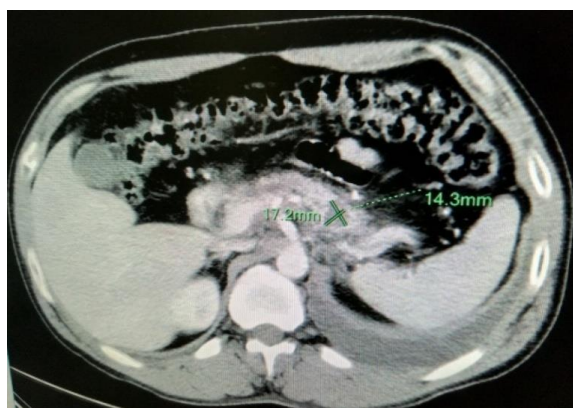

Fig. 3: CT scan showed a pancreatic pseudocyst (17.2mm * 14.3mm)

Discussion

Non traumatic factors are the least common causes of haemothorax. Left sided haemothorax due to pancreatic pathology is rare [1]. Hemorrhagic pleural effusion is common in alcoholics which has a peak incidence between 20-55 years of age [4]. Pancreatic enzymes coming in contact with the diaphragm, haematogenous transfer of pancreatic enzymes into the pleura, pleuroperitoneal fistula and pseudocyst having a direct communication with the pleural cavity are the various mechanisms which can lead to the formation of pleural effusion in pancreatitis.

A pseudocyst is a collection of amylase rich fluid enclosed in a wall of fibrosis or granulation tissue. The treatment of pancreatic pseudocysts are based on the clinical examination, symptoms, stage and size of the pseudocyst, and also on the degree of complications. At the initial level, non-invasive treatment is usually indicated whose main role is to lower the pancreatic exocrine secretion and promote sealing of the pancreatic ductal disruption. CT scan and Ultrasound of the abdomen are usually done to identify pseudocyst of pancreas. Radiological and proper scenario are used to differentiate pseudocyst from an abscess or ascitic fluid accumulation. In its management ERCP and MRCP is of

great help as it demonstrate communication of the cyst with the pancreatic duct system, and also helps in detecting ductal anomalies and chronic pancreatitis. Most of the pseudocysts will resolve spontaneously, but in thick wall pseudocyst (more than 6cm in diameter), pseudocyst lasting for more than 12 or those associated with chronic pancreatitis are less likely to resolve spontaneously [5]. Therapeutic interventions are recommended in symptomatic cases of pseudocyst, or where complications develop and in cases where distinction has to be made between pseudocyst and tumour [6]. Bleeding, fistula formation, infection are some of the common complication associated with pseudocyst [1]. In the present case, the patient was diagnosed as left sided haemothorax due to pseudocyst pancreas. As the patient was asymptomatic and size of pseudocyst was very small (17.2mm * 14.3mm) no surgical intervention was done and was successfully managed conservatively with antibiotics.

Conclusions

Haemothorax due to pancreatic pathologies are extremely rare. There are about 15% of pleural effusion cases where diagnosis are not readily found it is always advisable to rule out abdominal abnormality using a CT scan. Moreover, pleural fluid amylase estimation with or without pain abdomen in cases of left sided exudative pleural effusion should be done to avoid any undue delay in diagnosis. Thus, pseudocyst of pancreas should always be kept in mind as a cause of undiagnosed haemothorax.

Conflicts of Interest: None declared

Acknowledgements: Nil

References

1. Li CC, Hsu CW, Li CZ, Kuo SM, Wu YC. Successful treatment of a pancreatic pseudocyst accompanied by massive hemothorax: a case report. *J Med Case Rep* 2015;9:295.
2. Light RW. *Pleural disease: 6th edition*:405
3. Dixit R, Sharma S, Dave L. Massive haemothorax in asymptomatic pseudocyst pancreas. *Lung India*. 2008;25:126-128
4. Sachdeva R, Sachdeva R. Hemorrhagic pleural effusion due to pseudo- pancreatic cyst. *Adv Biomed Res* 2016;2:3.
5. Sandberg A, Eiriksson AK, Glomsaker T, Maleckas A. Treatment of pancreatic pseudocysts. *Scand J Surg* 2005;94(2):165-175.
6. Bailey, Love. *Short practice of surgery*. Pp1144-45.

How to cite this article: Baruah G, Yannawar A, Gabhale S. A case report of haemothorax associated with asymptomatic pancreatic pseudo cyst. *Indian J Immunol Respir Med* 2019;4(1):73-74.