

Clinicopathological profile of lung cancer in a teaching hospital in Eastern India

Snehal Baban Jadhav^{1,*}, Dipti Aniruddha Kadam²

¹Assistant Professor, Dept. of Respiratory Medicine, ESI-PGIMSR, ESIC Medical College and ESIC hospital & ODC, Kolkata, West Bengal, ²Senior Resident, Dept. of Pathology, ESI Post Graduate Institute of Medical Science and Research, Mumbai, Maharashtra, India

***Corresponding Author:**

Email: drjadhavsb1212@gmail.com

Abstract

Background: There is a sharp rise in the occurrence of lung malignancy in recent years with considerable change in clinical and pathological course. Lung cancer is vigorous in nature with poor outcome.

Objective: Our study intends to assess clinicopathological aspects of patients with lung malignancy in Eastern India.

Methodology: We retrospectively assessed the inpatient documents of histopathologically proven cases of primary lung malignancy from July 2016 to June 2018.

Results: We enrolled 63 patients of lung cancer. The disease showed 77.7% male predominance (M:F 3.5:1) and 73% occurrence in smokers. Majority of our patient (52.3%) aged greater than 60 years with an average age of 60.36 years. Productive cough in 95.2% and tumour mass in 85.7% was the common symptom and radiological presentation respectively. Histologically adenocarcinoma was seen in 66.67% of the patient and prevailed over 28.57% of squamous cell carcinoma.

Conclusions: Adenocarcinoma of lung exceeds the decade old prevalent squamous cell carcinoma.

Keywords: Lung cancer; Productive cough; Lung mass; Adenocarcinoma.

Introduction

Among all the new cancers detected annually lung cancer accounts 18 lakh cases[1]. In India Takiar et al. reported 57,795 new cases in 2010 and projected it to rise annually to 67,000 by 2020[2]. Smoking culture and regional variations influences the epidemiological and pathological trend of lung cancer. Squamous cell carcinoma once predominant cell type is now found below adenocarcinoma in occurrence in western and most Asian countries[3,4].

We undertook this study to assess the change in clinical and histopathological aspects of lung malignancy in single center in the Eastern region of India.

Materials and Methods

On retrospective analysis confirmed cases of lung cancer admitted during July 2016 to June 2018 in our institute were enrolled. Patients with rare lung cancer, cancers of lymphoid and secondary nature were eliminated. Records pertaining to demography, smoking, symptoms, radiology and variants of histopathology were noted. These patients had undergone Fibreoptic bronchoscopy (FOB) and or percutaneous Trucut biopsy from lung mass under image guidance. Wherever appropriate pleural fluid, loco regional or distant lymph node sampling for cell block was done. 18 F- Fluorodeoxy glucose positron emission tomography scan (FDG—PET) of whole body and Magnetic resonance imaging (MRI) of brain was done for disease staging.

Results

The study included 63 patients of cytologically and histologically proven bronchogenic carcinoma. Among these patients male are 49 (77.7%) and 14 (22.3%) are females (Table 1). There is an overall male predominance with M:F ratio 3.5:1. Male smokers are 46 (77%) and female smokers are 17 (27%) (Table 1). The numbers of male and female smoker are 44 and 2 respectively. Smoker to non smoker ratio is 2.7:1. Productive cough was the cardinal symptom (95.2%) (Table 2). Chest radiograph and computed tomogram of chest in most patient showed mass lesion (n=54, 85.7%) (Table 3). Adenocarcinoma (66.7%) was the most frequent histopathological variant of lung cancer.

Discussion

Recently India has noticed sharp rise in incidence of lung cancer. Worldwide, men are more frequently affected than women with lung cancer due to high incidence of smoking in them. However, in western world this gender gap is narrowing which is best explained by relative increase in smoking habits in women[5,6]. In our study also we observed men being affected more than women with male:female ratio of 3.5:1. This male predominance has been observed in various studies from India over the last few decades[7-10]. Tobacco smoking has strong correlation with lung cancer and is the single most important risk factor. The risk increases with an increase in exposure. Nearly 73% of our study population was smoker with majority being male. The smoking habit was significantly less among female population in our study. This indicates the possibility of other compounding factors like environmental tobacco smoke, air pollution and genetic

factors. The mean age of diagnosis in our study was 60.36 years and was comparable with other Indian studies. The majority of our patient had productive cough as cardinal symptom. Radiologically unilateral mass lesion was the common finding. Image guided modality in the form of computed tomography was the most common diagnostic modality used in our study. The yield of this modality was 70% compared to 20% by Fibreoptic bronchoscopy (FOB). Ultrasonography (USG)/Computed tomography of chest was commonly used for peripheral lesions which were beyond the bronchoscopic vision. Majority of lung lesions in our study group were peripheral in location. Whole body FDG-PET CT and contrast enhanced MRI Brain was done to stage the disease. Advanced stage disease was observed in 90% of our study population which impacts the quality of life directly. In our study adenocarcinoma was seen in 66.67% of the patient and prevailed over 28.57% of squamous cell carcinoma [Fig. 1]. This is in contrast to most of the older Indian studies which observed squamous cell carcinoma (SCC) as predominant subtype. However studies in recent past by Krishnamurthy et al. Noronha et al. and Mallick et al. observed ADC as common histological variant of lung cancer accounting for 42.6%, 43.8% and 37.3% respectively[10-12]. This paradigm shift in histopathology seems to be attributable to certain extent to change in smoking habits and industrialization.

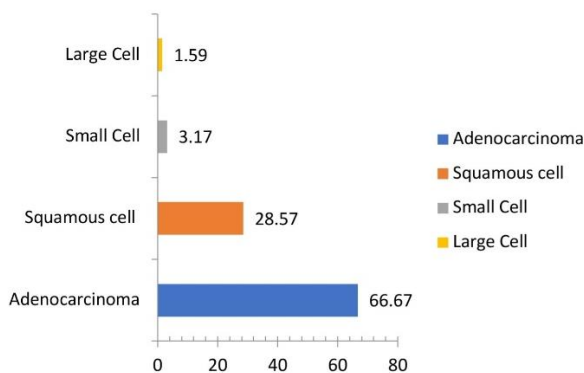


Fig. 1: Percentage distribution of histopathological subtypes of primary lung cancer

Table 1: Percentage distribution of the demographic profile of lung cancer patients (n=63)

Age group	No. of patients	Percentage
< 40	2	31.7
41– 60	28	44.4
>60	33	52.3
Gender		
Male	49	77.7
Female	14	22.3
Smoking status		
Smoker	46	73.0
Nonsmoker	17	27.0

Table 2: Percentage distribution of Clinical manifestations (n=63)

Symptoms	No. of Patients (n=63)	Percentage
Cough	60	95.2
Dyspnoea	48	76.1
Chest Pain	37	58.7
Haemoptysis	30	47.6
Fever	21	33.3
Hoarseness of voice	03	04.76
SVC obstruction	02	03.17

Table 3: Percentage distribution of radiological features

Radiological presentation	Frequency	Percentage
Mass	54	85.7
Nodule	05	07.9
Pleural effusion	10	15.8
Consolidation	05	07.9

Conclusion

In India majority of lung cancer patients at presentation have advanced disease. Adenocarcinoma now exceeds the decade old prevalent squamous cell histology in most regions of India.

Conflicts of interest: None declared.

Acknowledgements: Nil.

References

1. Ferlay J, Soerjomataram I, Ervik M, Forman D, Bray F, Globocan 2012; Estimated Cancer Incidence, Mortality and Prevalence Worldwide in 2012. *Int J Cancer* 2014;13.
2. Takiar R, Nadayil D, Nandakumar A. Projections of number of cancer cases in India (2010-2020) by cancer groups. *Asian Pac J Cancer Prev* 2010;11:1045-9.
3. Valaitis J, Warren S, Gamble D. Increasing incidence of adenocarcinoma of lung. *Cancer* 1981;47:1042-6.
4. Janssen –Heijnen MLG, Coebergh J-WW. The changing epidemiology of lung cancer in Europe. *Lung Cancer* 2003;41:245-58.
5. Ouellette D, Desbiens G, Emond C, Beauchamp G. Lung Cancer in women compared with men: stage, treatment, and survival. *Ann Thorac Surg* 1998;66:1140-3.
6. Ferguson MK, Wang J, Hoffman PC, Haraf DJ, Olak J, Masters GA, et al. Sex- associated differences in survival of patients undergoing resection for lung cancer. *Ann Thorac Surg* 2000;69:245-9.
7. Guleria JS, Gopinath N, Talwar JR, Bhargave S, Pande JN, Gupta RG. Bronchial carcinoma- an analysis of 120 cases. *J Assoc Physicians India* 1971;19:251-5.
8. Jindal SK, Behera D. Clinical spectrum of primary lung cancer: Review of Chandigarh experience of 10 years. *Lung India* 1990;94-8.
9. Gupta RC, Purohit SD, Sharma MP, Bhardwaj S. Primary bronchogenic carcinoma: clinical profile of 279 cases from mid-west Rajasthan. *Indian J Chest Dis Allied Sci* 1998;40:109-16.

10. Krishnamurthy A, Vijayalakshmi R, Gadigi V, Ranganathan R, Sagar TG. The relevance of “Nonsmoking- associated lung cancer” in India: a single- centre experience. *Indian J Cancer* 2012;49:82-8.
11. Noronha V, Dikshit R, Raut N, Joshi A, Pramesh CS, George K, et al. Epidemiology of lung cancer in India: focus on the differences between non-smokers and smokers: a single-centre experience. *Indian J Cancer* 2012;49:74-81.
12. Malik PS, Sharma MC, Mohanti BK, Shukla NK, Deo S, Mohan et al. Clinico-pathological profile of lung cancer at AIIMS: a changing paradigm in India. *Asian Pac J Cancer Prev* 2013;14:489-94.

How to cite this article: Jadhav S. B, Kadam D. A. Clinicopathological profile of lung cancer in a teaching hospital in Eastern India. *Indian J Immunol Respir Med.* 2018;3(4):193-195.