

Tenosynovitis of flexor tendons of hand: Tubercular etiology

Amit Jadhav¹, Mayur V. Devraj^{2*}, B. B. Sonawane³

¹Consultant Plastic Surgeon, Dept. of Surgery, ²Associate Professor, Dept. of Chest & Tuberculosis, ³Professor, Dept. of Pathology, SMBT Institute of Medical Science and Research Center, Maharashtra University of Health Sciences, Nashik, Maharashtra, India

***Corresponding Author:**

Email: mayurdevraj@gmail.com

Abstract

Extra-pulmonary Tuberculosis (EPTB), 10% about is musculoskeletal cases. A middle age female who presented to outpatient department of tertiary care center (Medical college & Hospital) with swelling over volar surface of right distal forearm gradually increased in size over 9 to 10 months. She noticed difficulty to move fingers of right hand as size of swelling increasing. She had tingling sensation in the territory of median nerve. It was single swelling of 05cm x 07cm over the volar surface of right distal forearm with defined margins. Lesion was open surgically and rice bodies were found. Histopathological examination had shown caseous type of necrosis and granuloma formation suggestive of tuberculosis. Anti-tuberculosis treatment was given to her. Cases of TB tenosynovitis are uncommon and diagnosis is often missed causing delay of treatment to patient. Surgical intervention decided by symptoms and signs. Antitubercular therapy and excision of lesion produce good outcome.

Keywords: Anti TB treatment; Rice Bodies; Surgical excision; Tenosynovitis.

Introduction:

Infection of Mycobacterium tuberculosis can involve any organ of the body and its clinical presentation is atypical at times. 10% of extra pulmonary tuberculosis is musculoskeletal [1]. Tuberculosis of hand or wrist joint is uncommon and it manifests as osteomyelitis or dactylitis [2]. Tenosynovitis is commonest form among the EPTB involving hand/wrist joint. It has been found that flexor aspect usually involved than extensor aspect and similarly involvement of ulnar side is more than the radial side. Arms are commonly involved in Tenosynovitis, very often the dominant arm [3]. The diagnosis is often missed due to the presence of nonspecific clinical signs leads to another clinical condition such as a ganglion, carpal tunnel syndrome, and granulomatous gout.

Case Report:

A 33 years old female an agricultural laborer came to the outpatient department of a tertiary care center (Medical college & Hospital) with a swelling over the volar surface of her right distal forearm. The swelling was gradually increased in size over 9 to 10 months. She noticed difficulty to move fingers of right hand in the form of restriction in the complete extension of the inter phalangeal joints and fingers since 3-4 months, later patient started complaining of the tingling numbness along the index finger, middle finger. She had reduced appetite and loss of weight. There was no past history of diabetes, tuberculosis, local trauma. We did not find any significant finding in general as well as systemic examination other than the swelling. Local examination: single soft swelling of size 05cm x 07cm over volar surface of right distal forearm. Swelling had defined margins and no scar, sinuses over the skin. The

swelling was adherent to underlying tendons of the fingers leading to contracture of the figure tendons namely flexor digitorum superficialis and flexor digitorum profundus. Chest radiograph & blood investigation was normal. A radiograph of wrist joint shows soft tissue swelling, MRI study was not done due to financial constraints of the patient. We decide to explore surgically in view of worsening of symptoms in terms of the tingling, numbness along the index finger, middle finger, which was suggestive of the compression over median nerve and limitations in movements of the fingers. Operative procedure: Surgery was done in the brachial block with an arm pneumatic tourniquet. Longitudinal incision was taken with zigzag design over the area of the wrist crease. Incision deepened, below the deep fascia and the lesion was traced [Fig. 1].

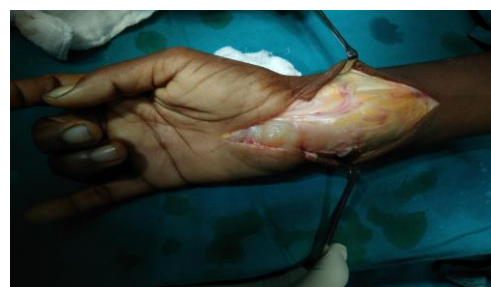

Fig. 1: Deep fascia and lesion dissected

Lesion was found to be involving the tenosynovium with encasing of the flexor digitorum superficialis of all fingers in the flexor tendon zone five, palmaris longus tendon. The median nerve was severely compressed in carpal tunnel with splaying of its fascicles caused by the lesion. By opening the carpal tunnel, median nerve was dissected and preserved. All tendons were dissected off synovium, during dissection

of the tendons many free yellow colored rice bodies found coming out from synovial sac [Fig. 2].

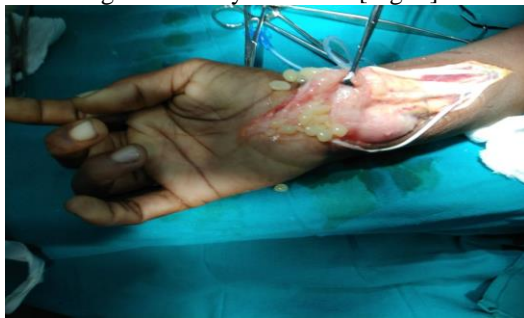

Fig. 2: Synovial sac dissected, free rice bodies (yellow colored)

Excised specimen was sent for the histopathological and microbiological examinations, all flexor tendons were freed well and tension adjustment done so as to achieve the fingers cascade position [Fig. 3].

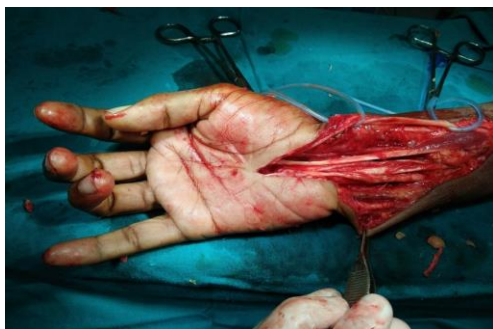

Fig. 3: All flexor tendons and median nerve freed

The wound was closed over the suction drain. Skin closure was done by nylon 3-0 sutures and dorsal extension blocking slab given. Histopathology showed caseous necrosis with granuloma and giant cell suggestive of tuberculosis [Fig. 4]. Mycobacterium tuberculosis bacilli were isolated in culture. Category-I regimen of Anti-TB therapy was initiated to patient. A consent was obtained from the patient to publish the case data and the images.

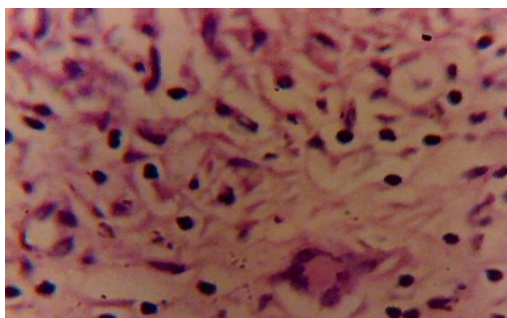


Fig. 4: Histopathological image showing granuloma formation & Giant cell in high power field

Discussion:

Swedish physician Acrel first described Tuberculous tenosynovitis in year 1777 [4]. There are two theories describing pathogenesis of tubercular tenosynovitis namely i) direct inoculation theory ii) hematogenous dissemination from primary focus. Infection starts in the synovium and then slowly spreads to the tendons and bones. Presence of rice bodies in joints infected by tuberculosis was first described in 1895 by Reise [5]. Tubercular tenosynovitis accounts for 5% of cases of osteoarticular tuberculosis which usually found on the volar aspect of hand and wrist [6]. The sheath of tendons is a site for various pathological changes such as i) rice body formation ii) increased vascularization iii) thickening of the synovial membrane. These changes progress to reactive inflammation around the tendon and swelling of the tendon [7]. This tendon is gradually replaced by vascular granulation tissue and rice body formation due to caseation. Only a few strands of tissue remain in tendon and such tendon may rupture spontaneously. Rice bodies can also found in infectious arthritis, seronegative arthritis, nonspecific arthritis and systemic lupus erythematosus [8]. Treatment of TB tenosynovitis involves i) medical management ii) Surgical management. Surgical management indicated when medical management does not show significant result or if one of the following complication occurs such as impending bone collapse, nerve compression, large or multiple abscesses. Similarly surgical intervention is warranted to remove ovoid bodies, drainage of large abscess and correction of deformity [9].

Conclusions:

Cases of tenosynovitis due to tuberculosis are uncommon and diagnosis is often missed causing delay of treatment to patients. Surgeons must consider it in the differential diagnosis when a patient comes with such a presentation. Surgical intervention decided by symptoms and signs. Antitubercular therapy and excision of lesion produce good outcomes.

Conflicts of interests: None declared

Acknowledgements: None

References:

1. Sharma SK. Extra-pulmonary tuberculosis. *Ind J Med Res* 2004;120(4):316-53.
2. Mateo L. Osteoarticular Tuberculosis: Study of 53 cases. *Med Clin* 2007;129:506-9.
3. Pei-Hung S. Tuberculous tenosynovitis of the flexor tendons of the wrist and hand. *J Med Sci* 2002;22:227-30.
4. Aboudola S, Sienko A. Tuberculous tenosynovitis. *Human Pathol* 2004;35(8):1044-046.
5. Reise H. Die Reiskorpschen in tuberculserkrankensynovialsacken. *Deutsche Zeitschrift f'ur Chirurgie*. 1895;42(1):2.
6. Fnini S, Ouarab M. An uncommon occupational accident: Tuberculous tenosynovitis of the extensor tendons of the hand. *Chir Main* 1999;18(4):309-12.

7. Hoffman KL. Tuberculous tenosynovitis of the flexor tendons of the wrist: MR imaging with pathologic correlation. *Skeletal Radiol* 1996;25(2):186–88.
8. Ergun T. Multiple rice body formation accompanying the chronic nonspecific tenosynovitis of flexor tendons of the wrist. *Radiat Med* 2008;26(9):545-48.
9. Renato FMR. Synovial tuberculosis of the hand: an ancient disease in an unusual localization. *Ind J Plastic Surg* 2017;50(2):130–37.

How to cite this article: Jadhav A., Devraj M. V., Sonawane B. B. Tenosynovitis of flexor tendons of hand: Tubercular etiology. *IP Indian J Immunol Respiratory Med* 2018;3(3):153-155.