

## Jugular vein ectasia presenting with hoarseness of voice- A rare association

VishnuKanth<sup>1\*</sup>, R. Manju<sup>2</sup>, Jineesh Joseph<sup>3</sup>, Balla Nagamali Kumar<sup>4</sup>, Abhisekh Chauhan<sup>5</sup>

<sup>1</sup>Assitant Professor, <sup>2</sup>Associate Professor, <sup>3,4</sup>Senior Resident, <sup>5</sup>Junior Resident, Dept. of Pulmonary Medicine, JIPMER, Puducherry, Tamil Nadu

**\*Corresponding Author:**

Email: Vishnu1429@yahoo.com

### Abstract:

Jugular vein ectasia is a congenital dilatation of the jugular vein presenting as a swelling in the neck. Although a benign condition, it can sometimes be associated with hoarseness of voice, horner's syndrome and hemorrhage. The condition can be diagnosed by imaging studies in particular during a Valsalva maneuver. There is no specific treatment for this condition. Surgical option may be required for cosmetic reasons. Though a less common condition it should be one of the differentials of a neck swelling. We report a case of internal jugular vein ectasia presenting with hoarseness of voice.

**Keywords:** Hoarseness of voice; Hemorrhage; Venous ectasia.

### Introduction:

Jugular vein ectasia or phlebectasia is a congenital fusiform or saccular dilatation of the jugular vein that presents as a soft and compressible neck swelling [1]. The swelling increases in size and becomes more prominent on straining and on doing a valsalva maneuver [1]. Although, essentially a benign condition, it is uncommon in presentation. We report, a case of ectasia of right internal jugular vein and briefly discuss its important features.

### Case Report:

A sixty years old lady was referred to the pulmonary medicine department with complaints of hoarseness of voice to rule out lung cancer. She self-reported symptoms of cough and nasal obstruction once or twice a year which subsides with traditional remedies. She had no chest pain, chest tightness, hemoptysis or breathlessness. Hoarseness of voice was present for four months. She had no difficulty in swallowing or phonation. There was no prior history of tuberculosis. She denied smoking history including second hand smoke /passive smoking. On examination, patient was stable. She maintained normal saturation at room air, had no cervical adenopathy and respiratory system examination was normal. On deep inspiration during respiratory system examination a small swelling appeared on the right side of neck along the sternocleidomastoid muscle. The swelling increased in size on coughing. The swelling extended from below the right sternocleidomastoid muscle up to the right anterior triangle of the neck. The swelling was soft, cystic, non-tender and partially compressible. Transillumination was negative implying no fluid content. There was also no venous hum or bruit was. The overlying skin was not involved. A possibility of laryngocele was considered, but laryngoscopy was normal. Chest X-ray and X-ray of soft tissue neck were also normal. A computed tomography scan with angiogram showed normal pulmonary parenchyma and

pulmonary vasculature. Angiogram of neck vessels however showed a duplication of right internal jugular vein with dilatation and ectasia of the posterior part (Figure. 1). The right external jugular vein could not be traced. A 3-dimensional reconstruction of neck vessels (Figure. 2) confirmed ectasia of right internal jugular vein and also an abnormal venous channel in the right paravertebral region. The patient was explained about her condition and reassured that it is a benign condition. Patient is currently undergoing speech therapy and is doing well till last follow-up. A written informed consent was obtained from the patient for the publication of case details.

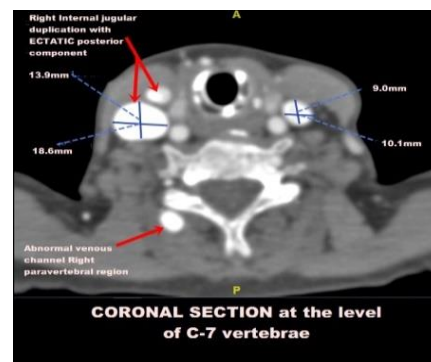


Fig. 1

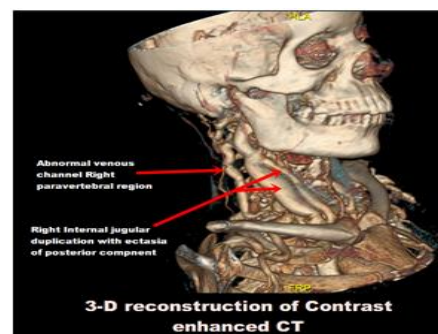


Fig. 2

## Discussion:

Jugular vein ectasia (JVE) is an abnormal dilatation of the jugular vein [1]. The abnormally dilated vein is usually not tortuous. This condition is also sometimes referred to as congenital venous cyst, venous aneurysm, venous ectasia or essential venous dilatation. Venous varix is a closely resembling condition where there is abnormal dilatation and tortuosity of the veins [1]. This condition was first described by Harris in 1928 and subsequently characterized by Gerwig in 1952 [2]. Though ectasia of any neck vein can occur, internal jugular vein is most commonly involved followed by external jugular, anterior jugular and superficial communicus [1]. Due to rarity of this condition, the exact etiology is unknown. A number of hypothesis however have been proposed. These include anomalous reduplication of the internal jugular vein, increased scalenus anticus muscle tone, compression of the vein between the head of the clavicle and the cupula of the right lung. Superior mediastinal irradiation, trauma to the neck and a possible congenital origin [3]. An association of jugular vein ectasia with Menkes disease has also been suggested [4].

The condition is most common in young boys. JVE commonly presents as a localized non tender and compressible swelling in the lower part of neck along the anterior border of sternocleidomastoid muscle. The swelling increases in size or appears to be more prominent during conditions that increase the intra thoracic pressure like straining, sneezing, bending or coughing and disappears after rest. JVE can also be accentuated following a Valsalva maneuver and exertion. The borders are usually well defined and overlying skin is not involved. Venous hum or bruit may be rarely heard over the swelling. Hoarseness of voice and dyspnea are uncommon associations [5]. Our patient presented with hoarseness of voice.

JVE is more common on the right side [6]. It is presumed that due to lack of valves in the right brachiocephalic vein, higher placement of valves in the right internal jugular vein and a larger right inferior jugular bulb, rise in the intrathoracic pressure is directly transmitted to the right jugular bulb resulting in dilatation of the right jugular vein. It has also been hypothesized that ectasia is more common on the right side because the right innominate vein lies in contact with the right apical pleura. As a result, increase in intrathoracic pressure could be directly transmitted to the right internal jugular vein [7].

The condition is usually benign. Rare complications like thrombosis, congestive heart failure, horners syndrome and massive hemorrhage secondary to trauma have been reported [8,9]. JVE has to be differentiated from other neck swellings that enlarge on straining. These includes laryngocele, inflation of apical bullae and superior mediastinal mass [10]. Laryngoscopy and computed tomography(CT) of the chest are needed to exclude laryngocele and mediastinal

mass. Confirmation of diagnosis of JVE is by imaging studies. Ultrasonography of the neck vessels during a Valsalva maneuver can clinch the diagnosis. During a Valsalva maneuver, the diameter of the affected vein may increase up to 2.2 times compared with its measurements at rest. Duplex ultrasound of the neck show flat waves indicating a venous swelling [2,6]. CT scan and angiography may sometimes be required as in our patient.

There is no specific treatment for JVE. Many authors believe that being a benign condition with very rare complications, no active intervention is needed. Patients may be advised to refrain from indulging in activities that increase the intra thoracic pressure. Surgical management may be needed for cosmetic reasons. Surgery may also be advisable in children due to chances of rupture of the dilated vein as they have poor self-control. There is also a chance of thrombus formation in the dilated vein that might require a surgical intervention [1,4,6]. Surgical treatments include ligation of the dilated vein, longitudinal constriction suture venoplasty and partial resection of the phlebectasia. Few instances of exploration and wrapping the dilated segment with polytetrafluoroethylene tube graft have been successfully performed [1].

## Conclusions:

JVE is a benign condition and should always be considered in the differentials of a neck swelling that increases on straining. A simple ultrasound may potentially clinch the diagnosis thereby avoiding unnecessary investigations and risky surgical procedures.

**Conflicts of interest:** None declared

**Acknowledgements:** None

## References:

1. Bindal SK, Vasisth GOP, Chibber P. Phlebectasia of internal jugular vein. *J Surg Tech Case Rep.* 2012;4(2):103-05.
2. Gerwig WH Jr. Internal jugular phlebectasia. *Ann Surg.* 1952;135:130-33.
3. Paleri V, Gopalakrishnen S. Jugular phlebectasia: theory of pathogenesis and review of literature. *Int J Pediatr Otorhinolaryngol.* 2001;57:155-59.
4. Swami H, Nambiar S. Focal ectasia of internal jugular vein. *MJAFI.* 2009;65:282-83.
5. Chakraborty S, Dey PK, Roy A, Bagchi NR, Sarkar D, Pal S. Internal jugular vein phlebectasia presenting with hoarseness of voice. *Case Reports in Vascular Medicine.* 2013, Article ID 386961.
6. Hsun-Chin C, Kin-Sun W, Syh-Jae L, Man-Shan K, Tzou-Yien L. Ultrasonographic Diagnosis and Color Flow Doppler Sonography of Internal Jugular Venous Ectasia in Children. *J Ultrasound Med.* 1999;18:411-16
7. LaMonte SJ, Walker EA, Moran WB. Internal jugular phlebectasia: a clinic roentgenographic diagnosis. *Arch. Otolaryngol.* 1976;102:706-08.

8. Indudharan R, Quah BS, Shuaib IL. Internal jugular phlebectasia: unusual cause of neck swelling. *Ann Trop Pediatr.* 1999;19:105-08.
9. Inci S, Bertan V, Kansu T, Cila A. Horner's syndrome due to jugular venous ectasia. *Child's Nervous System.* 1995;11(9):533-35.
10. Mehmet M, Harun G, Mustafa A, Bahar M. Jugular phlebectasia in children. *Journal of Turgut Ozal Medical Center.* 1997;4(1):107-08.