

Hyper-lucent one lung syndrome - MacLeod syndrome: A rare case associated with COPD

Vinay Mohan^{1,*}, Bharat Bhushan², Sunita Devi³, Ritu Puneet Kaur⁴, Arjun Bhatnager⁵

¹Senior Resident, ²Professor, ^{4,5}Junior Resident, Dept. of Tuberculosis & Chest Diseases, ³Senior Resident, Dept. of Pathology, Govt. Medical College, Patiala, Punjab

***Corresponding Author:**

Email: vnybhagat@yahoo.co.in

Abstract

Hyper-lucent one sided lung syndrome or Swyer James Macleod syndrome is uncommon entity. Sometimes it might be associated after bronchiolitis obliterans infections occurring during earlier part of life. Resultant Pulmonary hypo perfusion because of incomplete or absent development of the pulmonary arteries resulting in a reduced amount of blood flow in lungs is a characteristic feature of it. Typically, this disorder is diagnosed incidentally in recurrent childhood respiratory infections evaluations or occasionally it may follow a silent course only to be diagnosed at adulthood. Here, we report a case in a 70-year-old male person with Swyer James Macleod syndrome incidentally diagnosed while workup for a COPD differentials who presented with dyspnoea on exertion, cough with expectoration. Hence this case highlights the importance of computerized tomography in the diagnostic workup of a case of hyper-lucent lung. All smokers presented with breathlessness and hyperlucent lungs may not always be an emphysematous COPD cases. It could be a case of COPD with SJMS though extremely rare. Hence should be thoroughly investigated.

Keywords: Bronchiolitis obliterans; Pulmonary artery abnormalities, Swyer-James/MacLeod syndrome; Unilateral hyper-lucent lung

Introduction

Swyer James Macleod Syndrome or hyper lucent one sided lung syndrome with failure to develop and /or hypoplasia of the lung blood vessel supply resulting in respiratory organ parenchyma hypo-perfusion presenting as characteristic radiological pattern like unilateral hyperlucency or semi transparency of respiratory organ [1]. It is a rare entity related to bronchiolitis obliterans occurring infection during childhood [2]. Diagnosis is often made during childhood while evaluating for repeated respiratory infections. However occasionally patients without symptoms or having minimum or no bronchiectasis after effects or with minimal symptom diagnosis could also be made late until adulthood [3]. One of study comprising 17450 x-ray chest evaluations Macleod Swyer James Syndrome was found to be 0.001% [4].

Inflammation and fibrosis is a end result due to Bronchiolitis Obliterans involving the walls and surrounding tissues of the membranous and respiratory bronchioles leading to narrowed lumens [5]. Fibrosis of the inter-alveolar septae causes obliteration of the respiratory organ capillary bed and secondarily diminishes blood flow to the key artery segments, leading to the hypo-plastic blood vessel development as discovered in SJMS. Additionally, the reduction in ventilation causes a compensatory decrease in perfusion. Hyper-expansion of the terminal air sacs secondary to bronchiolar obstruction of the peripheral airways offers extra mechanical resistance to flow through the alveolar capillaries and contributes to atrophy of the vascular beds [6].

Hypoplasia of the pulmonary arteries may be a reflection of this decrease in blood flow. Due to the reduced parenchymal perfusion, this syndrome is usually mentioned as semitransparent or hyper-lucent unilateral respiratory organ [7].

Herein, we presented a 70 years old male patient with unilateral hyper lucent lung syndrome (SJMS) found during routine workup for a progressive breathlessness along with cough and expectoration.

Case Report

An old man of seventy years was admitted to this department with a four year history of dyspnoea on exertion which was progressive and cough and expectoration.

Patient was an illiterate labourer who was chronic alcoholic and a chronic smoker since last fifty years. He had recurrent episodes of dyspnoea and cough with expectoration. No notable or recorded childhood or adulthood ailment history. There was no other relevant medical specialty or family related antecedents presented by patients. On physical examination patient was very cooperative maintaining calmness in spite of his distress. He had a raised blood pressure of 200/100 mm hg; regular pulse rate of 88 beats per minute, respiration rate of 20 breaths per minute with recorded an oxygen saturation of 76 % while breathing at room air. On auscultation he had a bilateral ronchi. On chest examination no gross abnormality was seen. Percussion note was bilaterally resonant. The rest of his physical examination was normal.

He had a haemoglobin value of 10.4 mg% with white blood cell counts of 11600 per mm³ and platelet

count of 225,000 per mm³. His oxygen saturation while breathing at room air at the time of admission was 76%. His electrocardiogram showed p-pulmonale with sinus rhythm otherwise found to be well within expected limits. Blood serum electrolytes levels, Serum Creatinine and blood urea were normal. Hepatic transaminases, bilirubin levels, blood serum alkaline phosphatase, total serum proteins and albumins were also founded to be normal. A chest X-ray on admission (Fig. 1) showed comparatively more hyper-lucent lung on the right side chest. Subsequently a repeat check chest X-ray was done showing an alveolar-interstitial congestion finding on the left side with comparatively hyper-lucent lung on the right side chest (Fig. 2).

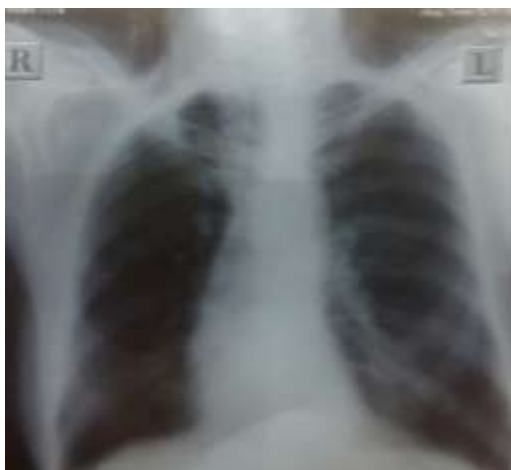

Fig. 1: X-ray chest showed right sided hyper-lucent lung

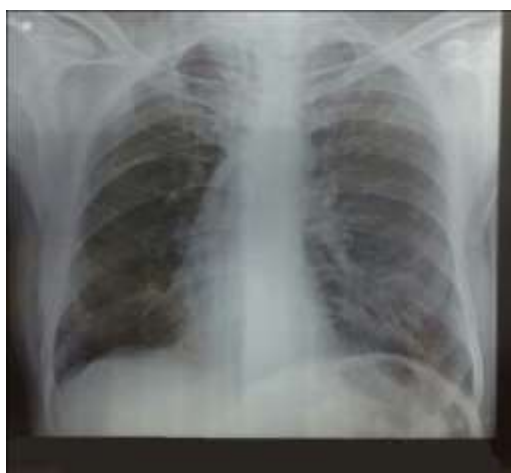

Fig. 2: X-ray Chest (repeated) showed a congested alveolar-interstitial pattern on the left side with comparatively hyper-lucent right side lung

The patient was advised admission to our unit for further management and diagnostic evaluation. Patient was initially given diuretic management (Inj. Lasix in dose of 20 mg thrice a day), antihypertensive treatment. He was given symptomatic management and also high flow supplemental oxygen with a mask. A pulmonary

function test (PFT) was done which reported as an obstructive-restrictive pattern. A subsequent repeat good quality digital x-ray chest was done to reassess the hyper-lucent lung to rule out probable emphysematous chest, encysted pneumothorax or large bullous lesion. There was ipsilateral shift of the mediastinum to the right side hyperlucent chest (Figure 3).

Keeping in vascular causes / Macleod leod syndrome as one of the various differentials patient was advised and planned for the computerized tomography chest (CT) and pulmonary angiography (Angio-CT). CECT confirmed the findings as area of hyperlucency affecting major part of right lower lobe (Figure 4a, 4b) that on pulmonary angiography (Figure 5a & 5b) showed paucity of branches of right pulmonary artery involving the affected part of lung along with presence of centrilobular variety of emphysematous changes more on right lung than left lung, compatible with SJMS.

Ventilation perfusion scan was advised for further work up. He was also recommended to get influenza and pneumococcal vaccinations along with on-going treatment. Owing to his financial condition and reluctant to accept any such vascular or perfusion defect patient refused both advices. The patient having mitigated of most of his symptoms declined further stay in the hospital and he was prescribed conservative management for breathlessness.

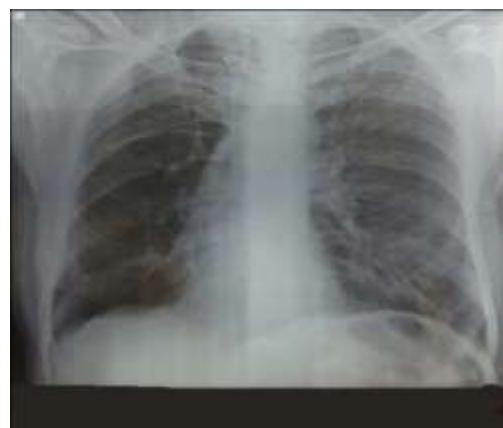


Fig. 3: X-ray Chest (follow up) showed that there was ipsilateral shift of the mediastinum to the right side hyperlucent chest

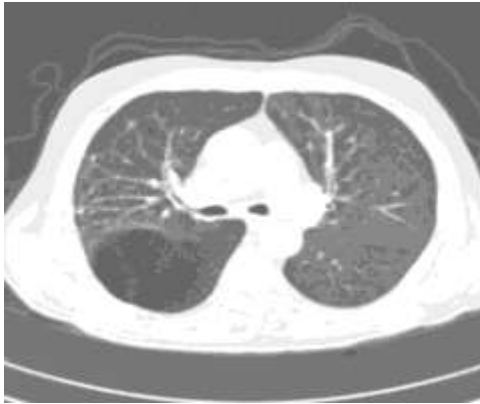

Fig. 4a: CECT Chest- Lung window (Axial view) showing hyperlucent right lung lower lobe with diminished vascularity

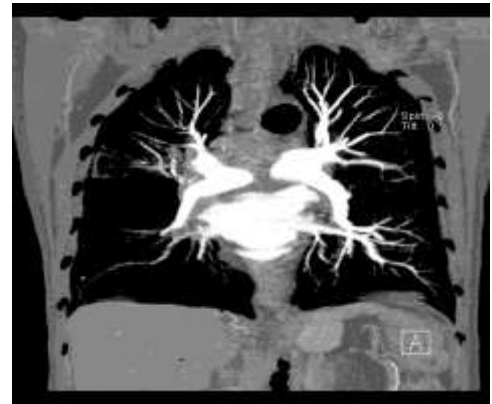

Fig. 5b: Pulmonary angiography (Coronal view) showing hypoplasia of right pulmonary artery and its branches

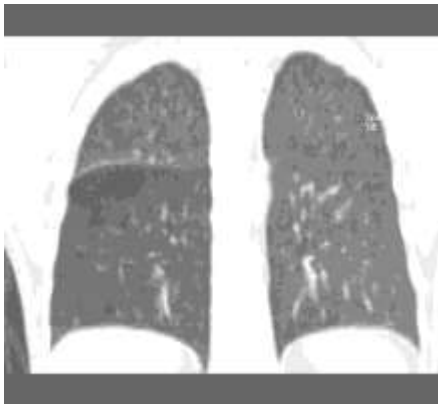


Fig. 4b: CECT Chest- Lung window (Coronal view) showing hyperlucent right lung lower lobe with diminished vascularity

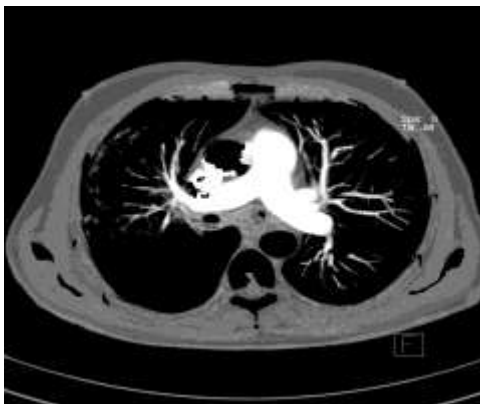

Fig. 5a: Pulmonary angiography (Axial view) showing hypoplasia of right pulmonary artery and its branches

Discussion

In our this case, keeping in view of adulthood, smoking habits and late onset of symptoms chronic obstructive lung disease was thought of. The patient can be completely asymptomatic with hyper-lucent lung field as an incidental finding on the x-ray chest conducted for other indications. Recurrent respiratory infections, productive cough, shortness of breath and progressive dyspnoea on exertion as in our case may be the alternate presentations [8]. The primary impression from the radiological pattern was according to right sided emphysematous changes. Finally, a radiological on computerized tomography chest (CT) and Pulmonary angiography (Angio-CT) confirmed the findings as area of hyperlucency affecting major part of right lower lobe which on further pulmonary angiography showed only small or insufficient branches of pulmonary artery within the affected segment suggestive of Swyer James Syndrome along with presence of centrilobular variety of emphysematous changes more on right lung than left lung.

Table 1: Causes of unilateral hypertranslucency of the lung [9]

<p><u>Normal</u></p> <ul style="list-style-type: none"> Increased density of contralateral lung, e.g. pleural effusion/thickening, consolidation 	<p><u>Soft tissue</u></p> <ul style="list-style-type: none"> Mastectomy Congenital absence of pectoralis muscle Poliomyelitis 	<p><u>Emphysema</u></p> <ul style="list-style-type: none"> Compensatory: lobar collapse, lobectomy Obstructive: foreign body, tumour, Macleod's syndrome, congenital lobar emphysema Bullous
<p><u>Technical</u></p> <ul style="list-style-type: none"> Rotation, scoliosis 	<p><u>Vascular</u></p> <ul style="list-style-type: none"> Absent/hypoplastic pulmonary artery Obstructed pulmonary artery, e.g. by tumour, embolus Macleod's syndrome 	<p><u>Pneumothorax</u></p>

Considerably, a comparatively uncommon and complicated SJMS disease is characterised by unilateral hyperlucency of a partial section of or the whole lung. This Syndrome was first ever described way back in 1953 by Swyer and James and further it was elaborately detailed by Macleod in 1954 [3,10]. This disorder may present with various clinical features and the reported prevalence of this disease is 0.01% in 17,450 survey chest radiograph [11]. Present thought is that disease is of an acquired nature secondary to viral bronchiolitis and pneumonitis occurring during childhood with various etiological association [2] like with mycobacterium tuberculosis, influenza A, paramyxovirus morbillivirus, mycoplasma pneumoniae, Bordetella pertussis and adenovirus types 3, 7 and 21. Our patient had repeated episodes respiratory infections or pneumonic spells during his childhood. Such patients may sometimes present clinically with cough of productive nature, breathlessness on exertion, at times may be with haemoptysis. Those patients with very little or absent sequelae of bronchiectasis, or who are with few symptoms or even who remain symptomless usually left without diagnosis till late life [12] to be diagnosed incidentally as in our case too. In our case we clicked the final diagnosis of SJMS while old chronic smoker was being routinely worked up as a case of COPD. Obstructive – Restrictive pattern as seen in PFT in our case too could better justify and explained the aspects related to dual disease of SJMS and COPD. Air trapping in lung during expiration in COPD along with one-sided hyperlucent lung or pulmonary lobar hyperlucency on Radiological based diagnosis of Macleod's syndrome ultimately resembled as a mosaic pattern [13]. There might be a variable degree of lung parenchyma destruction with or without associated bronchiectasis. Additionally the affected pulmonary artery as seen on pulmonary angio-CT typically has pathological reduced calibre thus consequently leading to a reduced blood flow to the respiratory organ. Finally, another characteristic feature seen is the change in perfusion due to pathological involvement within the morbid respiratory organ sections thus leading to

atelectatic compression area of healthy lung due unconventional hyperinflation of affected lung [14]. This is thus a valid reason to better diagnose this syndrome in such cases with HRCT on inspiration and expiration further reconfirmed with an angio-CT. A ventilation-perfusion respiratory organ scanning [15] might even be performed however false-positives might seem in the presence of any disorder involving distal airway obstruction (such as, bronchiolitis obliterans, bronchial asthma or congenital lobar emphysema). Timely protection with influenza and pneumococcal vaccinations along with the early management of respiratory organ infections is desirable for SJMS treatment [1,12]. Resection of the affected lung was fortunate [1]. There is absence of any specific morbidity-mortality study with SJMS in literature.

Conclusions

Summarising, the present case emphasizes that a chest X-ray might underestimate the prevalence of the SJMS syndrome. There is likelihood of missing the diagnosis among smokers who might have emphysema or bullous lesion on the chest x-ray [16]. Only a strong suspicion and prompt complementary imaging can facilitate diagnose SJMS. This case is reported as only very few cases have been reported worldwide of adults presenting with SJMS.

Conflicts of interest: None declared

Acknowledgements: None

References

1. Fregonese L, Girosi D, Battistini E, Fregonese B, Risso FM, Bava GL et al. Clinical, physiologic, and roentgenographic changes after pneumonectomy in a boy with Macleod/Swyer-James syndrome and bronchiectasis. *Pediatric Pulmonology*. 2002;1;34(5):412-16.
2. Tortajada M, Gracia M, García E, Hernández R. Diagnostic considerations in unilateral hyperlucency of the lung (Swyer-James-Macleod Syndrome). *Allergologia et immunopathologia*. 2003;32(5):265-70.

3. Sulaiman A, Cavaille A, Vaunois B, Tiffet O. Swyer-James-MacLeod syndrome; repeated chest drainages in a patient misdiagnosed with pneumothorax. *Interactive cardiovascular and thoracic surgery*. 2009 ;8(4):482-84.
4. Piquette CA, Rennard SI, and Snider GL, "Chronic bronchitis and emphysema," in *Textbook of Respiratory Medicine*, pp. 1187-1245, WB Saunders Company, Philadelphia, Pa, USA, 2000.
5. Schlesinger C, Meyer CA, Veeraraghavan S, Koss MN. Constrictive (obliterative) bronchiolitis: diagnosis, etiology, and a critical review of the literature. *Annals of diagnostic pathology*. 1998;2(5):321-34.
6. Mathur S, Gupta SK, Sarda M, Jaipal U. Swyer-James-Macleod syndrome with emphysematous bulla. *Journal of the Indian Medical Association*. 1995;93(4):150-54.
7. Salmanzadeh A, Pomeranz SJ, Ramsingh PS. Ventilation-perfusion scintigraphic correlation with multimodality imaging in a proven case of Swyer-James (Macleod's) syndrome. *Clin Nucl Med*. 1997;22:115-118.
8. Lucaya J, Gartner S, García-Peña P, Cobos N, Roca I, Liñan S. Spectrum of manifestations of Swyer-James-MacLeod syndrome. *Journal of computer assisted tomography*. 1998;22(4):592-97.
9. Janet M, Philip JA Robinson, Richard W. Whitehouse, Andrew R Wright, Jeremy PR Jenkins. The normal chest: methods of Investigation and differential Diagnosis. In: David Sutton, editor. *Text Book of Radiology and Imaging*. 7th ed. Edinburgh: Churchill Livingstone;2003.p.38.
10. Macleod WM. Abnormal transradiancy of one lung. *Thorax* 1954;9:147-153.
11. Yiu MWC, Tsang KWT, Wong Y, Ooi GC. Focal area of hyperlucency on a chest radiograph. *Respiration* 2001;68:545-47.
12. Capela C, Gouveia P, Sousa M, Regadas MJ. Adult diagnosis of Swyer-James-MacLeod syndrome: a case report. *J Med Case Rep*. 2011;5(1):2.
13. Gomez Belda AB, Martínez-Moragón E, Fernández Fabrellas E: Swyer-James syndrome: diagnostic contributions of helical computerized tomography. *Arch Bronconeumol*. 2000;36:421-22.
14. Walles T, Kyriss T, Maier AS, Friedel G: eComment: Swyer-James-MacLeod syndrome: addendum to the clinical appearance. *Interact Cardiovasc Thorac Surg*. 2009;8:484.
15. Salmanzadeh A, Pomeranz SJ, Ramsingh PS: Ventilation-perfusion scintigraphic correlation with multimodality imaging in a proven case of Swyer-James syndrome. *Clin Nucl Med*. 1997;22:115-18.
16. Yekeler E. A rare case of swyer-james macleod syndrome and a new clinical presentation, acquired lobar emphysema. *Ann Thorac Surg*. 2012;93(5):e123-5.