

## Clinical outcomes of surgical flail chest stabilization using the mini plating system

Devender Singh<sup>1</sup>, Shegu Gilbert<sup>2,\*</sup>, Arumugam Subramanian Thennavan<sup>3</sup>, Rajasukumaran Kandasamy<sup>4</sup>

<sup>1</sup>Consultant, <sup>2</sup>Associate Consultant, Dept. of Cardiothoracic Surgery, <sup>3</sup>Consultant, Dept. of Orthopaedics, <sup>4</sup>Consultant, Dept. of Oral & Maxillofacial Surgery, Kovai Medical Center & Hospital Limited, Coimbatore

**\*Corresponding Author:**

Email: shegugilbert@yahoo.co.in

### Abstract

**Objective:** To study the clinical outcomes of patients undergoing surgical fixation of flail chest due to blunt chest trauma.

**Methods:** It was a retrospective study. Six patients with flail chest requiring extended ventilator support underwent surgical fixation using the mini plating system. Their post-operative outcomes like duration of ventilation, duration of ICU and hospital stay, post-operative pain score and physical well-being in follow up were evaluated.

**Results:** The stiffness of these plates matches that of the ribs. Low stiffness and ductility of these plates effectively prevents screw loosening and pull-out and provides stable and durable fixation of flail chest. All the six patients in the study were successfully weaned off the ventilator and were able to maintain adequate room air saturations, reduced pain score and had good one year follow-up.

**Conclusions:** Compared to conservative management surgical stabilization of flail chest is associated with reduced length of hospital and ICU stay, reduced exposure to mechanical ventilation and its complications. Mini plating system is an effective implant system for flail chest stabilization.

**Keywords:** Flail Chest; Fracture Fixation; Internal; Rib Fractures

### Introduction

Flail chest is present in up to 6% of patients who have sustained blunt chest trauma [1]. These injuries are potentially fatal, with in-hospital mortality rates of up to 33% for patients with a flail chest [2]. Several reports indicate that patients who underwent surgical fixation of flail chest required a shorter duration of mechanical ventilation, were less likely to develop chest infections and less need for tracheostomy than patients managed without surgery [3]. Fixation is performed using pelvic, mandibular, customized reconstruction plates and anatomic rib plates [4]. An ideal rib implant should have low stiffness compared to that of the ribs [5]. Implants with high stiffness leads to increased stress between the screw bone interface resulting in screw loosening and pull out. We used the 2.0 MP Mini plates (16 hole, straight, regular, ref 55-08216) and 2.0mm MP self-drilling screws [Stryker Leibinger GmbH & co. KG, Germany] and performed fixation in six patients with flail chest.

### Methodology

It was a retrospective study. The study was conducted at the Kovai Medical Center and Hospital Limited, which is a tertiary care hospital located at Coimbatore, India. We retrospectively reviewed the data of six patients with flail chest, who underwent surgical stabilization of the flail chest. Computed tomography of the chest was done in all patients and volume reconstruction of the bony cage was done. Their post-operative outcomes like duration of ventilation, duration of ICU and hospital stay, post-operative pain score and physical well-being in follow-up were evaluated. Consent was not obtained from the

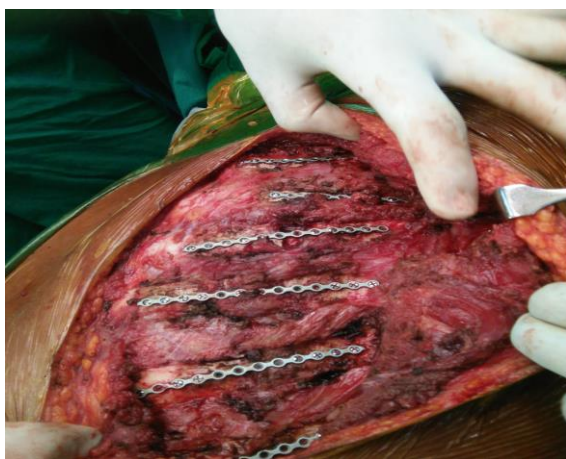patients, as it was a retrospective study.

### Results

**Patient outcome:** The mean age of the six patients who underwent ORIF was  $59 \pm 14.76$  (range 45-75). There were one female and five male patients. Five of them sustained injuries from road traffic accident and one from bull gaur injury. In three patients apart from the flail chest they had clavicle and scapula fracture, one patient had grade 4 splenic injury and subarachnoid hemorrhage with a Glasgow coma scale of 15/15. Five patients were intubated on admission for respiratory compromise and one patient required noninvasive ventilation. These patients underwent surgical fixation of flail chest after an average 5 days (range 3-9) from the day of admission to the hospital. Average number of rib fractures present was 10 (range 9-12) of which 5 ribs (range 4-7) were surgically fixed. Average number of ventilation days, days in intensive care unit and hospital stay were 5 (range 1-14), 9 (range 1-17) and 24 (range 10-40) days respectively. Pain score at the time of discharge was 2/10. One patient developed postoperative loculated pleural fluid collection and required decortication. One patient had hardware loosening due to screw pull out and required reoperation. Clavicle fixation was done along with ORIF for two patients. One patient required emergency laparotomy for hemoperitoneum. Two patients underwent tracheostomy along with rib fixation because of prolonged ventilation.

**Technique of surgery:** Under endotracheal general anesthesia patient is placed in semi lateral or lateral position. Anterolateral, posterolateral thoracotomy type skin incision or tailored skin incision according to the

site of fractures were made. Pectoralis major and latissimus dorsi muscles were divided for approaching the anterior and posterior fractures respectively. Muscle attachments from fractured ribs were cleared using electrocautery. Pleura were not entered. Debris was cleared from fracture site. Intercostal nerve bundle was protected. Fracture ends were mobilized and reduced. Mini plates were applied directly over the periosteum of the bone and were fixed with a minimum of three screws on either side of the fracture (Figure 1). Vacuum drain was placed under the dissected flap and intercostal drain was placed when needed. Layered closure of the thoracotomy was done.



**Figure 1: Operative image of fixation of flail chest using 2 MP mini plate system**

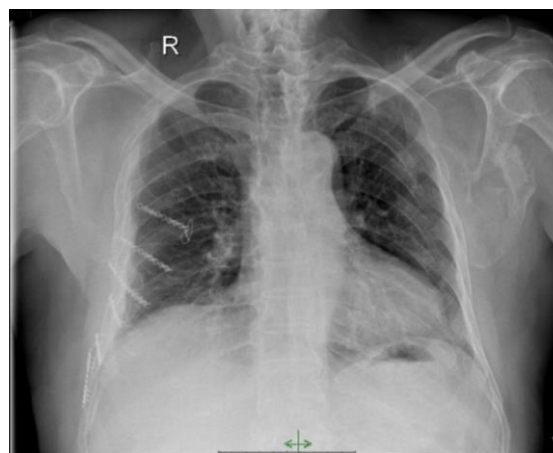
### Discussion

Flail chest is defined as fracture of three or more sequential ribs at multiple sites, results in paradoxical chest wall movement, altered respiratory mechanics, and frequently respiratory failure. Indications for surgical fixation of rib fractures include flail chest, severe chest wall deformity, failure to wean from mechanical ventilation, chronic pain or disability, pulmonary herniation, non-union, and "on the way out" after thoracotomy. Literature reviews suggest that patients undergoing surgical fixation had lesser stay in the intensive care and hospital and lesser duration of ventilation when compared with those being managed without surgery [6,7]. Surgical fixation of rib fractures for flail chest is a level 2 recommendation [8]. The 2.0 MP mini plate system are low profile straight 16 hole plates. They have a low stiffness that matches the flexibility of the ribs. Because of their enhanced ductility (bendability) plate compression over the bone by screw tightening allows the plate to bend and twist according to the contour of the rib. These plates have 16 holes. Length of each plate is 10cm and the width is 0.5cm.

These plates were fixed using a minimum of three screws (2.0 X 6mm MP screws) on either side of the fracture. These screws are self-drilling, self-tapping

screws. We preferred this plating system because of its low profile, ease of fixation technique, ease of contouring and low cost.

Patients with flail chest and extensive lung contusion are a special category because these patients after surgical stabilization may still need extended ventilator support. In all the six patients only the anterior and lateral rib fractures were fixed. Posterior fractures were not fixed. All of them have one year follow up. Chest radiograph in the follow up revealed a stable fixation (Figure 2). Patients are free of chest pain and tightness, breathing difficulty and they were able to do their activities at home.



**Figure 2: Post-fixation chest X-ray**

### Conclusions

Compared to conservative management surgical stabilization of flail chest is associated with reduced length of hospital and ICU stay, reduced exposure to mechanical ventilation and its complications.

**Conflicts of interest:** None declared

### Acknowledgements

We like to thank Mr. Kalayarasan Mani, Department of mechanical engineering, PSG institute of technology, Coimbatore for his support on mechanics of the plate.

### References

1. Lafferty PM, Anavian J, Will RE, Cole PA. Operative treatment of chest wall injuries: indications, technique, and outcomes. *J Bone Joint Surg Am.* 2011;93:97-110.
2. Fowler TT, Taylor BC, Bellino MJ, Althausen PL. Surgical treatment of flail chest and rib fractures. *J Am Acad Orthop Surg.* 2014;22:751-60.
3. Bhatnagar A, Mayberry J, Nirula R. Rib fracture fixation for flail chest: what is the benefit? *J Am Coll Surg.* 2012;215:201-05.
4. Engel C, Krieg JC, Madey SM, Long WB, Bottlang M. Operative chest wall fixation with osteosynthesis plates. *J Trauma.* 2005;58:181-86.
5. Bottlang M, Wallaser S, Noll M, Honold S, Madey SM, Fitzpatrick D. Biomechanical rationale and evaluation of

- an implant system for rib fracture fixation. *Eur J Trauma Emerg Surg.* 2010;36:417–26.
6. Lardinois D, Krueger T, Dusmet M, Ghisleta N, Gugger M, Ris H. Pulmonary function testing after operative stabilisation of the chest wall for flail chest. *Eur J Cardiothorac Surg.* 2001;20:496–501.
  7. Tanaka H, Yukioka T, Yamaguti Y, Shimizu S, Goto H, Matsuda H, et al. Surgical stabilization or internal pneumatic stabilization? A prospective randomized study of management of severe flail chest patients. *J Trauma.* 2002;52:727–32.
  8. Simon B, Ebert J, Bokhari F, Capella J, Emhoff T, Hayward T, et al. Eastern Association for the Surgery of Trauma. Management of pulmonary contusion and flail chest: an Eastern Association for the Surgery of Trauma practice management guideline. *J Trauma Acute Care Surg.* 2012;73(5 Suppl 4):S351-61.