



## Review Article

## Conceptual therapeutics for small cell lung cancer

Sunil Chaudhry<sup>1\*</sup>, Abhijit Trailokya<sup>2</sup><sup>1</sup>Consultant Edenwell Therapeutics Pvt Ltd, Mumbai, Maharashtra, India<sup>2</sup>Indoco Remedies, Mumbai, Maharashtra, India

## ARTICLE INFO

## Article history:

Received 23-08-2024

Accepted 20-09-2024

Available online 17-10-2024

## Keywords:

Small cell lung cancer

TP53 mutations

Therapeutic targets : Chemotherapy

Immunecheckpoint inhibitors

Radiotherapy

Surgery

## ABSTRACT

Small-cell lung cancer (SCLC) is 15% of all lung cancers and is definitely of the most aggressive tumors, with relative poor prognosis and with limited drugs. 90% of patients of SCLC are regular smokers providing the link that tobacco carcinogens are responsible for the initiation. The value of female smokers (79.9) is more than that of male smokers (20.3). The 5 year survival rate has been reported to be less than 7%. The cornerstone of treatment for any stage of SCLC is etoposide-platinum based chemotherapy; in limited stage (LS) along with concomitant radiotherapy to thorax and mediastinum. Novel drugs used in treatment of SCLC are: Atezolizumab, Everolimus, Durvalumab, Iplimumab, Tarlatamab which target PD-L1, a protein related to PD-1 that is found on some tumor cells and immune cells. The combination of thoracic RT with chemotherapy results in improved survival compared to chemotherapy alone. The role of surgery in SCLC has been under question, though performed in earlier stage 1 as per the International Guidelines. Some reports document better OS in early stage III too.

This is an Open Access (OA) journal, and articles are distributed under the terms of the [Creative Commons Attribution-NonCommercial-ShareAlike 4.0 License](https://creativecommons.org/licenses/by-nc-sa/4.0/), which allows others to remix, tweak, and build upon the work non-commercially, as long as appropriate credit is given and the new creations are licensed under the identical terms.

For reprints contact: [reprint@ipinnovative.com](mailto:reprint@ipinnovative.com)

## 1. Introduction

Small cell lung cancer (SCLC) is an aggressive high-grade neuroendocrine malignancy with high metastatic potential with poor clinical outcomes mostly occurring in 60-80 years. The median overall survival (mOS) for patients with metastatic SCLC receiving standard chemotherapy is ranges between 9–11 months.<sup>1</sup> SCLC is commonly seen in heavy smokers (depends on amount of tobacco consumption) as an advanced stage disease, it clinically presents with early metastatic spread and good responsiveness to initial therapy, and in most patients, it is consistently followed by relapse. With a chemo resistant disease. The SCLC has location in hilar or perihilar areas, with less than 5% of the cases at peripheral locations.<sup>2</sup> Concomitant inactivation of two tumour suppressors, p53 and RB (encoded by TP53 and RB1, respectively), is found in

the vast majority of SCLC cases.<sup>3</sup> SCLC has association with paraneoplastic syndromes such as paraneoplastic endocrinopathies include syndrome of inappropriate anti-diuretic hormone and Cushing syndrome. The features include dermatomyositis, and rarely hyperglycaemia, hypoglycaemia. 1–7.4% of patients with cancer can develop a paraneoplastic syndrome.<sup>4</sup> The common cytologic feature is highly cellular aspirates with presence of small blue cells with very scant cytoplasm, loosely arranged or in a syncytial pattern. The nuclear marker Ki-67, which is present in samples is characteristic. Patients with high Ki-67 had a better survival effect than those with low Ki-67, and patients with complete responses had a higher Ki-67 value.<sup>5</sup> The most common symptoms in patients with Extensive stage disease were shortness of breath, fatigue, coughing, chest pain, and nausea/vomiting. Shortness of breath is a fairly constant symptom, although it worsened with exertion and could be exacerbated by coughing.<sup>6</sup>

\* Corresponding author.

E-mail address: [sunil.r.chaudhry@gmail.com](mailto:sunil.r.chaudhry@gmail.com) (S. Chaudhry).

SCLC is easily diagnosed by cytology. There are a number of pitfalls in the diagnosis of SCLC. These include lack of cytology–histology correlation. A chest x-ray is the most standard imaging test to look for any abnormality within the lung. If abnormality is present, a computed tomography (CT) scan is frequently ordered to reveal the size, shape, and position of any lung tumour.<sup>7</sup>

## 2. Therapy for Small Cell Lung Cancer

After the initial treatment, many patients of SCLC develop recurrent disease, often with additional sites of metastasis. The basic initial line of therapy includes platinum–etoposide was found to be associated with the high overall survival and was well tolerated. Very few drugs have been proved effective for second-line treatment of SCLC. Topotecan is a standard second-line choice but is not uniformly used for patients in part due to its modest efficacy and high hematologic toxicity. Overall survival (OS) in patients treated with topotecan is only 26 weeks vs. 14 weeks in patients managed with the best supportive care alone. Single-agent regimens of standard cytotoxic agents, such as paclitaxel, docetaxel, gemcitabine, and vinorelbine, as second line therapies yield modest results.<sup>8</sup>

Extensive-stage small-cell lung cancer (ES-SCLC) have been significantly improved by incorporating immune checkpoint inhibitors (ICIs) into platinum-based chemotherapy. Use of antiangiogenic agents, PARP inhibitors (PARPi), lurbinectedin, and anti-DLL3 agents, offering insights into potential future directions in the management of this aggressive cancer. CASPIAN have shown substantial evidence of benefit from adding atezolizumab and durvalumab respectively to chemotherapy, leading to the approval of these checkpoint inhibitors (CPIs) in the frontline setting of ES-SCLC.<sup>9</sup>

**Table 1:** Line of therapy for SCLC

1. Chemotherapy improves the survival of patients with limited-stage disease (LD) or extensive-stage disease (ED), and it is curative in only a few patients.
2. The combination of platinum and etoposide is the most widely used standard chemotherapeutic regimen. [Level of evidence A1]
3. SCLC is highly radiosensitive and thoracic radiation therapy improves survival of patients with LD and ED tumors. Cranial radiation should also be provided [Level of evidence A1]
4. Clinical trials evaluating new drug regimens or under evaluation
5. For recurrent disease – Chemotherapy & Immunotherapy is evaluated

Platinum compounds are the mainstay of chemotherapeutic regimens in SCLC patients.<sup>10</sup>

Evaluation of recent therapeutics for refractory or recurrent setting or approved second line drugs : Lurbinectedin is a DNA alkylating agent, which covalently

binds to guanine residues in the DNA . It also causes inhibition of RNA-polymerase-II activity.

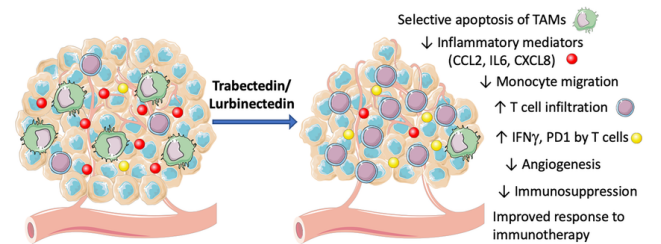
It is used for the treatment of adult patients with metastatic small-cell lung cancer (SCLC) with disease progression on or after platinum-based chemotherapy.

The drug has high volume of distribution, with high penetration to cancerous cells. Its synthetic derivative of trabectedin which is used to treat refractory, metastatic small cell lung cancer. In an evaluating trial, the median OS of 5.1 months in the second-line cohort and 5.6 months in the third-line setting was found .

In elderly patients, lurbinectedin seems to be superior to the standard of care in terms of both efficacy & safety.

Lurbinectedin leads to lymphopenia , fatigue, chest pain, headache & tumor lysis syndrome.

Indicated for metastatic small cell lung cancer (SCLC) in patients with disease progression on or after platinum-based chemotherapy 3.2 mg/m<sup>2</sup> IV q21Days (only if absolute neutrophil count (ANC) ≥1,500 cells/mm<sup>3</sup> and platelet count ≥100,000/mm<sup>3</sup>).<sup>11,12</sup>



**Figure 1:** Site of action of lurbinectedin

### 2.1. Diagram adopted from

Paola Allavena et al, Effects of the Anti-Tumor Agents Trabectedin and Lurbinectedin on Immune Cells of the Tumor Microenvironment, *Frontiers in oncology* ,2022

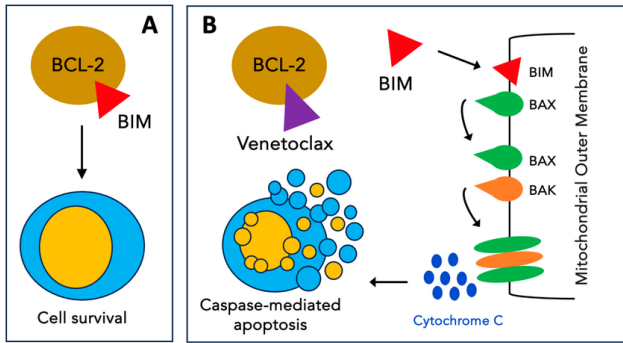
### 2.2. Bcl-2 Inhibition and navitoclax

Navitoclax and Venetoclax bind to apoptosis suppressor proteins Bcl-2, Bcl-XL, and Bcl-w, which are frequently overexpressed in var. Indicated for metastatic small cell lung cancer (SCLC) in patients with disease progression on or after platinum-based chemotherapy

Navitoclax administration (orally bioavailable) includes 150-mg 7-day lead-in dose followed by 250-mg daily dosing with the option to further increase to 325 mg after 14 days. Lymphopenia and thrombocytopenia are frequently observed side effects.<sup>13</sup>

### 2.3. Diagram adopted From

Ramy Rahmé, Venetoclax Combined with Intensive Chemotherapy: A New Hope for Refractory and/or

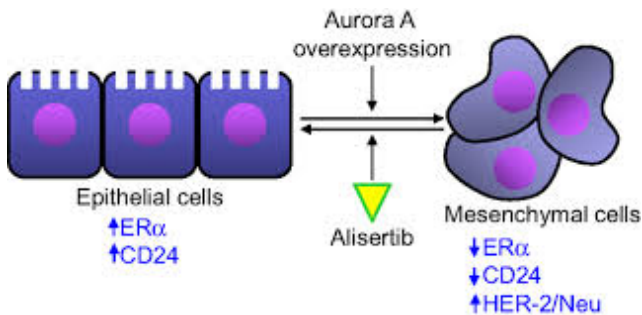


**Figure 2:** Mode of action of Venetoclax

Relapsed Acute Myeloid Leukemia? Journal of clinical medicine January 2024, 13(2):549

#### 2.4. Aurora A kinase (AAK) inhibition

Aurora A kinase is linked to mitosis regulation and is involved in formation of spindle poles. Acts on G2/ M phases of cell.



**Figure 3:** Mode of AAK inhibition

#### 2.5. Diagram adopted from

Huifeng Neu, Scientific rationale supporting the clinical development strategy for the investigational Aurora A kinase inhibitor alisertib in cancer, Front. Oncol., 24 August 2015 Alisertib/paclitaxel used in relapsed or refractory SCLC. Barasertib a prodrug reduces glucose in cancer cells in dose dependent manner. The maximum tolerated dose of Barsasertib is 200 mg, given as a 2-h weekly infusion. Danusertib is another drug<sup>14</sup>

#### 2.6. Poly-ADP ribose (PARP) inhibition

PARP inhibitors represent a novel class of anti-cancer therapy and they work by taking advantage of a defect in DNA repair in cancer cells with BRCA mutations and inducing cell death. Talazoparib has been demonstrated to be the most potent PARP trapper followed by niraparib, then olaparib and rucaparib, with veliparib being the least potent

trapper. SCLC patients have high PARP1 protein expression.

The first Chinese study on ES -SCLC was Trident, where safety and efficacy of Olaparib + Durvalumab was evaluated. In this study ORR was 75% and the median PFS was 5.8 months.<sup>15</sup>

#### 2.7. DLL-3 Targeting ADCs

DLL3 is a target identified in tumor-initiating cells which is expressed in more than 80% of patients with SCLC. Rovalpituzumab tesirine is a DLL3-targeted ADC that consists of a humanized DLL3-specific IgG1 monoclonal antibody (mAb), and a protease-cleavable linker that covalently links the antibody to the toxin. Rovalpituzumab tesirine was 0.4 mg/kg every 3 weeks, and the recommended phase 2 dose and schedule were 0.3 mg/kg every 2 weeks. It shows linear pharmacokinetics, and a half-life of around 10–14 days. Median overall survival was 5.8 months, and 1-year overall survival was 32% in DLL3 high expressors. The most common side effects are grade 3 and higher toxicities were thrombocytopenia in 12%, serosal effusions in 11%, and skin reactions in 8%. Skin reactions of any grade are seen in 49%.<sup>16</sup>

Tarlatamab, a bispecific T-cell engager molecule, which binds to both DLL3 and CD3 leading to T-cell-mediated tumor lysis. Tarlatamab demonstrates a manageable safety profile across a wide dose range of 100 mg.

Tarlatamab, administered as a 10-mg dose every 2 weeks, revealed the objective response rate (ORR) 40%.<sup>17</sup>

#### 2.8. Cyclin dependent kinase 4/6 (CDK 4/6)

Palbociclib, Abemaciclib inhibit transition from G1 to S phase during the cell cycle via inhibition of CDK4 and CDK6, which they target with varying potency. Palbociclib has similar binding affinity to CDK4/cyclin D3 and CDK6/cyclin D1, whereas abemaciclib have greater binding affinity for CDK4/cyclin D3.

Roniciclib from Bayer AG, is an oral, small-molecule pan-cyclin-dependent kinase (CDK) inhibitor Roniciclib used in 5mg twice daily or 7.5 mg twice daily BID on a 3 days on/4 days off schedule in 21-day cycles. Common Roniciclib-related adverse events include nausea (76.6%), fatigue (65.8%), diarrhoea (63.1%), and vomiting (57.7%).<sup>18</sup>

#### 2.9. Angiogenesis inhibitors

The addition of bevacizumab to chemotherapy did improve PFS but did not have an impact on OS.

The regimens had Etoposide and Irinotecan combination, Cisplatin + Irinotecan, Paclitaxel or Topotecan with Bevacizumab 7.5 mg/kg dosage<sup>19</sup>

2.10. Fibroblast growth factor receptor (FGFR)-Polysomy of chromosome 8

Pazopanib is a commercially available multi-kinase inhibitor with activity at FGFR1 at 800mg dose. Pazopanib maintenance yielded better results for patients who were initially on Etoposide and Platinum Chemotherapy.<sup>20</sup>

Metronomic therapy is a therapy in which anti-cancer drugs are administered in a lower dose than the maximum tolerated dose repetitively over a long period to treat solid cancers with fewer side effects. Metronomic chemotherapy regimen of cisplatin, etoposide, and irinotecan were compared to single-agent topotecan in sensitive recurrent SCLC. OS in patients taking the three-drug metronomic regimen was significantly longer than for patients treated with topotecan alone (18.2 vs. 12.5 months).<sup>21</sup>

Anlotinib: is a novel multi-target small molecule tyrosine kinase inhibitor (TKI) which effectively inhibits the vascular endothelial growth factor (VEGF) receptor, the fibroblast growth factor receptor (FGFR), the platelet-derived growth factor receptor (PDGFR)  $\alpha$  and  $\beta$  and c-Kit; hence, it has both anti-angiogenesis and tumor growth inhibition effects. Anlotinib is administered as one cycle of 12 mg daily for 14 days, discontinued for 7 days, and then repeated every 21 days. Anlotinib plus penpulimab had an objective response rate (ORR) of 42.1% and a median overall survival (OS) of 13.0 months.<sup>22</sup>

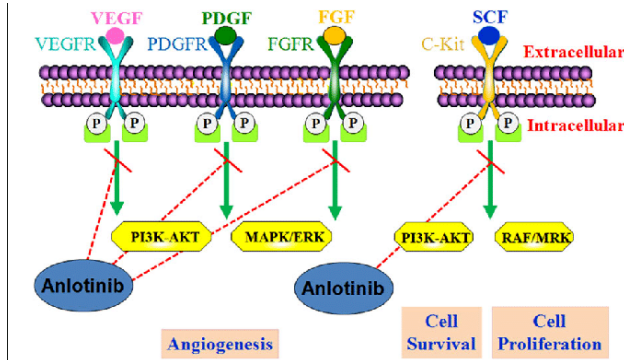


Figure 4: Actions of anlotinib

2.11. Diagram adopted from

Guoshuang Shen et al, Anlotinib: a novel multi-targeting tyrosine kinase inhibitor in clinical development, Journal of Hematology & Oncology (2018) 11:120

2.12. Somatostatin receptor 2

Somatostatin receptor 2 (SSTR2) is overexpressed in a majority of neuroendocrine neoplasms, including small-cell lung carcinomas. 48% of carcinomas expressed SSTR2. satoreotide, targeting extensive stage small cell lung cancer

(ES-SCLC), is being evaluated.<sup>23</sup>

2.13. Radiotherapy in SCLC

Chemoimmunotherapy is the first-line treatment for extensive-stage small-cell lung cancer (ES-SCLC). The addition of radiotherapy after first-line treatment for ES-SCLC can further improve local control. Radiotherapy is given once or twice daily for 5 days / week, for 3 to 7 weeks. Thoracic radiotherapy in addition to prophylactic cranial irradiation can be considered for all patients with ES-SCLC who respond to chemotherapy.<sup>24</sup>

2.14. Surgery in SCLC

The role of surgery in the integrated management of small cell lung cancer remained under investigation with retrospective studies demonstrating 5 year survival of approximately 50% for stage I disease. Lobectomy improved the OS in patients with Stage IIb disease. There was no statistically significant difference in survival between the surgery and the nonsurgery groups in patients with stage IIB disease. Surgery is not an option in later stages as the disease spreads rapidly.<sup>25,26</sup>

2.15. Vaccines

GD3 is a cell membrane ganglioside which has been shown to be overexpressed in approximately 60% of SCLC tumors, and has been investigated as a potential vaccine target for SCLC. The anti-idiotype vaccine to the GD3 ganglioside, BEC-2, has recently been tested in a phase III trial.

(IFN- $\alpha$ ) is a cytokine that stimulates immune response and promotes antigen presentation on tumor cells. Two important studies evaluated the role of IFN-alpha in SCLC.<sup>27</sup>

3. Discussion

The clinical management of small cell lung cancer still a challenge for clinicians. Poor prognostic factors in SCLC include weight loss, increased age, male sex, elevated lactate dehydrogenase (LDH) and low sodium, syndrome of inappropriate antidiuretic hormone secretion (SIADH) and impaired performance status (PS). The following sequence is followed for initial and later stages of SCLC.

New treatments are needed in order to improve the prognosis of Extensive stage-SCLC, as median survival with current standard treatment is still remains 9–10 months from diagnosis. About 60 to 80 percent of SCLC patients respond fairly well to first-line therapy; however, the majority of SCLC tumors develop resistance to chemotherapy, leading to disease progression. SCLC that comes back after first-line treatment is known as recurrent SCLC. The general survival rate at 5 years for localized SCLC (confined to the lung) is 27%. For SCLC that has spread within the chest area,

**Table 2:** Line of therapy for SCLC

SCLC	Management
Early Stage	<ul style="list-style-type: none"> <li>• Surgery or Stereotactic Body Radiation Therapy (linear accelerator or proton beam) (only rarely)</li> <li>• Chemotherapy</li> <li>• Radiation</li> <li>• Palliative care</li> </ul>
Extensive Stage	<ul style="list-style-type: none"> <li>• Chemotherapy</li> <li>• Radiation (for symptom amelioration)</li> <li>• Immunotherapy</li> <li>• Palliative care</li> </ul>

survival rate at 5 years is 16%.

The first line treatment, etoposide or irinotecan with cisplatin or carboplatin provides better response rates. Platinum-etoposide based induction chemotherapy along with surgery in stage I-IIIa SCLC with 3 year survival rates of 74 % for stage I and II and 43% for stage IIIa disease are common observations.

The strategy of combining platinum/doublet and the PD-L1 inhibitor atezolizumab has demonstrated improved outcomes in the front-line setting. The PD-1 inhibitor pembrolizumab has been voluntarily withdrawn for its indication in patients with metastatic small cell lung cancer (SCLC) after at least 2 prior lines of therapy.

**Table 3:** Utility of targeted therapies

- Cause cancer cell death rapidly
- Carry other drugs to tumor & cut off blood flow
- Make cancer cells more responsive to immune system
- Prevent / block interrupt cell growth
- Target defects in cancer cells

Immunotherapy has provided a brief response, although the prognosis remains poor, even after the advent of new drugs. With the advent of new therapies, the extension of life span in SCLC is slightly improved .5%–10% of patients will achieve long-term disease remission. Second and subsequent lines of therapy rarely produce durable responses.

#### 4. Source of Funding

None.

#### 5. Conflict of Interest


None.

#### References

- Farago A, Keane FK. Current standards for clinical management of small cell lung cancer. *Transl Lung Cancer Res.* 2018;7(1):69–79.
- Raso M, Bota-Rabassedas N, Wistuba II. Pathology and Classification of SCLC. *Cancers.* 2021;13(4):820. doi:10.3390/cancers13040820.
- Rudin C, Brambilla E, Faivre-Finn C, Sage J. Small-cell lung cancer. *Nat Rev Dis Primers.* 2021;7(1):3. doi:10.1038/s41572-020-00235-0.
- Soomro Z, Youssef M, Yust-Katz S, Jalali A, Patel AJ, Mandel J, et al. Paraneoplastic syndromes in small cell lung cancer. *J Thorac Dis.* 2020;12(10):6253–63.
- Sagmen SB, Dogan C, Comert S, Kiral N, Parmaksiz ET, Fidan A, et al. The importance of Ki-67 proliferation index in small cell lung cancer. *Eur Respir J.* 2020;56:1732. doi:10.1183/13993003.congress-2020.1732.
- Bebb DG, Murray C, Giannopoulou A, Felip E. Symptoms and Experiences with Small Cell Lung Cancer: A Mixed Methods Study of Patients and Caregivers. *Pulm Ther.* 2023;9(3):435–50.
- Travis WD. Update on small cell carcinoma and its differentiation from squamous cell carcinoma and other non-small cell carcinomas. *Mod Pathol.* 2012;25(1):18–30.
- Yang S, Zhang Z, Wang Q. Emerging therapies for small cell lung cancer. *J Hematol Oncol.* 2019;12(1):47. doi:10.1186/s13045-019-0736-3.
- Gomezrandulfe I, Leporati R, Gupta B, Liu S, Califano R. Recent advances and future strategies in first-line treatment of ES-SCLC. *Eur J Cancer.* 2024;200:113581. doi:10.1016/j.ejca.2024.113581.
- Giunta EF, Addeo A, Rizzo A, Banna GL. First-Line Treatment for Advanced SCLC: What Is Left Behind and Beyond Chemotherapy. *Front Med (Lausanne).* 2022;9:924853. doi:10.3389/fmed.2022.924853.
- Serzan M, Farid S, Liu SV. Drugs in development for small cell lung cancer. *J Thorac Dis.* 2020;12(10):6298–307.
- Manzo A, Sforza V, Carillio G, Palumbo G, Montanino A, Sandomenico C, et al. Lurbinectedin in small cell lung cancer. *Front Oncol.* 2022;12:932105. doi:10.3389/fonc.2022.932105.
- Rudin CM, Hann CL, Garon EB, Oliveira MR, Bonomi PD, Camidge DR, et al. Phase II study of single-agent navitoclax (ABT-263) and biomarker correlates in patients with relapsed small cell lung cancer. *Clin Cancer Res.* 2012;18(11):3163–9.
- Du R, Huang C, Liu K, Li X, Dong Z. Targeting AURKA in Cancer: molecular mechanisms and opportunities for Cancer therapy. *Mol Cancer.* 2021;20(1):15. doi:10.1186/s12943-020-01305-3.
- Barayan R, Ran X, Lok BH. PARP inhibitors for small cell lung cancer and their potential for integration into current treatment approaches. *J Thorac Dis.* 2020;12(10):6240–52.
- Rudin CM, Reck M, Johnson ML, Blackhall F, Hann CL, Chih-Hsin J, et al. Emerging therapies targeting the delta-like ligand 3 (DLL3) in small cell lung cancer. *J Hematol Oncol.* 2023;16:66. doi:10.1186/s13045-023-01464-y.
- Ahn MJ, Cho BC, Felip E, Korantzis I, Ohashi K, Majem M, et al. Tarlatamab for Patients with Previously Treated Small-Cell Lung Cancer. *N Engl J Med.* 2023;389(22):2063–75.
- Fassl A, Geng Y, Sicinski P. CDK4 and CDK6 kinases: from basic science to cancer therapy. *Science.* 2022;375(6577):1495. doi:10.1126/science.abc1495.
- Hamilton G, Rath B, Voutsina A, Mavroudis D, Georgoulis V. Targeting angiogenesis in small cell lung cancer. *Transl Lung Cancer Res.* 2017;5(4):389–400.
- Sun JM. Pazopanib maintenance after first-line etoposide and platinum chemotherapy in patients with extensive disease small-cell lung cancer: a multicentre, randomised, placebo-controlled Phase II study (KCSG-LU12-07). *Br J Cancer.* 2018;118(5):648–53.
- Goto K, Ohe Y, Shibata T, Seto T, Takahashi T, Nakagawa K, et al. Combined chemotherapy with cisplatin, etoposide, and irinotecan versus topotecan alone as second-line treatment for patients with sensitive relapsed small-cell lung cancer (JCOG0605): a multicentre, open-label, randomised phase 3 trial. *Lancet Oncol.* 2016;17(8):1147–57.
- Zhang C. Efficacy and safety of anlotinib plus penpulimab as second-line treatment for small cell lung cancer: A multicentre, open-label, single-arm phase II trial. *Cancer Pathogenesis and Therapy.* 2024;.
- Park H, Tseng SC, Sholl LM, Hatabu H, Awad MM, Nishino M, et al. Molecular Characterization and Therapeutic Approaches to Small Cell Lung Cancer: Imaging Implications. *Radiology.* 2022;305(3):512–25.

24. Tjong MC, Mak DY, Shahi J, Li GJ, Chen H, Louie AV, et al. Current Management and Progress in Radiotherapy for Small Cell Lung Cancer. *Front Oncol.* 2020;10:1146. doi:10.3389/fonc.2020.01146.
25. Koletsis E, Prokakis C, Karanikolas M, Apostolakis E, Dougenis D. Current role of surgery in small cell lung carcinoma. *J Cardiothorac Surg.* 2009;4:30. doi:10.1186/1749-8090-4-30.
26. Huang Z, Liu Y, Wang S, Ai K, Zhang P. Kaixing Ai & Peng Zhang. Surgery for stage IIB-III B small cell lung cancer. *World J Surg Oncol.* 2023;21:333. doi:10.1186/s12957-023-03196-2.
27. Mamdani H, Induru R, Jalal SI. Novel therapies in small cell lung cancer. *Transl Lung Cancer Res.* 2015;4(5):533–44.

### Author biography

**Sunil Chaudhry**, Consultant  <https://orcid.org/0000-0002-5863-3025>

**Abhijit Trailokya**, Medical Head

**Cite this article:** Chaudhry S, Trailokya A. Conceptual therapeutics for small cell lung cancer. *IP Indian J Immunol Respir Med* 2024;9(3):98-103.