

Metastatic adenocarcinoma of lung mimicking spinal tuberculosis

Swapnil Manaji Thorve^{1,*}, Vishwas Gupta², Pralhad Prabhakar Prabhudesai³

¹Consultant, HBT Medical College & RN Cooper Hospital, ²DNB Resident, ³Consultant, Lilavati Hospital & Research Centre, Maharashtra

***Corresponding Author:**

Email: thorves@yahoo.com

Abstract

Clinically, it is sometimes difficult to distinguish an infection of the spine from a metastasis. Spinal tuberculosis is common in India and adenocarcinoma of the lung is also rising. Radiologically, the hallmark of spinal infection is an erosion of adjacent vertebral endplates and narrowing of the disc space with or without a paravertebral shadow. Metastasis typically does not involve the disc space with erosion of the adjacent vertebral endplates. It usually presents as a lytic/sclerotic lesion in the vertebral body or 'winkle owl' sign. These distinguishing features of infection versus metastasis are not certainties. A biopsy is mandatory whenever in doubt or patient is not responded with provisional treatment.

We present a case of 45 year old male with so-called radiological features of spinal tuberculosis infection, which turns out to be a metastatic adenocarcinoma of the lung.

Keywords: Adenocarcinoma; Extrapulmonary; Metastasis; Spinal tuberculosis; Tuberculosis

Introduction

Tuberculosis is a serious infectious disease in India. According to WHO global TB report 2015, 22 lakh people in India suffer from tuberculosis of which 71000 are multi drug resistant tuberculosis. Spinal tuberculosis accounts for 5% of all cases of tuberculosis cases. In the case of spinal tuberculosis, two or more contiguous vertebrae are usually involved due to haematogenous spread of bacteria since one vertebral artery feeds two adjacent vertebrae. Adenocarcinoma has replaced squamous cell carcinoma as the commonest lung cancer. Skeletal metastasis is commonly seen in late stages. In India where tuberculosis is so common, many patients are started on empirical antitubercular treatment based on clinical and radiological findings without histopathological and microbiological evidence thus missing other diseases. This is a case of 45 year old man who was misdiagnosed as spinal tuberculosis which later turned out to be metastatic adenocarcinoma of lung.

Case Report

A 45 year old man, resident of Mumbai presented with backache and lower limb weakness since 2 months. The pain was deep seated, pricking type with no aggravating or relieving factors. The pain progressed and was associated with numbness of lower limbs which made him homebound. He had a history of loss of weight of 10kgs in last 6

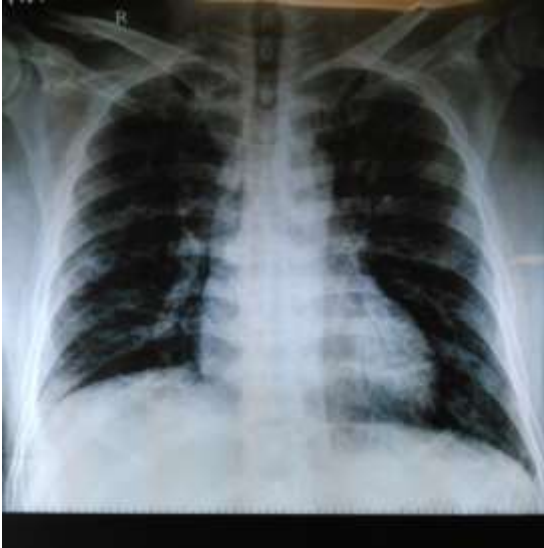months. The patient had no past history of tuberculosis or history of contact with tuberculosis. He was a non-smoker and had no family history of carcinoma.

Clinically patient was weak, with decreased sensation over lower limbs and reduced power of lower limb muscles. MRI spine was done which showed multilevel vertebral body hyperintense abnormalities, liquefaction of T12-L1 disc and associated psoas and paraspinal muscle abscess. Biopsy of lesion was done and patient was started on empiric antitubercular treatment till culture report was awaited.

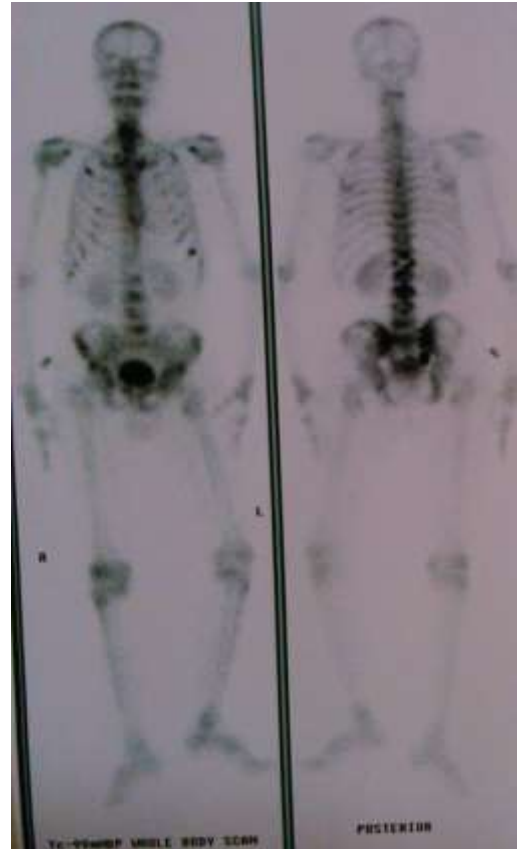
Patient failed to improve with antitubercular treatment. Gene Xpert was negative for mycobacterium tuberculosis and no mycobacterial growth was seen on MGIT culture. This called for a thorough investigation. Bone scan showed abnormally increased osseous activity in skull, cervical, dorsal and lumbar vertebrae, multiple ribs, both pelvic bones, left scapula, partial collapse of L1 vertebral body and sclerotic areas in sacrum.

CT guided biopsy was done from iliac crest which showed metastatic adenocarcinoma (moderately differentiated). PET scan showed evidence of ground glass lesion in upper lobe of left lung, ground glass infiltrates and nodular lesions in all the lung fields, bilateral pleural effusion and left adrenal, retroperitoneal lymph nodes.

Patient was started on chemotherapy and clinically improved initially. However, he deteriorated due to secondary pulmonary infection and succumbed to pulmonary embolism after 4th cycle of chemotherapy.

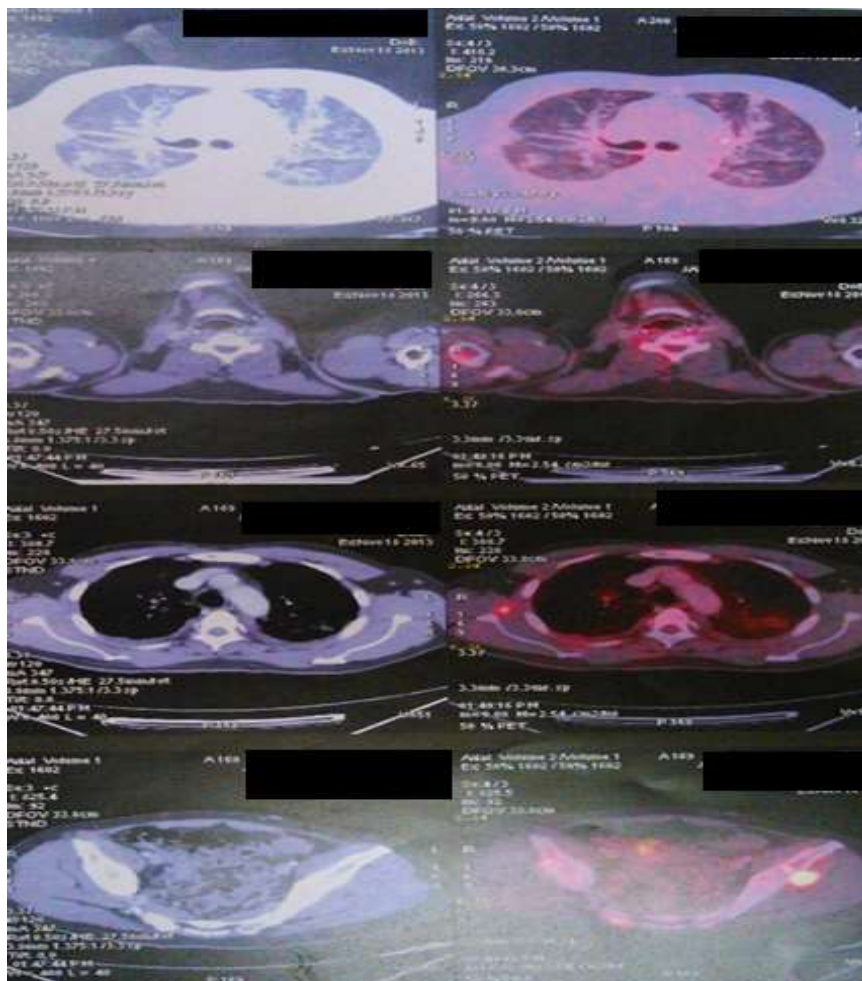


- Chest x-ray: Fine nodular shadows seen in basal region



- Bone scan: Abnormally increased osseous activity in skull, cervical, dorsal and lumbar vertebrae, multiple ribs, both pelvic bones, left scapula.
- Partial collapse of L1 vertebral body.
- Sclerotic areas in sacrum.

f/s/o- multiple skeletal metastasis/disseminated skeletal infection



PET scan: Evidence of active disease is seen in ground glass lesion in upper lobe of left lung, ground glass infiltrates and nodular lesions in all the lung fields, b/l pleural effusion and left adrenal, retroperitoneal lymph nodes.

Scan s/o of primary neoplasm in the lung.

Discussion

Adenocarcinoma has replaced squamous cell carcinoma as the leading lung cancer cell type among both men and women in many parts of world.¹ The incidence of adenocarcinoma in India is also on rise.² Adenocarcinoma naturally grows slowly and usually metastasize later in its course than small cell lung carcinoma. The spine, pelvis, femur, ribs and skull are commonly involved in bone metastasis. Spine is the most common site for adenocarcinoma metastasis.³

The clinical presentation of metastatic spine disease is general weakness, pain, neurological deficit and progressive deformity. Pain is the most common presenting symptom in patients with metastatic spinal tumors.⁴ The etiology of pain may be tumor spread, spinal instability, nerve root or dural irritation, or direct cauda equina or spinal cord

compression. Pain may also be due to bony destruction or invasion of paraspinal tissues, such as muscles or ligaments.⁴

India is endemic for tuberculosis. Skeletal tuberculosis (TB) accounts for 10 to 35 percent of cases of extrapulmonary tuberculosis. Pott's disease is the most common form of skeletal tuberculosis and comprises approximately half of musculoskeletal TB cases.⁵ The onset of clinical symptoms of spinal tuberculosis are insidious. Backache, fever, paraparesis, sensory disturbance, and bladder dysfunction are common symptoms of presentation. All these symptoms may be interpreted as stemming from an underlying paravertebral mass.⁶

Magnetic resonance imaging (MRI) is very sensitive for both infection and metastasis. MRI findings in tuberculous spondylitis commonly seen

are destruction of contiguous vertebral bodies, disc spaces involvement, end plates destruction and paravertebral abscesses.⁷ The characteristic MRI findings are loss of cortical definition, intra-osseous abscesses with rim enhancement, paraspinal abscess, subligamentous spreading of inflammatory tissue with relative disc preservation.⁸

As incidence of tuberculosis high in India, it is not uncommon for physicians in India to diagnose spine tuberculosis on clinical and radiological findings. Some case reports support empirical treatment for spine tuberculosis.⁹

The most reliable minimally invasive test for diagnosis is CT guided biopsy. Biopsy is recommended for patients who have spine lesions with no known primary malignant tumor for histopathology and suspected spine infection without known organism for culture and sensitivity.¹⁰ Presentation with spinal metastases may not be a terminal event. The aim of surgery is to relieve pain and improve neurological functions. Surgical decompression with laminectomy is required when the spinal canal is compromised by vertebral collapse or infiltration of tumor and when there is spinal instability due to the pathological vertebral collapse or extensive destruction of the posterior elements, surgical stabilization with instrumentations may be needed.¹¹

Radiotherapy is a key component of palliative treatment for pain from bone metastasis and advanced stage IV adenocarcinoma of lung. Although adenocarcinoma is much less chemosensitive than small cell lung carcinoma, chemotherapy can improve survival and quality of life in patients with adenocarcinoma.^{12,13}

To conclude we believe that metastatic lesion in spine can mimic tuberculosis in clinical and radiological presentation and hence tissue must be obtained for histological and culture diagnosis. Tissue diagnosis either open or CT guided biopsy must be done and then further treatment planning should be done. If decision is taken to treat tuberculosis without biopsy then patient should be followed up on regular basis and clinical improvement should be assessed at regular intervals.

Acknowledgements: Nil

Conflict of interests: None declared

References

1. Dela Cruz C, Tanoue L, Matthay R. Lung Cancer: Epidemiology, etiology, and prevention. *Clinics in chest medicine*. 2011;32(4):605-644.
2. Malik P, Sharma M, Mohanti B, Shukla N, Deo S, Mohan A, et al. Asian pacific journal of cancer prevention. 2013;14(1):489-494.
3. D'Antonio C, Passaro A, Gori B, Del Signore E, Migliorino M, Ricciardi S, et al. Bone and brain metastasis in lung cancer: recent advances in therapeutic strategies. *Therapeutic Advances in Medical Oncology*. 2014;6(3):101-114.
4. Lee C, Jung C. Metastatic spinal tumor. *Asian Spine J*. 2012;6(1):71.
5. Gautam MP, Karki P, Rijal S, Singh R. Pott's spine and Pott's paraplegia. *J Nep Med Assoc*. 2005;44(159):106-15.
6. Garg R, Somvanshi D. Spinal tuberculosis: A review. *The Journal of Spinal Cord Medicine*. 2011;34(5):440-454.
7. Sharif H, Clark D, Aabed M, Haddad M, al Deeb S, Yaqub B, et al. Granulomatous spinal infections: MR imaging. *Radiology*. 1990;177(1):101-107.
8. Jung N, Jee W, Ha K, Park C, Byun J. Discrimination of tuberculous spondylitis from pyogenic spondylitis on MRI. *American Journal of Roentgenology*. 2004;182(6):1405-1410.
9. Patil S, Mohite S, Varma R, Bhojraj S, Nene A. Non-Surgical Management of Cord Compression in Tuberculosis: A Series of Surprises. *Asian Spine J*. 2014;8(3):315.
10. Eismont FJ, Green BA, Brown MD. Coexistent infection and tumor of the spine. A report of three cases. *J Bone Joint Surg Am*. 1987;69:452-458.
11. Bach F, Agerlin N, Sorensen JB, Rasmussen TB, Dombrowsky P, Sørensen PS, et al. Metastatic spinal cord compression secondary to lung cancer. *J Clin Oncol*. 1992;10:1781-1788.
12. Klimo PJ, Schmidt MH. Surgical management of spinal metastases. *Oncology*. 2004;9(2):188-196.
13. Pavlidis N, Briasoulis E, Hainsworth J, Greco F. Diagnostic and therapeutic management of cancer of an unknown primary. *European Journal of Cancer*. 2003;39(14):1990-2005.