



Case Report

A closer look -Asymptomatic cysticercosis unveiled during COPD exacerbation: A case report

Nirajkumar Dhakare¹, Radha Munje¹, Gyanshankar Mishra^{1*}, Jitesh Atram¹

¹Dept. of Respiratory Medicine, Indira Gandhi Government Medical College, Nagpur, Maharashtra, India



ARTICLE INFO

Article history:

Received 18-04-2024

Accepted 22-05-2024

Available online 10-07-2024

Keywords:

Disseminated cysticercosis

Neurocysticercosis

COPD

Praziquantel

Albendazole

ABSTRACT

Disseminated cysticercosis a widespread dissemination of cysticerci throughout the whole body is a rare manifestation of cysticercosis. This case report describes a unique presentation of asymptomatic and incidentally diagnosed case of disseminated cysticercosis which is rare and with very few cases being reported in India to date. This 62-year-old male presented to the emergency department with acute onset breathlessness due to an exacerbation of chronic obstructive pulmonary disease (COPD). Routine Chest radiograph revealed an incidental suspicion of disseminated cysticercosis. After treating exacerbation of COPD, he was further evaluated for cysticercosis and active infection. Following confirmation of disseminated cysticercosis, a multidisciplinary treatment approach was implemented to address both COPD and neurocysticercosis.

This is an Open Access (OA) journal, and articles are distributed under the terms of the [Creative Commons Attribution-NonCommercial-ShareAlike 4.0 License](https://creativecommons.org/licenses/by-nc-sa/4.0/), which allows others to remix, tweak, and build upon the work non-commercially, as long as appropriate credit is given and the new creations are licensed under the identical terms.

For reprints contact: reprint@ipinnovative.com

1. Introduction

Cysticercosis is a parasitic disease caused by *T. Solium* larva and it is a major public health problem in developing countries. Neurocysticercosis is the most common type of cysticercosis. Widespread dissemination of the cysticerci can result in the involvement of almost any organ of the body.¹

Human cysticercosis can result in devastating effects on human health. The larvae (cysticerci) may develop in the muscles, skin, eyes, and the central nervous system. When cysts develop in the brain, the condition is referred to as neurocysticercosis (NCC). Symptoms include severe headache, blindness, convulsions, and epileptic seizures, and can be fatal.²⁻⁴

2. Case Report

We hereby report a case of a 62-year-old male farmer from central India, who presented in the emergency room with complaints of cough and breathlessness for 8 days, and chest pain for 6 days. On examination, the patient's oxygen saturation was 80% on room air. His arterial blood gas was suggestive of respiratory acidosis. The patient was admitted to the intensive respiratory care unit (IRCUCU) and put on non-invasive ventilatory support.

Chest radiography was done which surprisingly revealed calcific specks giving a characteristic appearance which has been termed rice-grain calcifications (Figure 1).

The patient was a mixed diet consumer but a non-pork eater. He smoked bidi for 30 years and left since one month and was an alcoholic for 30 years. On laboratory investigation hemoglobin was 13.5 gm%, total lymphocyte count (TLC) of 7650/mm³, and differential leucocyte count (DLC) of Polymorphs 91% and Lymphocytes 6%. Routine biochemical investigation including glucose, renal, and liver function tests were within normal limits. Test for

* Corresponding author.

E-mail address: gpmishra81@gmail.com (G. Mishra).

human immunodeficiency virus (HIV) using enzyme-linked immunosorbent assay (ELISA) was negative for both HIV 1 and 2. An electrocardiogram (ECG) examination showed a P pulmonale in lead II. Fundus examination was normal. Sputum cytology did not show Scolices and chitinous walls. Serology for *Cysticercus* (*Tanenia Solium*) IgG was equivocal.

Ultrasonography of the neck showed normal thyroid except for a single calcific focus and strap muscles of the neck with intramuscular multiple elongated calcific foci. Similar findings were seen on ultrasonography of the upper and lower limbs.

Contrast-enhanced computed tomography (CECT) scan of thorax and abdomen showed small elliptical calcified granulomas in subcutaneous, intermuscular, and intramuscular planes throughout the visualized part of the neck and thoracoabdominal body wall, right crura of the diaphragm, bilateral iliopsoas muscles suggestive of disseminated myo-cysticercosis. Centriacinar emphysematous changes in bilateral lung parenchyma predominantly in the right lower lobe with hyperinflation of the right upper lobe in the form of retrosternal herniation & flattening of the bilateral dome of diaphragm suggested changes of COPD. (Figure 2)

Magnetic resonance imaging (MRI) scan of the brain and spine showed multiple small intra-axial ring-enhancing lesions in the cerebral parenchyma and paraspinal muscles of the back suggestive of disseminated cysticercosis. (Figures 3 and 4)

The diagnosis was confirmed through a comprehensive approach, which included radiograph, ultrasonography, serological tests, CT, and MRI scans, suggesting an infective aetiology- disseminated *Cysticercosis*. A multidisciplinary treatment approach is being implemented. Management of Chronic Obstructive Pulmonary Disease (COPD) exacerbation during the hospitalization period encompasses non-invasive ventilatory support and the administration of inhaled bronchodilators. Prior tablet Prednisolone 40mg once a day was given and then advised in tapering doses to prevent anaphylactic reactions and seizures. Antiparasitic agents albendazole 400mg twice a day for 30 days and praziquantel 600mg QID for 15 days, were administered for cysticercosis. Screening of the patient's family was found to be negative for active infection of cysticercosis. For management of COPD, based on severity, the patient was prescribed a Metered Dose Inhaler (MDI) containing Formoterol, Glycopyrronium and Budesonide, and advised to be taken with a spacer device on discharge. Follow-up care involved pulmonary rehabilitation, a crucial component aimed at optimizing respiratory function. The patient and his family were educated regarding this preventable and eradicable infection.

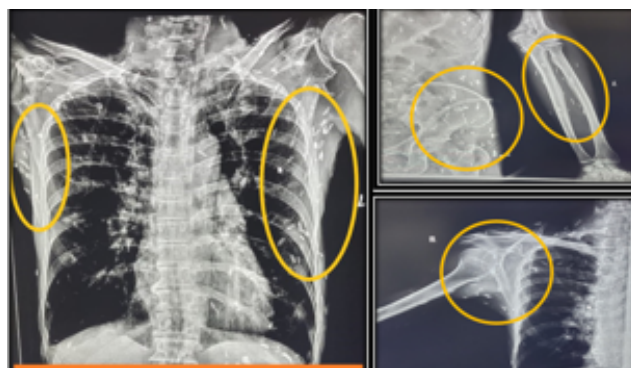


Figure 1: Chest radiograph suggestive of calcific specks giving a characteristic appearance of “rice-grain calcifications”

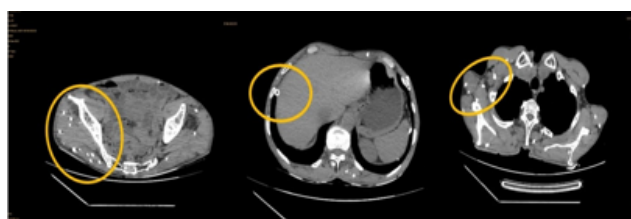


Figure 2: Calcified granulomas in subcutaneous, intermuscular and intramuscular plane showing

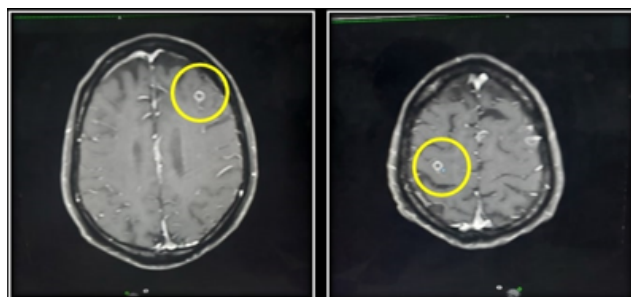


Figure 3: MRI Scan of brain showing intra-axial ring enhancing lesions

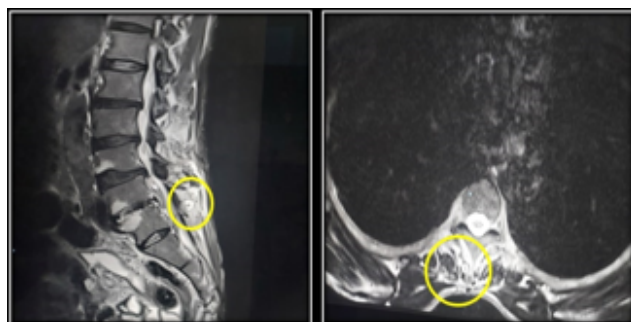


Figure 4: MRI scan of the spine showing ring enhancing lesions

3. Discussion

This case report underscores the significance of recognizing incidental findings of cysticercosis, leading to a subsequent diagnosis of disseminated cysticercosis. It is noteworthy that the patient initially presented to the emergency room with symptoms of COPD with exacerbation, despite being asymptomatic and unidentified for decades with cysticercosis.

Vegetarians get this infection through contaminated food or water, unhygienic practices, cross-contamination, exposure to infected individuals or animals, and changing dietary habits. Healthcare providers should consider the possibility of atypical transmission routes in patients presenting with NCC-like symptoms who do not have a history of consuming pork. Our patient had a mixed diet habit but denied any history of pork eating.

In such cases, a thorough diagnostic workup becomes crucial. The disease is commonly diagnosed with CT and MRI scans, especially in cases of neurocysticercosis. Biopsy is usually achieved by excision of the subcutaneous cysticerci, found in 4–25 % of patients with NCC. Serological tests are the most preferred and reliable tests for NCC diagnosis in India. The enzyme-linked immunoelectrotransfer blot (EITB) assay uses affinity-purified glycoprotein antigens to detect antibodies to *T. Solium*. This test has almost 100 % specificity but low sensitivity (50–60 %), especially in patients with a single intracranial cysticercus. Human faeces can be examined microscopically for the presence of *Taenia* eggs, the technique is otherwise insensitive in that it cannot distinguish between different species of the genus (*T. solium*, *Taenia saginata*, and *Taenia asiatica*).⁵

The management of cysticercosis includes corticosteroids (prednisolone, dexamethasone) to reduce inflammation. Antiepileptic/anticonvulsant medications (phenytoin, carbamazepine) to prevent seizures. Antiparasitic medications (Albendazole, praziquantel) are used to treat infections. Surgery to remove the cyst or put tube (shunt) to redirect the fluid in your brain.⁶

In cases of disseminated cysticercosis, most institutions used albendazole in a dose of 15 mg/kg/day for 30 days. Few other institutions applied praziquantel in a dose of 50mg/kg/day for 15-20 days. The advantage of albendazole over praziquantel is that the former also destroys subarachnoid and ventricular cysts because of its better penetration in CSF, as well as the fact that it can be administered jointly with corticosteroid agents for anti-inflammatory therapy.⁷

Combined administration of praziquantel and albendazole as was administered in our patient, can also be effective as both drugs exert a different mode of action on the parasite and praziquantel increases the bioavailability of albendazole sulfoxide when the two are given together.⁵

The antiparasitic drugs, inhalation therapy, and pulmonary rehabilitation constituted a combined therapeutic strategy aimed at tackling both parasitic dissemination and respiratory manifestations in the patient. This underscores the importance of a multidisciplinary approach in managing complex cases like disseminated cysticercosis.

In the management of COPD, inhaled bronchodilators long-acting beta-2 agonists (LABAs), and long-acting muscarinic antagonists (LAMAs), are prescribed to prevent or alleviate symptoms.⁸ Combination therapy with LABA and a LAMA is more effective in reducing COPD exacerbations compared to monotherapy. In severe cases, an inhaled corticosteroid may also be added as was added in our patient. The use of a single inhaler containing these medications improves adherence, potentially leading to better overall outcomes in COPD management. Regular follow-up with healthcare providers is essential to assess treatment effectiveness and make any necessary adjustments to the therapeutic plan.

4. Conclusion

Disseminated cysticercosis can be an incidental finding even when the presenting complaints lead to a different disease like COPD in the current case. To highlight the rarity of disseminated cysticercosis, its potential involvement in various organs warrants a thorough investigation, especially when multiple neurocysticerci are detected in the brain. An expanded imaging evaluation or other appropriate diagnostic tests targeting the spine and other organs can aid in confirming or ruling out dissemination, allowing for a more comprehensive multidisciplinary approach to treatment. Patients who are not treated efficiently and have active cysts remain at risk to both themselves as well as for the community.

5. Source of Funding

None.

6. Conflict of Interest

None.

References


1. Kraft R. Cysticercosis: an emerging parasitic disease. *Am Fam Physician*. 2007;76(1):91–6.
2. WHO. Cysticercosis WHO [Internet]. [cited 2024 Mar 9]. Available from: <https://www.who.int/news-room/fact-sheets/detail/taeniasis-cysticercosis>.
3. Niknejad M, Baba Y, Elfeky M. Rice grain calcification. *Radiopaedia*. 2021;[cited 2024 Mar 9]. Available from: <https://radiopaedia.org/articles/rice-grain-calcification#:~:text=Rice%20grain%20calcification%20is%20characteristic,granulomatous%20change%20and%20become%20calcified>. doi:10.53347/rID-21565.
4. Shahi MK, Singh JA, Singh A. Disseminated neurocysticercosis in a vegetarian: An intriguing case report. *Indian J Microbiol Res*.

- 2023;10(4):249–52.
5. Ahmad R, Khan T, Ahmad B, Misra A, Balapure AK. Neurocysticercosis: a review on status in India, management, and current therapeutic interventions. *Parasitol Res.* 2017;116(1):21–33.
 6. Nash TE, Garcia HH. Diagnosis and treatment of neurocysticercosis. *Nature Reviews Neurology.* 2011;7(10):584–94.
 7. Park SY, Kong MH, Kim JH, Song KY. Disseminated Cysticercosis. *J Korean Neurosurg Soc.* 2011;49(3):190–3.
 8. Global strategy for prevention, diagnosis and management of COPD: 2023 report. [cited 2024 Mar 9]. Available from: <https://goldcopd.org/2023-gold-report-2>.

Author biography

Nirajkumar Dhakare, Junior Resident

Radha Munje, Professor and Head

Gyanshankar Mishra, Associate Professor  <https://orcid.org/0000-0002-0084-839X>

Jitesh Atram, Assistant Professor

Cite this article: Dhakare N, Munje R, Mishra G, Atram J. A closer look -Asymptomatic cysticercosis unveiled during COPD exacerbation: A case report. *IP Indian J Immunol Respir Med* 2024;9(2):75-78.