

Massive pleural effusion as a result of painless acute pancreatitis: A rare presentation

Sujeet Raina^{1*}, Shyam Sunder CM², Baldev Singh Rana³, Guru Dutt Sharma⁴

^{1,3}Assistant Professor, ²Ex-Post Graduate Student, ⁴Professor, Department of Medicine, Dr. RPGMC, Himachal Pradesh

***Corresponding Author:**

Email: sujeetraina@gmail.com

Abstract

We report a patient who presented to us with massive left sided pleural effusion. While investigating him for the etiology of pleural effusion, acute pancreatitis was unexpectedly diagnosed on computed tomography. The case is reported to highlight the clinical condition of massive pleural effusion as a presentation of painless acute pancreatitis.

Keywords: Pleural fluid, pancreas, painless

Introduction

Pleural effusion accompanies non-malignant pancreatic diseases like acute pancreatitis, pancreatic abscess, chronic pancreatitis with pseudocyst and pancreatic ascites. Abdominal pain is present at the onset of most attacks of acute pancreatitis, but the timing of abdominal pain is variable. Pain is absent in 5% to 10% of acute attacks, and a painless presentation may be a feature of serious fatal disease.¹ Pancreaticopleural fistula (PPF) is an uncommon but serious complication of acute, and more commonly chronic, pancreatitis. The precise incidence of PPF is unknown, but it is estimated to occur in 0.4% of patients with pancreatitis. PPF typically presents as massive pleural effusion due to communication between the pancreas and pleural space. In the absence of pain and predominance of thoracic symptoms often causes a diagnostic dilemma as initial efforts are directed toward finding a thoracic pathology, thus resulting in a delay in diagnosis.² We report this case for two reasons. First, to highlight the clinical condition of left side massive pleural effusion as an initial presentation of acute pancreatitis. Second, painless acute pancreatitis was not an etiological diagnosis and was unexpectedly diagnosed while contrast enhanced computed tomography thorax was performed. This is a rare confluence of two clinical features as a presentation of acute pancreatitis.

Case History

A 40 yrs. male presented to the emergency department of Dr. Rajendra Prasad Government

Medical College in Himachal Pradesh, India in September, 2014. He gave history of progressive dyspnea for 15 days which had increased for last 12 hours with no history of orthopnea, chest pain, palpitations, cough, fever, vomiting, pain abdomen, trauma or prolonged immobility. There was history of decreased urine output for last 12 hours. Patient was a driver by occupation, alcoholic with dependence (fulfilled CAGE criteria) and had last intake of alcohol 24 hours back. There was no history of similar complaints in past. No significant past history of any other illness was present. Review of other systems was unremarkable.

At the time of admission patient was afebrile, pulse was 110/minute and blood pressure recorded in both arms in supine position was 70mm Hg. Respiratory rate was 36/min and SpO₂ on pulse oximetry was 75% at ambient room air. Respiratory system examination was consistent with left side pleural effusion with tracheal shift to right. Abdomen was soft, non-tender with no ascites. Examination of other systems was normal. On investigations, hemoglobin was 14.1 gm/dl, total leucocyte count was 20,000/cmm. Peripheral blood smear revealed normocytic normochromic picture with neutrophilia. Biochemical investigations were: Random blood glucose-124mg/dl, creatinine-1.0 mg/dL, blood urea nitrogen- 26 mg/dL serum calcium- 9.4 mg%, triglyceride- 130 mg/dL, total protein- 7.2 gm/dL, albumin- 3.5 gm/dL, total bilirubin- 1.1 mg/dL, aspartate transferase- 65 U/L, alanine transferase- 48 U/L alkaline phosphatase- 131 IU/L. Chest X-ray was suggestive of massive pleural effusion on left side, with mediastinal shift

towards right.(Fig. 1a) Electrocardiogram showed sinus tachycardia. Diagnostic and therapeutic thoracocentesis was done which revealed serosanguinous fluid. His symptoms improved after thoracocentesis. With bolus intravenous fluid both blood pressure and urine output improved.

His pleural fluid biochemistry was: protein-4.6g/dl, lactate dehydrogenase-674U/L, glucose-07mg/dl. The pleural fluid ADA was 40.3 U/L. The fluid cytology on microscopic examination showed a total leukocyte count of 26000/cmm (neutrophils 96%) along with few lymphocytes and histiocytes in a hemorrhagic background. Pleural fluid was negative for malignant cells on three occasions. Gram stain did not reveal presence of any organism and fluid was sent for bacterial culture also. Based on these investigations patient was managed with intercostal tube drainage. Empirically ceftriaxone and metronidazole were started pending culture results.

Contrast enhanced computed tomography thorax was done on third day of admission. It revealed partially collapsed left lower lung secondary to left hydropneumothorax with chest

tube in-situ. Additionally it showed acute pancreatitis with necrosis of distal body and tail region, Balthazar grade D modified CT severity index- 9.(Fig. 2) Subsequently pleural fluid amylase was analyzed which was 2314 IU/L. Serum amylase and lipase were also obtained and were 134 IU/L and 652 IU/L respectively. Pleural fluid culture was sterile. Intercostal drain was removed. The patient was managed conservatively and discharged on day 10. Follow up chest x- ray after two weeks revealed resolution of pleural effusion. (Fig. 1b)

Retrospective diagnosis of acute pancreatitis with pancreaticopleural fistula was made. As patient had significant improvement at the time of incidental detection of acute pancreatitis, an endoscopic retrograde cholangiopancreatography (ERCP) or magnetic resonance cholangiopancreatography(MRCP) were not offered for identifying possible pancreaticopleural fistula. With history of significant alcohol consumption, acute pancreatitis was presumed to be alcohol induced pancreatitis.

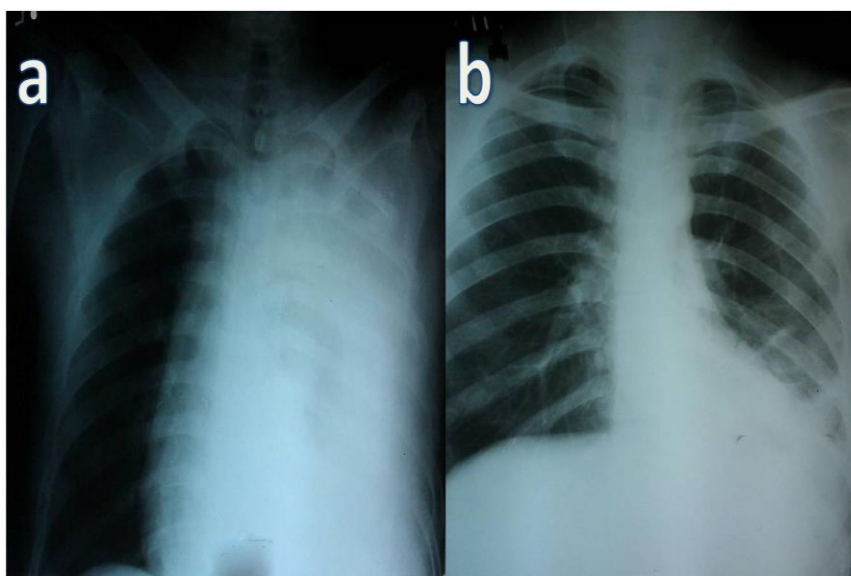


Fig. 1 a: Chest x-ray PA view showing left pleural effusion with mediastinal shift towards right. b: Follow up chest x-ray PA view 2 weeks later showing resolution of pleural fluid

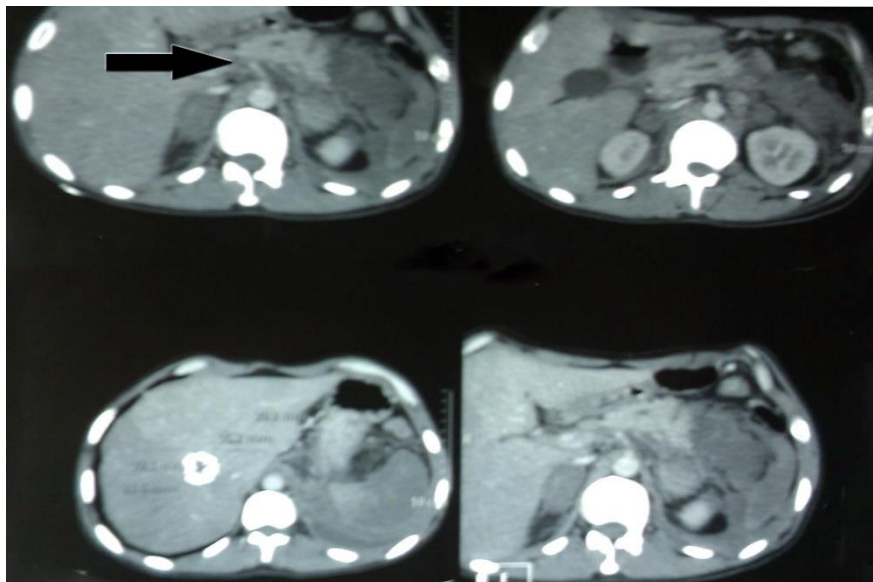


Fig. 2: Contrast enhanced computed tomography abdomen showing necrosis of pancreas in distal body and tail region

Discussion

Respiratory complications of acute pancreatitis are clinically or radiologically detectable in 33% patients and include pulmonary infiltrates or atelectasis (15%), pleural effusions (4%-17%), and pulmonary edema (8%-50%). Presence of pleural effusion is currently considered an indication of severe pancreatitis and not just a marker of the disease. Pleural effusions in acute pancreatitis are usually small, occasionally bloody, and are characterized by high amylase (up to 30 times greater than corresponding serum value), protein (>30 gm/L), and lactic acid dehydrogenase ratio more than 0.6 serum value levels. The pleural fluid glucose level is comparable to that of the serum. The pleural fluid differential white blood cell (WBC) count usually reveals predominantly polymorphonuclear leukocytes and the pleural fluid WBC can vary from 1,000 to 50,000 cells/mm³.³ The majority of pleural effusions (68%) are left sided, 22% are bilateral and 10% are right-sided only. Two main causes of pleural effusion are trans diaphragmatic lymphatic blockage or pancreaticopleural fistulae secondary to leak and disruption of the pancreatic duct or pseudocyst caused by an episode of acute pancreatitis. The leak or disruption is more likely to lead to a pleural effusion if the duct disruption is posteriorly into the retro peritoneum. The pancreatic enzymes can track up into the mediastinum and then rupture into the pleural cavity either left side or bilaterally and so create a connection between the pancreatic duct and

the pleural cavity.⁴ Our patient had low pleural fluid glucose level. The differential diagnosis of low glucose is malignancy, rheumatoid arthritis, hemothorax, parasitic infection, bacterial infection, lupus and tuberculosis. We have ruled out all these causes by the possible investigations in our case. The reasons for low glucose remain obscure. Acute pancreatitis is an acute inflammatory process of the pancreas, with variable involvement of other regional tissues or organs.

Abdominal pain is the major symptom in acute pancreatitis and is present in more than 95% of patients. Painless acute pancreatitis occurs in less than 5% of patients. Clinical clues to suspect painless acute pancreatitis are unexplained shock, fluid loss, systemic inflammatory response syndrome and patient deterioration without any explanation.⁵ The massive destruction of the pancreas in a short time and fulminant course may account for the lack of pain. In our patient there was severe necrosis of pancreas and that possibly accounted for the absence of pain.

The diagnosis may be confirmed with ERCP although it may not always be possible to demonstrate the fistulous tract. In these cases, CT or MRCP may be helpful. ERCP leads to diagnosis in 80% of cases and demonstrates the fistulous tract in 59% to 74% of the cases.

Treatment of pleural effusion is usually at first conservative. Pleural effusions which become symptomatic often require thoracentesis, tube thoracotomy, endotracheal intubation, ICU

admission, parenteral alimentation, and administration of octreotide. Endoscopic pancreatic stenting is effective therapeutic option associated with minimal morbidity and mortality, and combined with somatostatin analogues it can shorten the duration of hospital stay. Surgical intervention is the second line of treatment with an appreciable morbidity and mortality.^{4,6}

To conclude painless pancreatitis with pleural effusion should be considered as one of the possibilities in patients presenting with sudden onset dyspnea and massive pleural effusion even in the absence of pain abdomen.

References

1. Scott T, William M. Acute pancreatitis. In: Feldman M, Friedman LS, Brandt LJ, editors. *Sleisenger and Fordtran's Gastrointestinal and Liver Disease*. 9th ed. Philadelphia: Saunders Elsevier; 2010. p. 959- 82.
2. Clifton MT, Stephen KYC. Diagnosis and management of pancreaticopleural fistula. *Singapore Med J* 2013;54:190-4.
3. Light RW. Pleural effusion secondary to diseases of gastrointestinal tract. In: *Pleural diseases*. 5th ed. Philadelphia: Lippincott Williams & Wilkins publication;2007. p 252-64.
4. George WB, Pitchumoni CS. Pathophysiology of pulmonary complications of acute pancreatitis. *World J Gastroenterol* 2006;28:7087-96.
5. Supot P. Acute Pancreatitis: Evidence Base Management. *Thai J Gastroenterol* 2004;5:111- 21.
6. Norman OM. Pancreaticopleural Fistula: Revisited. *Diagnostic and Therapeutic Endoscopy*. Vol. 2012, Article ID 815476, 5 pages.doi:10.1155/2012/815476.