

Hydatid cyst of lung mimicking as mediastinal mass – A diagnostic dilemma

Rahul Sinha^{1,*}, Devendra Nema², K Venkatnarayan³, Shamsheer Dalal⁴

¹Head of Department Pediatrics, Military Hospital, Jodhpur, ²Head of Department Radiology, Military Hospital, Shillong, ³Professor & Head of Department of Pediatrics, Neonatology, Command Hospital, Pune, ⁴Professor, Armed Forces Medical College, Pune

***Corresponding Author:**

Email: drrahul_2000@yahoo.com

Abstract

Mediastinal masses in pediatric patients are very heterogeneous in origin and etiology. In the first decade of life, 70% of the mediastinal masses are benign, whereas malignant tumors are more frequent in the second decade of life. Among the mediastinal masses, lymph nodes are the most common involved structures and could be enlarged due to a lymphoma, leukemia, metastatic disease, or due to infectious diseases as sarcoidosis, tuberculosis and others. We report a mass located in the superior aspect of middle mediastinum mass in 14 year old boy who presented with features of dyspnea, flushing of face on lifting of arms, anorexia and chest pain. After detail history, clinical examination and imaging modalities it was diagnosed as hydatid cyst of lung which was closely associated with (in close relation with) middle mediastinum abutting trachea and arch of aorta on medial aspect and superior vena cava superiorly.

Keywords: Cyst; Hydatid; Lymphoma; Mediastinum

Introduction

Mediastinal masses can be caused by a variety of benign and malignant conditions. Mediastinal masses in children can be caused by the expansion of many organs that are contained in this thoracic compartment, such as the thymus gland, the thoracic portion of the esophagus and trachea, the great vessels, the heart, lymph nodes, fat and nerves. Non-vascular mediastinal masses can derive from all these structures and represent many conditions, such as congenital anomalies, benign and malignant neoplasms and infection like hydatid cyst^[1]. Lymphomas account for 13% of all pediatric cancers and are the most common cause of a mediastinal mass in children; almost half of the children with non-Hodgkin and two thirds of the children with Hodgkin lymphoma present with anterior or middle mediastinal masses^[2]. Though the differential diagnosis is extremely wide, diagnosis in an individual case can be aided by a thorough clinical examination and judicious use of imaging and ancillary investigations. The three important features which aid the clinical differential of a mediastinal tumour are 1) the location in the mediastinum, 2) the age of the patient, and 3) the symptoms at presentation.

Case Report

A 14 year old male adolescent presented to our OPD with a history of breathlessness on exertion with increasing severity of 20 days, chest pain of 20 days, Anorexia of 20 days and flushing of the face on combing of hair or lifting arms above head of 15 days duration. There was history of dry cough mostly in night. There was no history of weight loss, fever, night sweats, vomiting and diarrhea. There was no significant past history. The clinical evaluation revealed normal anthropometric measurements. The vital parameter revealed temperature 98 degree Fahrenheit with pulse 90/min, respiratory rate 20/min, blood pressure 110/70 mm Hg. There was flushing of face on lifting of arms and venous engorgement of neck veins. The SPO₂ on room air was 94%. There was pallor. There was no significant lymphadenopathy or any bony swelling. The systemic examination revealed decreased air entry on right mammary and the right scapular region with a dull percussion note over this region with a mild deviation of trachea on left side. The cardiovascular system revealed normal heart sound. The investigation revealed hemoglobin of 9gm%, TLC 12000(Polymorphs 85, Lymphocyte 12, Monocyte 3) and platelet of three lacs/cmm. The PBS was suggestive of microcytic hypochromic anemia with no malignant cells. C

reactive protein was negative and ESR 18 mm fall in 1st hour. The renal function test revealed urea of 22mg%/ creatinine 0.5mg% and electrolytes serum sodium 138 meq/l, potassium 5.0 meq/l, chloride 100 meq/l, total calcium 9 mg% (ionized 4.8), serum phosphorus 3.8mg%, ALP 150IU/L. The albumin was 3gm% and urine examination revealed few pus cells and specific gravity of 1006. Mountox test was normal. The sputum examination after saline nebulisation was negative for TB bacilli and malignant cells. The chest radiograph (PA view) revealed a homogenous density mass measuring 10.2 x 9.3 cms is seen arising from the superior aspect of middle mediastinum with well-defined lobulated margins, occupying right upper and mid zones with a broad base towards middle mediastinum(Fig. 1). Chest radiograph (right lateral view) shows the mass is in middle mediastinum, abutting the trachea and aortic arch (Fig. 2). With these features and location of the mass, the provisional diagnosis of lymphoma was made and urgent CT chest and abdomen were planned. The

ECG was essentially normal. The ultrasound of the abdomen was normal. CECT(Chest) revealed the mass is pulmonary in origin and seen in (close relation with) located with middle mediastinum, abutting the aortic arch and trachea/carina on medial aspect and superior vena cava on superior aspect. The fat planes between these structures are maintained. The lesion is thin walled with inner contents of Hounsfield unit 18-22 HU, depicting a fluid filled cystic mass lesion. The lesion is monolocular, with no internal septa, mural nodules or calcification(Fig. 3 and 4). No post contrast enhancement seen. With these findings, a diagnosis of hydatid cyst of right lung upper lobe was made. The hydatid serological test was negative. The Cardiothoracic surgeon was consulted and surgery was planned. The surgery involved enucleation of the cyst with capitonnage of the cavity. The patient was discharged on the 10th postoperative day on Albendazole. He was followed up for about six months and is doing well and attending school without any problems.

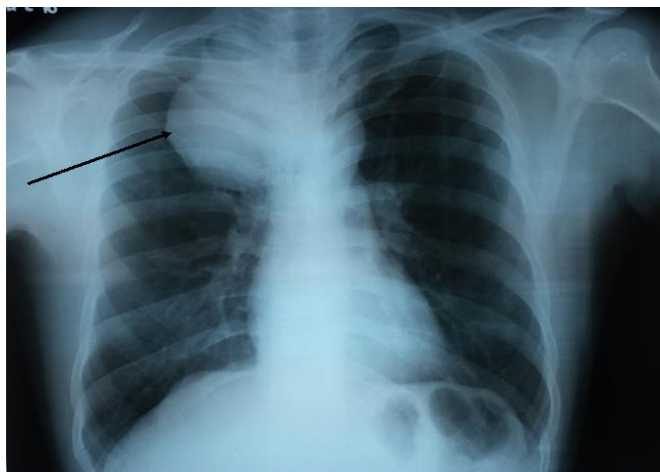


Fig. 1: Chest radiograph (PA view)- A homogenous density mass measuring 10.2 x 9.3 cms is seen arising from superior aspect of middle mediastinum with well-defined lobulated margins occupying right upper and mid zones. The mass has a broad base toward mediastinum, seem to be arising from it. There is no calcification or cystic areas seen

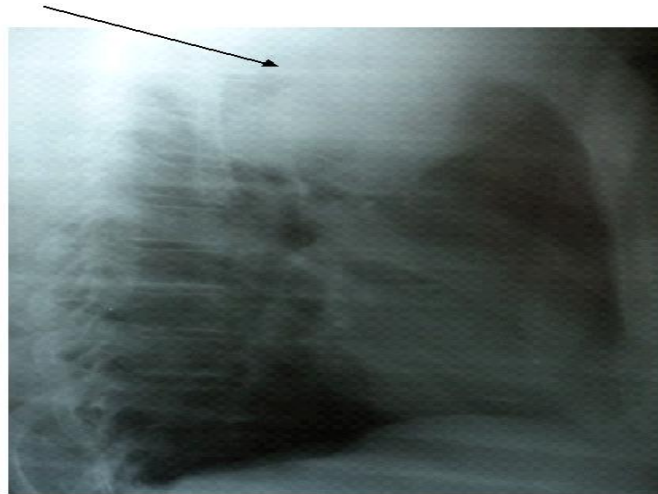


Fig. 2: Chest radiograph (right lateral view) shows the mass is located in superior aspect of middle mediastinum abutting the aortic arch. With these features and location of the mass it appears to be a lymphoma

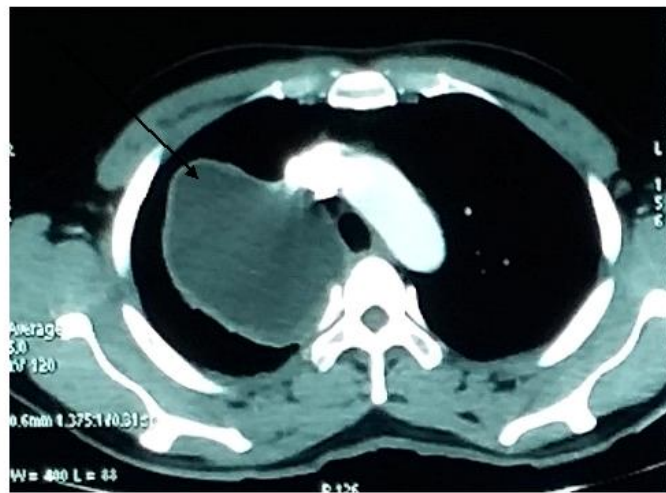

Fig. 3: CECT Chest axial view

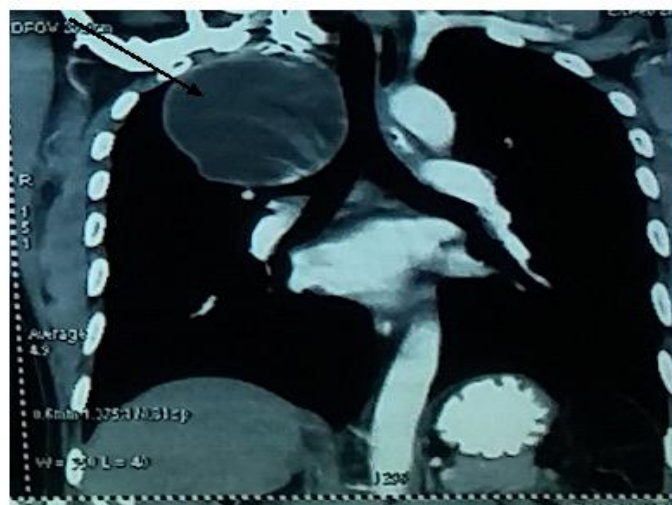


Fig. 4: CECT Chest axial view

Fig. 3 & 4: Contrast Enhanced CT Images show that the mass is pulmonary in origin, abutting the aortic arch, superior vena cava and trachea/carina with maintained Fat planes. The lesion is thin walled with inner contents of Hounsfield unit 18-22 HU, depicting a fluid filled cystic mass lesion. The lesion is monolocular, with no internal septae, mural nodules or calcification. No post contrast enhancement was seen. Based on the above findings diagnosis of hydatid cyst of right lung was made

Discussion

Children with mediastinal mass represent a potentially serious and life-threatening cardio-respiratory emergency that requires immediate and coordinated efforts by a multidisciplinary team. Most pediatric patients with mediastinal masses are symptomatic as compared to adults. Symptoms may include cough, dyspnea, dysphagia, orthopnea, wheezing, hoarseness, facial edema, headache and chest pain. Superior vena cava syndrome (SVCS) is found in 6% of pediatric cases of mediastinal malignancy, two-thirds of these being lymphoma and acute lymphoblastic leukemia (particularly T cell phenotype). Mediastinal masses in children can be caused by the expansion of many organs that are contained in this thoracic compartment, such as the thymus gland, the thoracic portion of the esophagus and trachea, the great vessels, the heart, lymph nodes, fat and nerves. Non-vascular mediastinal masses can derive from all these structures and represent many conditions, such as congenital anomalies, benign and malignant neoplasms and infection like hydatid cyst of lungs and mediastinum.

The pulmonary hydatid cystic disease caused by *Echinococcus granulosus* is still an important problem in endemic areas of Middle and Eastern Europe, including Turkey, South America, Australia, South Africa and India. The pulmonary hydatid cystic disease is frequently asymptomatic in children^[3]. Common presenting symptoms of giant pulmonary hydatid cyst are related to compression of tissue and they present as dry cough, chest pain, dyspnea, and ruptured cyst can cause productive cough and very rarely anaphylaxis. In our patient, dry cough was the single symptom present at admission. Biochemical and physical examination findings have limited value in the diagnosis of pulmonary hydatid disease^[4]. Serological tests have limited diagnostic value and enzyme-linked immunoabsorbent assay was positive only in less than 50% cases of pulmonary hydatid cyst. The chest X-ray and thoracic CT are generally sufficient for diagnosis of hydatid cyst. Unruptured pulmonary hydatid cyst shows one or more homogenous round or oval masses with smooth borders surrounded by normal

lung tissue on chest radiograph^[5]. Water lily sign, crescent sign, Cumbo's sign, serpent sign, and Monod's sign are the other pathognomic radiologic signs for ruptured hydatid cyst which can sometime pose diagnostic challenge^[6]. A CT scan can demonstrate the cystic nature of lung lesion and a thin enhancing rim if the cyst is intact. A definite diagnosis of hydatid cyst is based on surgery and pathological confirmation. Surgery is the first treatment modality of choice for hydatid cyst disease and medical treatment can be used during the postoperative period in order to prevent recurrence. In our case child presented with features of dyspnea, superior vena cava syndrome with lung mass associated closely with middle mediastinum which was later confirmed with CECT chest and intraoperative finding as hydatid cyst of the lung. The masses which are closely associated with mediastinum always pose difficulty in the diagnosis of the more sinister condition like lymphoma. This case report highlights the diagnostic dilemma while dealing with pulmonary mass closely associated with mediastinum in children.

Conflicts of interests: None declared

Acknowledgements: Nil

References

1. Lee EY. Evaluation of non-vascular mediastinal masses in infants and children: an evidence-based practical approach. *Pediatr Radiol.* 2009;39(Suppl 2):S184-S190.
2. Mc Carville MB. Malignant pulmonary and mediastinal tumors in children: differential diagnoses. *Cancer Imaging.* 2010, 10 (1A): S35-S41. 10.1102/1470-7330.2010.9015.
3. Ghallab NH, Alsbahi AA. Giant viable hydatid cyst of the lung: A case report. *J Med Case Rep.* 2008;2:359.
4. Kayhan S, Akgunes A. Histopathologically diagnosed pulmonary complicated hydatid cyst cases. *Turkiye Parazitoloj Derg.* 2011;35:189-93.
5. Beggs I. The radiology of hydatid disease. *AJR Am J Roentgenol.* 1985;145:639-48.
6. Akhtar J, Khan NA, Baneen U, Shameem M, Ahmed Z, Bhargava R. Giant pulmonary hydatid cyst mimicking elevated diaphragm: A diagnostic dilemma. *Ann Afr Med.* 2012;11:122-3.