



Case Report

COVID-19 associated mucormycosis with frontal bone osteomyelitis

Neha Gupta^{1,*}, Rajeev Gupta², Rajiv Goel³, Dheeraj Gautam⁴, V P Singh⁵

¹Founder, NG Swastha, Infectious Diseases Clinic, Gurugram, Haryana, India

²Dept. of Radiology, Medanta- The Medicity, Gurugram, Haryana, India

³Dept. of Neurology, The Medicity, Gurugram, Medanta- The Medicity, Gurugram, Haryana, India

⁴Dept. of Histopathology, The Medicity, Gurugram, Medanta- The Medicity, Gurugram, Haryana, India

⁵Dept. of Neurosurgery, The Medicity, Gurugram, Medanta- The Medicity, Gurugram, Haryana, India



ARTICLE INFO

Article history:

Received 07-04-2022

Accepted 13-06-2022

Available online 09-07-2022

Keywords:

Covid-19

Mucormycosis

Corticosteroids

Fungal infection

Amphotericin B

ABSTRACT

During the coronavirus disease 2019 (COVID-19) pandemic, increasing cases of COVID-19 associated mucormycosis (CAM) have been reported. This may be attributed directly to the COVID-19 infection or the associated unrecognised uncontrolled hyperglycaemia compounded by the use of COVID-19 treatment strategies such as steroids and IL-6 inhibitors. As mucormycosis is one of the most rapidly progressing fungal infection, an early diagnosis and early appropriate management are of prime importance in reducing mortality. Rhino-orbital-cerebral and pulmonary mucormycosis have been the most common presentations of CAM. Osteomyelitis in mucormycosis is very rare, although a few cases of maxillary bone involvement have been reported with CAM. We report a very rare and challenging case of extensive frontal bone osteomyelitis in a patient with CAM with frontal sinusitis and without orbital or maxillary bone involvement.

This is an Open Access (OA) journal, and articles are distributed under the terms of the [Creative Commons Attribution-NonCommercial-ShareAlike 4.0 License](https://creativecommons.org/licenses/by-nc-sa/4.0/), which allows others to remix, tweak, and build upon the work non-commercially, as long as appropriate credit is given and the new creations are licensed under the identical terms.

For reprints contact: reprint@ipinnovative.com

1. Introduction

Globally, there has been a rapid spread of Coronavirus Disease 2019 (COVID-19). A high prevalence of secondary infections (10-30%) is reported in severely ill, hospitalised COVID-19 patients. The prevalence of fungal infection is 10-times high in such patients.¹ In patients with COVID-19, both *Aspergillus* and *Candida* have been reported to be the main fungal pathogens for co-infection. However, an increasing number of cases of CAM have also been reported worldwide, particularly in India. CAM is an emerging angioinvasive disease caused by mould fungi of the genus *Rhizopus*, *Apophysomyces elegans*, *Lictheimia*, *Mucor*, *Rhizomucor*, *Cunninghamella*, and *Absidia* of order- *Mucorales*.²

In COVID-19 patients, the primary conditions facilitating *Mucorales* spores to germinate include: low oxygen, high glucose (diabetes, new-onset hyperglycaemia, and steroid-induced hyperglycaemia), acidic medium (metabolic acidosis, diabetic ketoacidosis [DKA]), high iron levels (increased ferritins), decreased phagocytic activity of white blood cells due to immunosuppression and prolonged hospitalisation.²

In a recent systemic review, Singh et al., reported that, out of 101 total cases of CAM in people with COVID-19 (reported globally), 82 cases were from India. Researchers also reported a high mortality rate (30.7%) in COVID-19 patients with mucormycosis.² In addition to the high mortality rate, an extraordinary phenomenon with mucormycosis is rapid dissemination. Evidence suggests that a delay of a week can double the 30-day mortality from 35% to 66%.¹ Therefore, a high suspicion of this disease

* Corresponding author.

E-mail address: nehathedoc@gmail.com (N. Gupta).

should be considered in immunocompromised patients.³

Another recent multicentre retrospective study across India evaluated 287 CAM patients during September–December 2020. CAM prevalence was 0.27% among hospitalised COVID-19 patients and 1.6% of patients managed in ICUs. During the study period, there was a 2.1-fold rise in mucormycosis vs. September–December 2019. Most common presentation of CAM included 86.1% Naso-orbital, 23.5% brain, 8.6% pulmonary, and 2.1% disseminated. The multivariate analysis concluded hypoxemia ($p=0.02$) and inappropriate steroid 63.3% ($p=0.0001$) are the most common risk factors associated with CAM. CAM case-fatality rate at 12 weeks was 45.7%.⁴

Based on its clinical presentation and anatomic site, invasive mucormycosis can be classified into 6 major clinical forms: (1) rhinocerebral, (2) pulmonary, (3) cutaneous, (4) gastrointestinal, (5) disseminated, and (6) uncommon rare forms, such as endocarditis, osteomyelitis, peritonitis, and renal infection.⁵

The present report is a rare and challenging case of extensive frontal bone osteomyelitis in a patient with CAM with frontal sinusitis and without orbital or maxillary bone involvement.

2. Case Report

A 62-year-old gentleman with hypertension, presented with a history of high-grade fever, body ache and dry cough for 6 days. Nasopharyngeal swab sent for RT-PCR tested positive for Covid-19. On 26th April 2021, investigations suggested a case of moderate COVID-19 with Oxygen saturation levels (SpO₂) <94%. So, he was hospitalised and administered methylprednisolone (for 20 days). After 20 days, he was discharged and was advised to continue the steroids at home. During his hospital stay, he developed steroid induced hyperglycaemia with glucose ranging between 200–300 mg/dL.

On 25th May 2021, a month after the onset of COVID-19 illness, the patient complained of headache and left eye swelling. He was taking steroids at the time. Magnetic resonance imaging (MRI) of the brain suggested left frontal sinusitis with extra-calvarial soft tissue and bone involvement. Functional endoscopic sinus surgery (FESS) was performed somewhere else. Histopathological examination revealed partially septate broad- ribbon shaped hyphae indicating mucormycosis.

For managing mucormycosis, a lipid formulation of amphotericin B was initiated. Due to severe infusion related toxicity, the patient was not able to tolerate the treatment. Subsequently, posaconazole was initiated. At this time, no surgical debridement was performed.

While on posaconazole, the patient continued to have symptoms and the left eye swelling persisted. He also complained of the occasional shooting of pain in the head,

mild left eye ptosis, and facial swelling of the left side. Repeat contrast MRI brain scans on 12th and 27th June 2021 showed an increase in dural enhancement in the left basi-frontal bone with peripheral enhancement. In addition to this, an increase in enhancing soft tissue component, extra calvaria bone involvement, and mucosal enhancing areas in the frontal sinuses were observed (Figure 1).

The patient was then referred for an infectious diseases opinion due to the progression of the disease. There the patient was advised hospitalisation and immediate treatment with liposomal amphotericin B (L-AmB) therapy and source control. On admission, 1st July 2021, laboratory investigations were performed, and the results were: haemoglobin: 10.4 gm/dL, platelets: 247 (10³/uL), serum creatinine: 0.7 mg/dL, sodium: 137 mmol/L, potassium: 3.6 mmol/L, magnesium: 1.9 mg/dL and blood urea: 14 mg/dL, with stable vital signs. The patient was afebrile, conscious, and oriented. Treatment with intravenous liposomal amphotericin B 10 mg/kg/day was initiated and blood glucose levels were controlled under the guidance of an endocrinologist. A neurosurgeon, who was immediately consulted, advised a contrast computed tomography (CT) scan of the paranasal sinuses (PNS) and orbit (axial and sagittal sections). The scanning showed frontal sinusitis with contiguous erosion of the anterior and posterior walls of the frontal sinus. Besides, frontal bone necrosis with extraosseous soft tissue swelling involving the overlying scalp extending inferiorly (in the pre-septal region of the left orbit) and posteriorly (involving the left temporalis muscle) was observed (Figure 1). Post contrast images showed a mild enhancement in the soft tissue. No loculated collection was seen. The findings were parallel to the provided history of left frontal fungal sinusitis with an erosion of the frontal bone and extracalvarial soft tissue.

The diffuse pachymeningeal thickening with enhancement along the left frontal convexity measuring approximately 5 mm in thickness suggested pachymeningeal spread of the disease. Before the surgery, close consultation with the neurosurgeon, ear nose, and throat (ENT) specialist, ophthalmologist, and the cardiologist was done. On 5th July 2021, a team of neurosurgeons performed a bifrontal craniotomy with resection of infected calvarial bone with exenteration and exteriorization of the frontal sinus. Local instillation of amphotericin B was avoided in view of the possibility of chemical meningitis.

Post-operatively, the patient was followed by ear, nose, and throat (ENT) and neurosurgery teams. The bilateral nasal pack was removed on 7th July 21. On day 10 of liposomal amphotericin B therapy, the patient developed fever again. Peripherally inserted central catheter (PICC) line related infection was suspected. PICC line was removed and the patient was initiated on polymyxin B combination therapy for seven days.

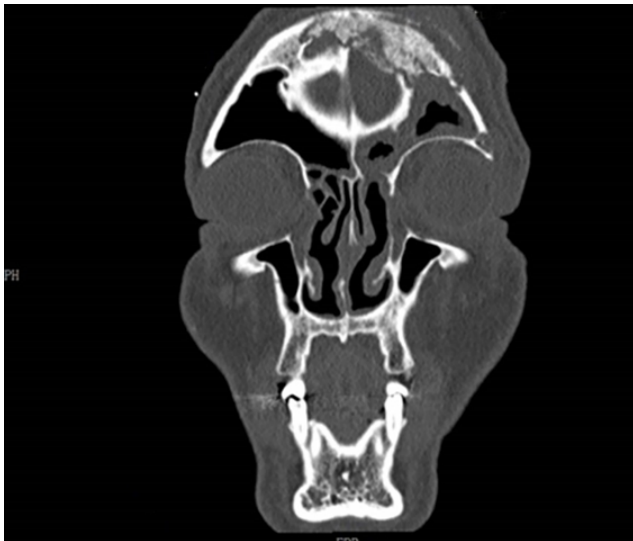

Fig. 1: CT scanhead/PNS showing frontal sinusitis with necrotic frontal bone with underlying pachymeningitis

Repeat MRI of the brain showed improvement with no increase in necrotic bone (Figure 2). However, a localised collection was observed. The collection was drained and microbiological examination revealed negative KOH, gram stain, aerobic & fungal cultures. Histopathological evaluation of the collection was also negative.

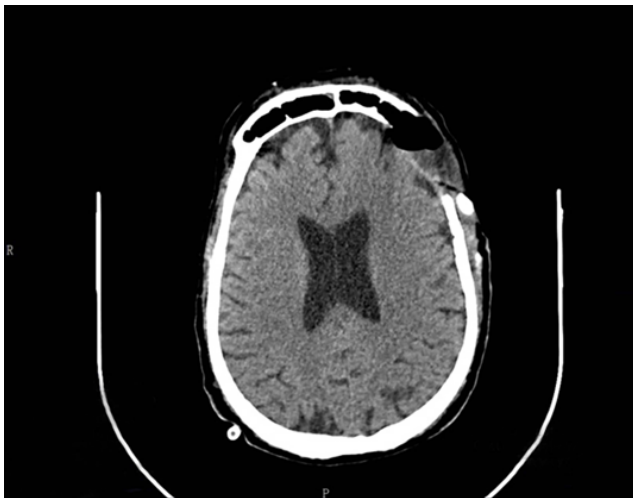


Fig. 2: Repeat MRI of the brain showing no increase in necrotic bone, but a localised collection

On 19th July 2021, the patient appeared stable with no oxygen support, haemoglobin: 8.1 gm/dL, WBC: 14.22, platelet: 400 (10^3 /uL), Mg: 1.99 mg/dL, creatinine: 0.7 mg/dL, sodium: 137 mmol/L and CRP: 33.7 (slowly improving).

L-AmB was administered for a period of six weeks followed by a switch to oral antifungal therapy

(isavuconazole) for another 6 weeks. The antifungal therapy was discontinued after demonstrating clinical, microbiological cure, and radiological stability.

The patient has been doing well on follow-up in March 2022. Written informed consent was obtained from the patient for publication of this case report and accompanying images.

3. Discussion

During the COVID-19 pandemic, an exponential increase in CAM has been observed. The impaired immune system of the COVID-19 patient is one of the major causes of rising mucormycosis cases in these individuals.² In addition, hyperglycemia during COVID-19 also increases the expression of endothelial receptor GRP78 and increases free iron and polymorphonuclear (PMN) dysfunction which promotes angioinvasion.⁶

CAM has a few rare manifestations and complications of mucormycosis. Osteomyelitis in mucormycosis is rare and has been reported usually following trauma or in immunosuppressed patients with diabetes or transplantation. Osteomyelitis of long bones is observed following trauma or surgery, while a wide variety of bones are involved by hematogenous dissemination.⁷ Maxillary bone osteomyelitis has been reported in patients with CAM.⁸ However, osteomyelitis of the skull is a rare clinical presentation. A typical fluctuant swelling on the forehead is seen in patients with frontal osteomyelitis. Trauma and spread from adjacent sites (especially frontal sinus) are commonly seen in most cases of skull osteomyelitis. Hematogenous origin of infection is rarely reported.⁹

In the present case, there was a fungal invasion in the paranasal sinuses of the susceptible host. This led to consistent symptoms, including headache and left eye swelling, followed by sinusitis, soft tissue swelling, and frontal bone osteomyelitis.

From the sinuses, the infection usually spreads to the orbit, resulting in the loss of extraocular muscle function and proptosis with marked chemosis. These sequelae of events can quickly lead to cavernous sinus thrombosis, carotid artery, or jugular vein thrombosis and death.⁷ The patient in the present study also had a rapid spread of infection involving the frontal sinus and frontal bone osteomyelitis and necrosis. Despite the early treatment initiation with posaconazole (initiated elsewhere), the patient continued to have symptoms, and the left eye swelling persisted. The disease further progressed and the patient had mild left eye ptosis, facial swelling of the left side, and dural enhancement in the left basi-frontal bone.

Arora DR et al. in a recent case report also emphasized the development of frontal bone osteomyelitis (Pott's puffy tumour) as a possible rare complication of mucormycosis after COVID-19 infection. In this case, the patient had a chief complaint of swelling of the forehead for 4

weeks. The patient had a history of moderate COVID-19 which was treated with supplemental oxygen, steroids, and remdesivir. Periorbital swelling was developed in the patient during the treatment. The swelling was diagnosed as right sinonasal mucormycosis. After 1-week, the patient developed swelling in the frontal region. Contrast-enhanced magnetic resonance imaging of the orbits and paranasal sinuses revealed that the swelling was due to osteomyelitis with osteonecrosis of the frontal bone associated with adjacent patchy meningitis and cerebritis, presumably Pott's puffy tumor. The patient underwent the endoscopic procedure with bicoronal incision frontal craniectomy with exteriorization of the frontal sinus. Postoperatively, the patient recovered without any other problems. Early diagnosis and prompt treatment are the keys to the recovery of the patient. The authors reported that they did not find any similar case in the setting of the COVID-19 pandemic.¹⁰

Four factors are critical for eradicating mucormycosis: rapidity of diagnosis, reversal of the underlying predisposing factors (if possible), appropriate surgical debridement of infected tissue, and appropriate antifungal therapy.¹¹

Clinical features and pathological findings help in the diagnosis of mucormycosis. Imaging plays an important role in defining the extent of involvement. Opacification of sinuses in conjunction with heterogeneous patchy effacement of bony walls of the sinuses can be seen radiographically. CT with contrast or MRI face shows the erosion or destruction of bone and guides about the extent of the disease.¹²

In the present case, immediate treatment with liposomal amphotericin B (LAmB) therapy and source control was initiated. For source control, a bifrontal craniotomy with resection of infected calvarial bone with exenteration of frontal sinus and exteriorization of frontal sinus was performed.

Early diagnosis and correction of the underlying cause are the primary steps in the management of mucormycosis. However, this cannot be always achieved in COVID-19 patients who are dependent on high-dose steroid therapy.³ In this case report, a fast progression of fungal infection involving the sinus, soft tissue with bone involvement, further leading to eye ptosis (due to oedema without significant extra- or intra-ocular muscle involvement) and peripheral enhancement was observed. Hence, prompt surgical intervention along with pharmacological treatment is the key to controlling the extent and severity of the disease. Liposomal amphotericin B, a fungicidal agent, is the mainstay of treatment for mucormycosis.

Mucormycosis, when diagnosed early, can be treated by a combination of surgical debridement of the infected area and administration of liposomal amphotericin B.¹¹

4. Conclusions

In COVID-19 patients, multiple factors facilitate the development of CAM, which adds to morbidity and

mortality. Thus, close monitoring of high-risk patients can help in early diagnosis and timely initiation of treatment. For a better prognosis, rational use of corticosteroids and maintenance of glycaemia plays an important role in prevention. Mucormycosis osteomyelitis needs to be actively managed by a team that includes members from almost all departments in the hospital. Inputs are needed from infectious diseases, radiology, microbiology, histopathology, medicine, endocrine, and various surgical specialties to manage these invasive fungal infections (IFI) effectively.

5. Acknowledgments

None.

6. Conflict of Interest

None.

7. Source of Funding

None.

References

1. Singh D, Kaur H, Kajal NC. Covid-19 and Rhino-Orbital Mucormycosis - A Case Report. *Int J Pul Res Sci.* 2021;5(1):555654. doi:10.19080/IJOPRS.2021.05.555654.
2. Singh AK, Singh R, Joshi SR, Misra A. Mucormycosis in COVID-19: A systematic review of cases reported worldwide and in India. *Diabetes Metab Syndr.* 2021;15(4):102146. doi:10.1016/j.dsx.2021.05.019.
3. Maini A, Tomar G, Khanna D, Kini Y, Mehta H, Bhagyasree V, et al. Sino-orbital mucormycosis in a COVID-19 patient: A case report. *Int J Surg Case Rep.* 2021;82:105957. doi:10.1016/j.ijscr.2021.105957.
4. Patel A, Agarwal R, Rudramurthy SM, Shevkani M, Xess I, Sharma R, et al. Multicenter Epidemiologic Study of Coronavirus Disease-Associated Mucormycosis. *India Emerg Infect Dis.* 2021;27(9):2349–59.
5. Petrikos G, Skiada A, Lortholary O, Roilides E, Walsh TJ, Kontoyiannis DP, et al. Epidemiology and Clinical Manifestations of Mucormycosis. *Clin Infect Dis.* 2012;54(1):23–34.
6. Solanki B, Chouhan M, Shakrawal N. Mucor Alert: Triad of COVID-19, Corticosteroids Therapy and Uncontrolled Glycemic Index. *Indian J Otolaryngol Head Neck Surg.* 2021;p. 1–3. doi:10.1007/s12070-021-02801-8.
7. Taj-Aldeen SJ, Gamaletsou MN, Rammaert B, Sipsas NV, Zeller V, Roilides E, et al. Bone and joint infections caused by mucormycetes: A challenging osteoarticular mycosis of the twenty-first century. *Med Mycol.* 2017;55(7):691–704.
8. Ahmed WS, Elsherbini AM, Elsherbiny NM, El-Sherbiny M, Ramzy NI, Arafa AF, et al. Maxillary Mucormycosis Osteomyelitis in Post COVID-19 Patients: A Series of Fourteen Cases. *Diagnostics (Basel).* 2021;11(11):2050. doi:10.3390/diagnostics11112050.
9. Osei-Yeboah C, Neequaye J, Bulley H, Darkwa A. Osteomyelitis of the frontal bone. *Ghana Med J.* 2007;41(2):88–90.
10. Arora RD, Thangaraju P. Pott's puffy tumor in coronavirus disease-2019 associated mucormycosis. *Rev Soc Bras Med Trop.* 2022;55:e06692021. doi:10.1590/0037-8682-0669-2021.
11. Garlapati K, Chavva S, Vaddeswarupu RM, Surampudi J. Fulminant Mucormycosis Involving Paranasal Sinuses: A Rare Case Report.

Case Rep Dent. 2014;p. 465919. doi:10.1155/2014/465919.


12. Afroze SN, Korlepara R, Rao GV, Madala J. Mucormycosis in a Diabetic Patient: A Case Report with an Insight into Its Pathophysiology. *Contemp Clin Dent.* 2017;8(4):662–6.

Rajiv Goel, Radiologist

Dheeraj Gautam, Histopathologist

V P Singh, Neurosurgeons

Author biography

Neha Gupta, Senior Infectious Diseases Physician
 <https://orcid.org/0000-0001-5135-8916>

Rajeev Gupta, Director

Cite this article: Gupta N, Gupta R, Goel R, Gautam D, Singh VP. COVID-19 associated mucormycosis with frontal bone osteomyelitis. *IP Indian J Immunol Respir Med* 2022;7(2):85-89.