



Case Report

Burkholderia cepacia: An unusual cause of pneumonia

Prasanna Kumar T¹, Manjunath H K¹, Arjun A S^{1,*}

¹MS Ramaiah Medical College, Bengaluru, Karnataka, India



ARTICLE INFO

Article history:

Received 17-09-2021

Accepted 22-12-2021

Available online 31-12-2021

Keywords:

Burkholderia cepacia

Pneumonia

Cepacia Syndrome

ABSTRACT

Introduction : Burkholderia Cepacia is a gram negative organism, an uncommon cause of pneumonia. When isolated, it usually represents colonisation. In the presence of immunocompromising conditions, it can cause disease, ranging from mild illness to the highly fatal Cepacia syndrome. The organism is intrinsically resistant to many antibiotics.

Case Presentation: We report a 57 years old male farmer, who has diabetes mellitus and bronchial asthma, who presented with a acute history of high grade fever, pain abdomen and cough. He was diagnosed with a ruptured liver abscess, with the infection spreading to the right lower lobe. Laparotomy was performed. Pus culture grew Pseudomonas aeruginosa. He improved upon antibiotic therapy, only to return after one month with severe cough, chest X-ray revealing a lung abscess in the right lower lobe. Bronchoalveolar lavage culture grew Burkholderia cepacia, and sensitive antibiotics were initiated, however the patient succumbed to the illness. The implicated source of the organism was the nebulisation solution which he was using regularly.

Conclusions: Emphasis should be laid on the need for improved aseptic practices while using medical solutions at either hospital or home setting. An index of suspicion may guide optimal antibiotic prescription practices in susceptible individuals.

This is an Open Access (OA) journal, and articles are distributed under the terms of the [Creative Commons Attribution-NonCommercial-ShareAlike 4.0 License](https://creativecommons.org/licenses/by-nc-sa/4.0/), which allows others to remix, tweak, and build upon the work non-commercially, as long as appropriate credit is given and the new creations are licensed under the identical terms.

For reprints contact: reprint@ipinnovative.com

1. Introduction

Burkholderia cepacia (B. cepacia) is a gram-negative organism and a less frequent cause of pneumonia. They carry intrinsic resistance to many antibiotics which makes them potentially lethal. They have been linked to poor outcomes in patients with structural lung disease [eg; cystic fibrosis] and in immunosuppressed individuals. They also cause the potentially fatal Cepacia syndrome, a combination of necrotizing pneumonia, rapid respiratory decline, and bacteremia. It primarily being a colonizer runs an indolent course in the majority, the immunosuppressed are susceptible to a wide range of manifestations.¹⁻⁵ Knowledge of the existence of this entity with intrinsic

resistance is vital to ensure optimal care. We hereby report a case of pneumonia caused by B. cepacia.

2. Case History

A 57-year-old male farmer, a known asthmatic, diabetic and hypertensive, presented with complaints of fever with chills and rigors for 15 days, cough for seven days and pain abdomen for five days. On physical examination he was hyperventilating, tachycardic and guarding the right upper abdomen. He was febrile, had a heart rate of 116/min, SpO₂ of 96% in room air, blood pressure 130/90 mmHg and respiratory rate of 30 cycles/min. On systemic examination, he had severe tenderness in the right hypochondrium. Bowel sounds were normal. Examination of respiratory system and other systems were within normal limits.

* Corresponding author.

E-mail address: drarjun2321@gmail.com (Arjun A S).

He was admitted to the medical ICU (MICU). Blood workup revealed neutrophilic leukocytosis (17740 cells/mm³) with thrombocytosis (541000/mm³), elevated ALP (176U/L) and GGT (119U/L). Renal function tests and pancreatic enzymes were normal. Viral serology was non-reactive for HIV, HBsAg, and HCV-Ab.

He was initiated on broad spectrum antibiotics after sending blood and urine for cultures which had revealed no growth subsequently.

He was subjected to contrast CT of the abdomen which revealed, ruptured intrahepatic abscess (Figure 1 A,B), hence he was subjected to laparotomy which revealed pus in the subdiaphragmatic area and the left hepatic lobe. The pus was drained and peritoneal lavage was performed. He tolerated the surgery well and was managed in the MICU.

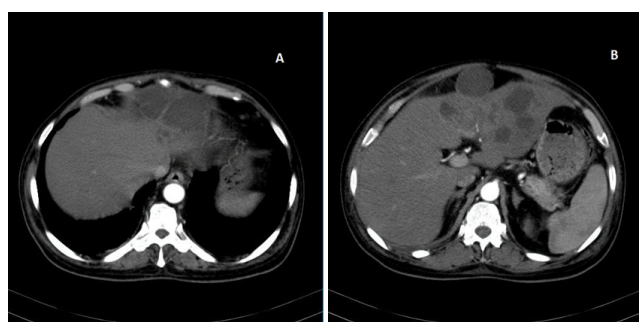


Fig. 1: A,B- Contrast CT of the abdomen revealing a ruptured intrahepatic abscess

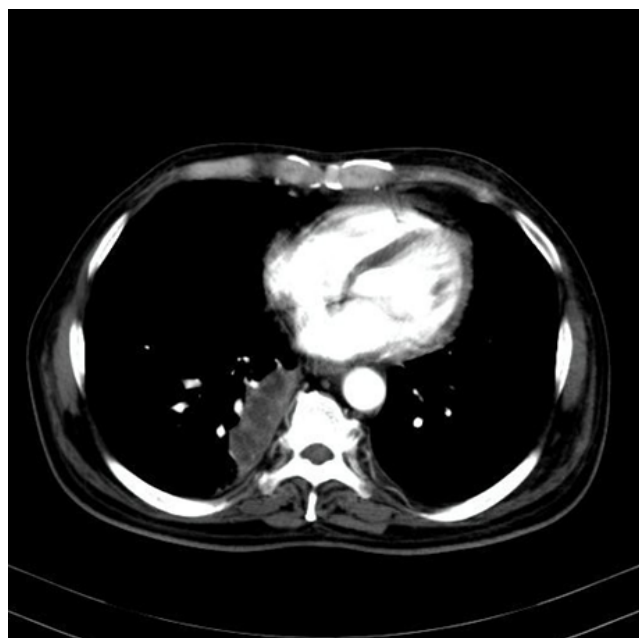

Fig. 2: The lung cuts of the Contrast CT abdomen shows a heterogeneously enhancing mass like lesion in the right lower lobe

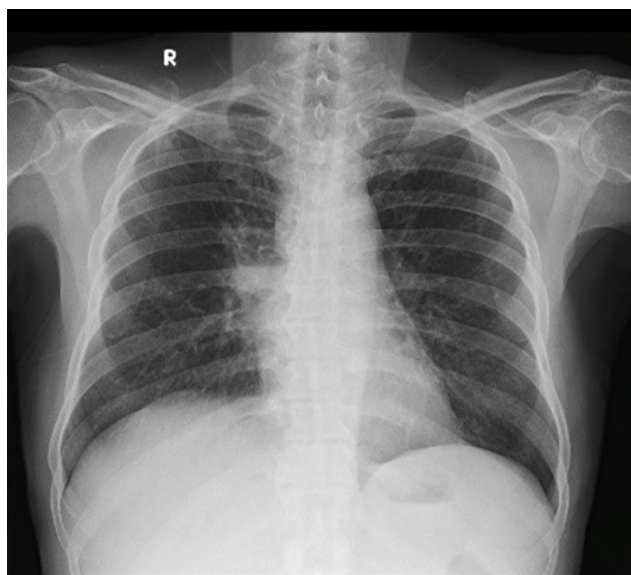


Fig. 3: Frontal Chest Radiograph reveals a cystic lesion with air fluid level in the right midzone with the medial border abutting the mediastinal contour

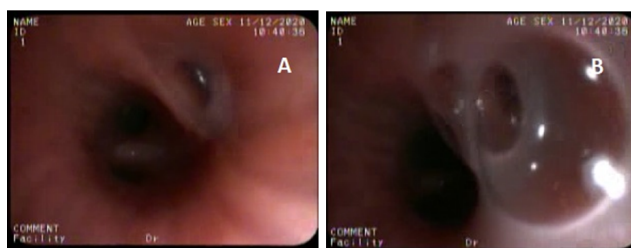


Fig. 4: A,B- Diagnostic fiberoptic bronchoscopy images show viscid secretions emerging from the right lower lobe, primarily the superior segment

The lung slices of the CT also revealed a well-defined heterogeneously enhancing mass in the medial segment of the right lower lobe measuring 60 x 24 mm for which a pulmonology opinion was sought (Figure 2 Heterogeneously enhancing mass like lesion in the right lower lobe).

He was advised to continue antibiotics. However, patient deteriorated and became hypoxic (SpO₂ 86% on room air) and was initiated on oxygen therapy. Respiratory examination revealed polyphonic rhonchi bilaterally, he was treated accordingly.

Bacterial culture of pus from the liver abscess grew *Pseudomonas aeruginosa* which was pan resistant, with intermediate sensitivity to Doripenem.

He was initiated on a 5th generation Cephalosporin, Ceftaroline 600mg and Metronidazole. Following this he improved gradually and was moved to ward. He was subsequently discharged in a stable state on an extended course of oral Metronidazole and nebulization. He had

received a total course of antibiotics of 21 days.

One month later he presented to Pulmonology OPD with persistent cough. Chest X-ray revealed a cystic lesion with air fluid level in the right midzone with the medial border abutting the mediastinal contour (Figure 3). Hence he was subjected to diagnostic bronchoscopy.

Bronchoscopy revealed viscid secretions emerging from the right lower lobe, primarily the superior segment (Figure 4 A,B). Bronchoalveolar lavage was performed and the fluid was sent for culture and analysis.

BAL culture revealed significant growth (15000 CFU/ml) of *Burkholderia cepacia* which was pan resistant and sensitive only to Meropenem, Minocycline and Ceftazidime.

He was promptly initiated on Inj Ceftazidime + Avibactam and oral Minocycline. He sought discharge and was continued on home-based treatment.

On telephonic follow-up a week later, patient claimed adherence to medication and improvement in symptoms. Unfortunately, very soon after, he developed severe breathlessness and was found unresponsive at his home and expired subsequently at a local hospital. Written and informed consent was obtained from patient's relatives for the publication of this case report.

3. Discussion

Burkholderia cepacia is an aerobic gram-negative, non-fermentative bacillus formerly classified as *Pseudomonas*. Unlike *Pseudomonas aeruginosa*, *B. cepacia* is an organism of low virulence with a limited ability to cause infection in healthy hosts. It has high transmissibility and low virulence and is a frequent colonizer of fluids used in the hospital (eg, irrigation solutions, intravenous fluids, distilled water, nebulizers, dialysis machines, contaminated disinfectants, solutions, and intravenous fluids, catheters, blood gas analyzers, thermometers, ventilator temperature sensors, and intra-aortic balloon pumps).^{1,6}

Further, its antifungal and degradative properties have resulted in its employment as a pesticide in agriculture, thereby making farmers potential hosts for colonization/infection.⁷

B. cepacia is known to exhibit multiple drug resistance and has thus emerged as an important cause of morbidity and mortality in hospitalized patients, particularly among the immunosuppressed.⁸ A wide range of presentations have been reported, ranging from superficial to deep-seated and disseminated infections, such as pneumonia, meningitis, peritonitis (in patients undergoing peritoneal dialysis and bronchiectasis).^{9,10}

However, *B. cepacia* is an extremely rare cause of nosocomial pneumonia. *B. cepacia* cultured from respiratory secretions in hospitalized patients especially those on ventilator support, generally represents colonization rather than infection. Our patient is a farmer, a

known asthmatic who had been using nebulizations during his first hospital stay as well as at home. These risk factors are likely causative factors towards his susceptibility to *B. cepacia*.

His second hospitalization was for the purpose of diagnostic bronchoscopy limiting the possibility of hospital-based contamination. While questions may arise on the possibility of contamination from the fluid used for the purpose of lavage, we reiterate that the fluid used was obtained from sterile, packed plastic containers opened freshly for the purpose of lavage.

BAL culture established the causative organism in this patient, thereby underlying the utility of bronchoscopy, although this patient succumbed to the illness.

Emphasis should be laid on the need for improved aseptic practices while using medical solutions at either hospital or home setting. An index of suspicion may guide optimal antibiotic prescription practices in susceptible individuals.

4. Acknowledgements

None.

5. Conflict of Interest

The author declares no potential conflicts of interest with respect to research, authorship, and/or publication of this article.

6. Source of Funding

None.

References

1. Mahmood SF. *Burkholderia cepacia*: Background, Pathophysiology, Epidemiology. Medscape. Available from URL:- <https://emedicine.medscape.com/article/237122-overview>. Last accessed 2021 on September 1;.
2. Weidmann A, Webb AK, Dodd ME, Jones AM. Successful treatment of cepacia syndrome with combination nebulised and intravenous antibiotic therapy. *J Cystic Fibrosis*. 2008;7(5):409–11.
3. Shafiq I, Carroll MP, Nightingale JA, Daniels T. Cepacia syndrome in a cystic fibrosis patient colonised with *Burkholderia multivorans*. *BMJ Case Rep*. 2011;p. bcr0820103296. doi:10.1136/bcr.08.2010.3296.
4. Gilchrist FJ, Webb AK, Bright-Thomas RJ, Jones AM. Successful treatment of cepacia syndrome with a combination of intravenous cyclosporin, antibiotics and oral corticosteroids. *J Cystic Fibrosis*. 2012;11(5):458–60.
5. Blackburn L, Brownlee K, Conway S, Denton M. Cepacia syndrome with *Burkholderia multivorans*, 9 years after initial colonization. *J Cystic Fibrosis*. 2004;3(2):133–4.
6. Conly JM, Klass L, Larson L, Kennedy J, Low DE, Harding GK, et al. *Pseudomonas cepacia* colonization and infection in intensive care units. *CMAJ*. 1986;134(4):363–6.
7. Govan JR, Hughes JE, Vandamme P. *Burkholderia cepacia*: medical, taxonomic and ecological issues. *J Med Microbiol*. 1996;45(6):395–407.
8. Hancock R. Resistance Mechanisms in *Pseudomonas aeruginosa* and Other Nonfermentative Gram-Negative Bacteria. *Clin Infect Dis*. 1998;27(Supplement_1):S93–99.

9. Mukhopadhyay C, Bhargava A, Ayyagari A. Two Novel Clinical Presentations of *Burkholderia cepacia* Infection. *J Clin Microbiol.* 2004;42(8):3904–5.
10. Ledson MJ, Gallagher MJ, Walshaw MJ. Chronic *Burkholderia cepacia* bronchiectasis in a non-cystic fibrosis individual. *Thorax.* 1998;53(5):430–2.

Manjunath H K, Senior Resident

Arjun A S, Junior Resident

Author biography

Prasanna Kumar T, Associate Professor

Cite this article: Kumar T P, Manjunath H K, Arjun A S. *Burkholderia cepacia*: An unusual cause of pneumonia. *IP Indian J Immunol Respir Med* 2021;6(4):249-252.