



Original Research Article

Study of lung cancer patients with the help of bronchoscopy and evaluating the lung cancer patterns in such patients

Kaushal Bhavsar¹, Gunjan Pareshkumar Upadhyay^{2,*}

¹Dept. of Pulmonary Medicine, GMERS Medical College, Sola, Ahmedabad, Gujarat, India

²Dept. of Pulmonary Medicine, GMERS Medical College, Gandhinagar, Gujarat, India



ARTICLE INFO

Article history:

Received 23-10-2019

Accepted 16-11-2019

Available online 09-12-2019

Keywords:

Bronchoalveolar lavage

Fiber optic video bronchoscopy

Lung malignancy

Smoking

Transbronchial needle aspiration

ABSTRACT

Introduction and Aim: Bronchoscopy is highly sensitive investigation for patients with suspected lung malignancy. Beside histology, a cytological diagnosis is also possible with the help of bronchoscopy. In present study, we describe our experience of performing bronchoscopy in patients with suspected lung cancer.

Materials and Methods: Present study was prospective observational study done over a period of one year at a tertiary care centre of western India. In this study 75 patients were recruited in the study that had suspected lung cancer and subjected to bronchoscopy also. A detailed clinical history, physical examinations was done before hand and necessary investigations were also done. Selected patients with chest x-ray and CT scan and clinical findings consisting with lung cancer were subjected for flexible fiber-optic video bronchoscopy after obtaining well informed written consent.

Result: Most of the patients were between 51-70 years of age. 59 patients were male, and 16 patients were female. Bronchoalveolar lavage (BAL) was performed in all patients and given positive result in 42 patients. Yield of BAL was 56.0%. Endo-bronchial biopsy was performed in 58 patients and gave positive result in 47 patients. Yield of Bronchial biopsy was 81.03%. Adenocarcinoma was commonest type present in 40% of participants, while second most common was Squamous cell carcinoma. Small cell carcinoma was present in 4.%, Large cell carcinoma in 1% and Undifferentiated carcinoma in 12% of patients.

Conclusion: Premature recognition of lung cancer in the airway is vital for evading the multi-step sequence to invasive cancer. Though tissue biopsy is the gold standard for diagnosing neoplastic and preneoplastic disease, bronchoscopic technologies are the safest and most precise tools to assess both central and distal airway mucosa.

© 2019 Published by Innovative Publication. This is an open access article under the CC BY-NC-ND license (<https://creativecommons.org/licenses/by/4.0/>)

1. Introduction

worldwide in both genders combined, lung cancer is the on the whole frequently diagnosed cancer and the important cause of cancer death.¹ Flexible fiber -optic bronchoscopy (FOB) is very safe and highly sensitive investigation for patients suspecting lung malignancy.² Beside histology, cytological diagnosis is possible with the help of such bronchoscopy. In modern days, immense attention in the histological categorization of lung cancer in consideration of newer histology guided therapeutic

modalities and genomic classification of lung carcinoma. In western countries and the majority of the Asian countries, adenocarcinoma has outshines squamous cell carcinoma in terms of occurrence. This change appears to be attributable somewhat to the transformed smoking pattern and rising incidence of lung cancer in females and non- smokers.^{3,4} Tobacco smoking constitutes the single most important carcinogen for lung cancer.

The expected diagnostic yield of flexible fiber -optic bronchoscopy depends on location and distribution of the tumour.⁵ Central and endobronchial lesions have the highest diagnostic yield. The use of transbronchial needle aspiration (TBNA) and bronchoalveolar lavage (BAL) can augment

* Corresponding author.

E-mail address: drupadhyaygunjan@gmail.com (G. P. Upadhyay).

the yield substantially. Biopsy of solid lesion can assist in analysis of over 60% of cases but the success rates are lesser if the lesion is intramural in place and falls further if the lesion is distant from idea of bronchoscopy. Since its introduction, published rates of complication from flexible fiber-optic bronchoscopy have ranged from <0.1 to 11%, with mortality generally reported between 0 and 0.1%.⁶

2. Materials and Methods

Present study was observational prospective study completed over a time of one year at a tertiary care centre of western India. In this study all patients with suspected lung cancer and subjected to bronchoscopy were recruited in the study after taking informed consent. A detailed clinical history, physical examinations was done before hand and necessary investigations were carried out for example chest radiography, CT scan of thorax, haematological examination, sputum for AFB, etc. Patients with HIV AIDS were excluded from the study. Children less than 18 years of age, patients who did not give consent for the study and patients who had absolute contraindications for performing fibreoptic bronchoscopy were excluded from the study.

3. Results and Discussion

Greater than 28% of every cancer mortality each year are due to lung cancer.⁷ Lung cancer stands for the chief reason of cancer death all over the world, with 1.4 million deaths every year due to lung cancer.⁸ As per WHO figures, Egypt has the maximum death rate, prevalence, and incidence in North Africa.⁹

This study included 75 patients with primary malignancy of the lung (59 male and 16 female patients). Majority of the patients in this study were in age group of 51 to 70 years (58.66%). (Figure 1) Cough was the most common symptom present in 67(89.33%) of the patients followed by dyspnoea 40(53.33%), chest pain 34(45.33%), haemoptysis 33(44.0%), weight loss 23 (30.66%) and hoarseness of voice 16(21.33%). Fever was present in 10 patients (13.33%) while dysphagia was observed in 4(5.33%) patients. Clinical signs such as clubbing were present in 32(42.66%) patients and cervical lymphadenopathy was present in 20 (26.66%) patients. In this present study, 52(69.33%) patients were current or former smokers and 23(30.66%) were never-smokers, finding of this study were in harmony with the findings of Safwat et al.¹⁰

Bronchoscopy guided endo-bronchial biopsy was more specific than BAL cytology. 27 (36.0%) patients were diagnosed based on only endo-bronchial tissue biopsy histopathology report. 20 patients (26.66%) were diagnosed by both BAL cytology and endo-bronchial biopsy histopathology examination. 17(22.66%) patients were diagnosed by only BAL cytology. 2(4.4%) patients were diagnosed by both BAL cytology and TBNA. One patient

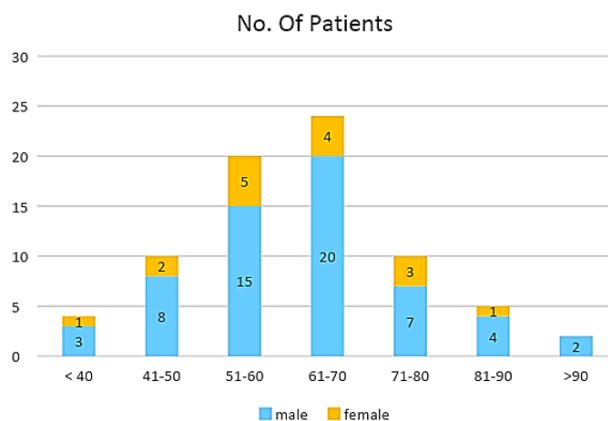


Fig. 1: Distribution of patients according to age and gender

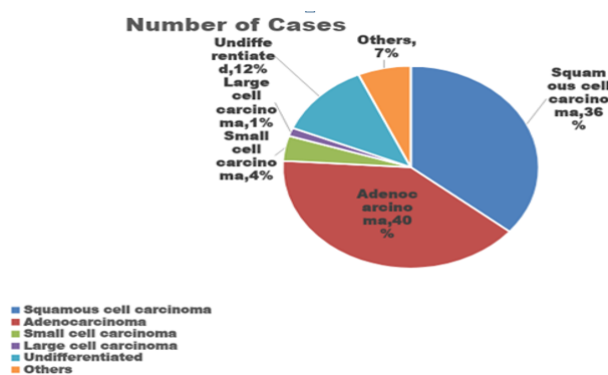


Fig. 2:

(1.33%) was diagnosed exclusively on TBNA report. Post bronchoscopy sputum cytology and BAL both together helped to arrive at diagnosis in 2 (2.66%) patients. 4 patients (5.33%) was diagnosed by post bronchoscopy sputum cytology only without the help of any other reports.

In this present study, 52(69.33%) patients were current or former smokers and 23(30.66%) were never-smokers. Out of smokers, 90.1% smokers had smoking history of ≥ 20 pack years of smoking. No one of female was smokers. Amid Smokers, Squamous cell carcinoma was more frequent histological subtype found. Findings of this were also in harmony with the research of Kshatriya et al¹¹ who found among 25 cases of malignancy, 19 smokers and six nonsmokers. Squamous cell carcinoma was observed more in smokers, which was in agreement with findings of Mazharand Jehanzeb.¹²

Metastasis was found in 82.5% patients at the time of diagnosis. In lungs, upper lobe was most commonly involved, wherein left upper lobe was most commonly involved. For proper staging of the tumor patients were referred to the nearby cancer institute where the further management of theirs was carried out. Finding of this study were in harmony with Rabahiet al¹³ who describe the

Table 1: Distribution of patients according to bronoscopic procedures

Bronoscopic Procedure done	Performed in No of Patients	Positive for malignant cells in following number of Patients	Percentage (%)
Broncho alveolar lavage (BAL)	75	42	56.0%
Endobronchial Biopsy	58	47	81.03%
Trans-bronchial needle aspiration (TBNA)	6	3	50.0%
Sputum Cytology (Immediately Post Bronchoscopy)	60	6	10.0%

Table 2: Anatomical site at which lesion was encountered during bronchoscopy

Anatomical site at which lesion was encountered during bronchoscopy	Number of Cases	%
In trachea	2	2.667%
Near carina	21	28.000%
In Main bronchi	27	36.000%
In Upper lobe bronchus	14	18.667%
In lower lobe bronchi or bronchus intermedius	11	14.667%

Table 3: Macroscopic presentation of lesion seen in bronchoscopy

Macroscopic presentation of lesion seen in bronchoscopy	Number of Cases	%
End bronchial lesion	28	37.333%
Luminal Narrowing	19	25.333%
Mucosal infiltration	4	5.333%
External Compression	17	22.667%
Combination of above	7	9.333%

Table 4: Association of type of cancer with gender, smoking, metastasis and bronchoscopic procedure

Variables	Squamous Cell Ca (n=22)	Adeno Carcinoma (n=20)	Odds ratio	95% confidence limits	Measure of Association (p value)
Gender	Male	16	1.05	0.96, 1.36	0.05*
	Female	6			
Smoking	Present	17	1.25	0.98, 1.61	0.01*
	Absent	5			
Metastasis	Present	17	1.30	1.07, 1.69	0.001*
	Absent	5			
Bronchoscopic procedure	BAL Cytology	13	1.02	0.89, 1.67	0.02*
	Bronchial biopsy H&P	9			

location of noticeable tumors in 169 cases; the tumor was there in the upper lobe bronchi in 48% of cases.

In this present study, only 3(4%) out of 75 patients had complications. There were no serious complications and there was zero mortality. 2 patients had bleeding from biopsy site during endo-bronchial biopsy which was easily controlled with ice-cold 0.9% normal saline lavage. 1 patient developed bronchospasm who was a known case of COPD. Bronchospasm was controlled within short period with inhaled bronchodilators (Levosulbutamol) which were administered soon after the patient was shifted to short general anaesthesia (propofol) by expert standby

anaesthetist and then the procedure was carried out without further complications.

Table 4 explains association of type of cancer with gender, smoking, metastasis and bronchoscopic procedure. It was observed that males had a significant ($p \leq 0.05$) higher risk ratio of squamous cell and Adeno Carcinoma contrast to females. Smoking was more linked with squamous cell carcinoma and differences between two carcinoma groups were significant statistically. (Odds ratio: 1.25) ($p \leq 0.05$) Similarly, metastasis was more associated with squamous cell carcinoma and it was also statistically significant (Odds ratio: 1.30). There was

statistically significant differentiation observed between the bronchoscopic procedures like BAL cytology and Bronchial Biopsy in diagnosis of squamous and adenocarcinoma. ($p \leq 0.05$) (Odds ratio: 1.02)

4. Conclusion

Premature recognition of lung cancer in the airway is vital for evading the multi-step sequence to insidious cancer. Even though tissue biopsy is the gold standard for analysing neoplastic and preneoplastic disease, bronchoscopic technologies are the safest and most precise apparatus to assess both central and distal airway mucosa. Appropriate screening and premature diagnostic methods should be functional on a huge scale to discover out alleged patients who are at risk of rising lung cancer.

5. Source of funding

None.

6. Conflict of interest

None.

7. Acknowledgment

None.

References

1. Bray F, Ferlay J, Soerjomataram I, Siegel RL, Torre LA, Jemal A. Global cancer statistics 2018: GLOBOCAN estimates of incidence and mortality worldwide for 36 cancers in 185 countries. *CA: A Cancer J Clin*. 2018;68:394–424.
2. Rivera MP, Mehta AC, Wahidi MM. Establishing the diagnosis of lung cancer: Diagnosis and management of lung cancer. *Chest*. 2013;143:142–65. American College of Chest Physicians evidence-based clinical practice guidelines.
3. Wakelee HA, Chang ET, Gomez SL. Lung cancer incidence in never smokers. *J Clin Oncol*. 2007;25(5):472–478.
4. Lortet-Tieulent J, Soerjomataram I, Ferlay J, Rutherford M, Weiderpass E, Bray F. International trends in lung cancer incidence by histological subtype: Adenocarcinoma stabilizing in men but still increasing in women. *Lung Cancer*. 2014;84(1):13–22.
5. Gasparini S, Ferretty M, Such E. Integration of transbronchial and percutaneous approach in the diagnosis of peripheral pulmonary nodules or masses: experience with 1027 consecutive cases. *Chest*. 1995;108(1):131–137.
6. David S, Kathleen R, Thomas P. Complications of bronchoscopy: A concise synopsis. *Int J Crit Illn Inj Sci*. 2015;5(3):189–195.
7. Cancer facts and Figures: American Cancer Society; Atlanta: Lung cancer deaths Inc. 2016; p. 17/72.
8. GLOBOCON Lung cancer incidence and mortality worldwide in 2008 Available from: <http://globocan.iarc.fr/factsheets/cancers/lung.asp>. [Accessed 1 August 2013].
9. Ferlay J, Bray F, Parkin DM, Pisani P, Globocan. FR/globocan). fiber optic bronchoscopy on arterial oxygen saturation. *J Islamic Med Assoc (USA)*. 2000;32(5):30–33. IARC Cancer base.
10. Safwat T, Samy H, Helmy H. Lung cancer presentations and sites in fiber optic bronchoscopy. *Cairo: Faculty of Medicine*. 2017;p. 69–89.
11. Kshatriya RM, Khara NV, Paliwal R, Patel S. Role of flexible fiber-optic bronchoscopy in the diagnosis of pulmonary diseases in rural-based tertiary hospital. *Int J Med Sci Public Health India*. 2016;5:873–876.
12. Mazhar M, Jehanzeb A. Fibro optic bronchoscopy diagnostic outcome and complications in patients with hilar and para hilar lung opacities. *Professional Med J*. 2006;13:384–390.
13. Rabahi MF, Ferreira AA, Reciputti BP, Matos TO, Pinto SA. Fiber optic bronchoscopy findings in patients diagnosed with lung cancer. *J Bras Pneumol*. 2012;38:445–451.

Author biography

Kaushal Bhavsar Assistant Professor

Gunjan Pareshkumar Upadhyay Associate Professor

Cite this article: Bhavsar K, Upadhyay GP. Study of lung cancer patients with the help of bronchoscopy and evaluating the lung cancer patterns in such patients. *Indian J Immunol Respir Med* 2019;4(4):230-233.