

## Vanishing primary lung aspergilloma in young female with diabetes mellitus

Jyoti Bajpai<sup>1</sup>, Darshan Kumar Bajaj<sup>2</sup>, Surya Kant<sup>3,\*</sup>

<sup>1</sup>Senior Resident, <sup>2</sup>Assistant Professor, <sup>3</sup>Professor and Head, Dept. of Respiratory Medicine, King George's Medical University, Lucknow, Uttar Pradesh, India

**\*Corresponding Author:**

Email: skantpulmed@gmail.com

### Abstract:

Aspergilloma is a saprophytic infection caused by *Aspergillus fumigatus*. It is common but frequently misdiagnosed clinical condition. It is usually diagnosed in patients with a long standing history of tuberculosis and other diseases leading to cavity formation. Although, primary Aspergilloma also seen in immune compromised patient without previous history of cavitary lung disease. Aspergilloma have unique radiological manifestation. Very rarely, they have been resolved without surgical intervention. We hereby report a case of primary Aspergilloma in cavitary lung mass presenting with hemoptysis in young diabetic female. The establishment of Aspergilloma as the underlying diagnosis led to conservative medical treatment which was followed by complete resolution of the cavitary mass like opacity. The present case highlights that Aspergilloma can be conservatively managed with antifungal therapy leads to disappearance of lesion.

**Keywords:** CECT thorax; Hemoptysis; Primary aspergilloma.

### Introduction:

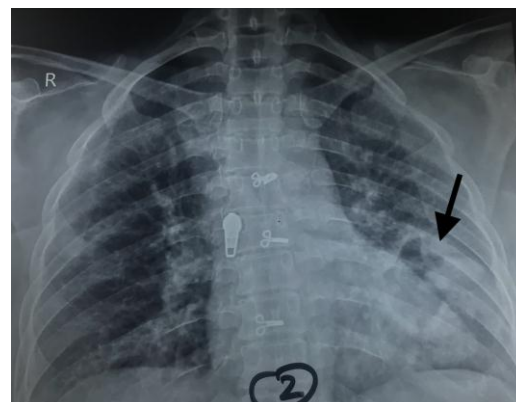
Pulmonary Aspergilloma is caused due to the inhalation of the fungal spores in patients with preexisting cavitary lung disease. The fungal hyphae admixed with mucus and cellular debris within a pulmonary cavity or ectatic bronchus forms an Aspergilloma or fungal ball (secondary Aspergilloma). Aspergilloma has been reported in 15-18% cases of residual tubercular cavities, followed by sarcoidosis [1].

Majority of patients with Aspergilloma remain asymptomatic. Among those who are symptomatic, hemoptysis is the most common complaint. It has been seen in 50-90% of Aspergilloma patients [2]. In many cases, an Aspergilloma is suspected when a discrete, round or oval density, occupying the upper lobe cavity is incidentally noticed in a chest X-ray. Presence of serum precipitins against *Aspergillus* is confirmatory test. Aspergilloma passes through various phases in the clinical spectrum. The fungus grows and dies continuously, undergoes regressive changes in its structure, fragments and forms focal calcification. In majority of cases, the dead fungus liquefies, and is eliminated with the sputum. Herein, we report a rare case of left lower lobe primary aspergilloma, which was completely resolved on antifungal therapy.

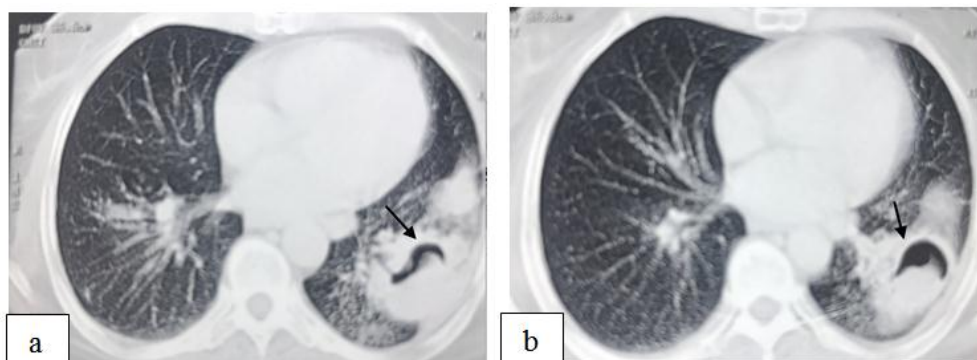
### Case Report:

A 30 years old diabetic female presented to our department with complained of hemoptysis for last two months. One year back she had had a similar episode of hemoptysis for one week with fever and cough. At that time she was treated empirically with antibiotics. She had never been treated with antitubercular therapy in past. On presentation to our department she was febrile with normal oxygen saturation. On auscultation crackles were present in left infrascapular area. Testing for the viral markers was negative. Her chest X-ray

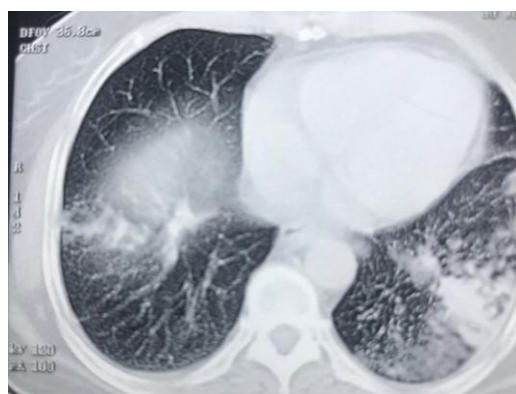revealed a cavitary lesion in left lower lobe (Fig. 1). A Mantoux test showed 10 mm induration. Smear and culture results were negative for acid fast bacilli. Sputum smear for Cartridge Based Nucleic Acid Amplification Test (CBNAAT) was also suggestive of no acid fast bacilli. Smear and culture results were positive for *Aspergillus fumigatus*. Chest computed tomography (Fig. 2a, 2b) revealed left lower lobe cavity with radio-opaque gravity dependent ball that moved inside the cavity in supine and prone position. Patient is known diabetic for last five years and she is on oral hypoglycemic agents. She is immunocompromised so she is prone to primary Aspergilloma. On the basis of clinical and radiological aspect a diagnosis of primary Aspergilloma of left lower lobe was made. The patient had been treated with Itraconazole for one year and has remained asymptomatic for last seven months, with no recurrent hemoptysis. Follow-up of the patient was done, and chest computed tomography was repeated after one year of itraconazole therapy revealed complete resolution of the Aspergilloma (Fig. 3).



**Fig. 1: Chest X-ray PA view showed a cavitary lesion in left lower lobe.**



**Fig. 2 a,b:** CECT Thorax showed left lower lobe cavitory mass with fungal ball ( black arrow)



**Fig. 3:** Follow up ct thorax after one year showed resolution of Aspergilloma

### Discussion:

Aspergillus is a ubiquitous fungus that causes varied pulmonary diseases ranging from an invasive infection to non-invasive diseases. Invasive pulmonary Aspergillosis is also seen in immune compromised patient. However chronic pulmonary Aspergillosis (CPA) occurs primarily in immune competent patients. Aspergilloma is one of manifestation of CPA. It involves the saprophytic growth of Aspergillus in preformed lung cavity. Aspergilloma is generally a radiological diagnosis and is often a complication of a post-tubercular cavity. Diagnosis of Aspergilloma is confusing in developing countries with high prevalence of tuberculosis. Hemoptysis is commonly seen in both tuberculosis and Aspergilloma diseases. Primary Aspergilloma is seen in immunocompromised cases like HIV, steroid therapy, diabetes, etc. However, secondary Aspergilloma is seen in preformed cavitory lung disease. Primary Aspergilloma which arises with in bronchial tree with proliferating Aspergillus leading to cavity formation is very uncommon [3]. This patient presented with hemoptysis, which is the most common symptom among the patients with Aspergilloma. The chest radiologic finding showed fibrotic changes as a consequence of previous tuberculosis infection in most patients and a mass-like lesion in few patients [4]. In

our case, patient did not have a history of tuberculosis and she was diabetic which lead to Aspergilloma formation in left lower lobe. She responded well to itraconazole therapy. Spontaneous disappearance of Aspergilloma has been reported in 7–10% of cases [5]. Aspergilloma can be bilateral or multiple. CT-chest may be helpful to diagnose fungal ball. More than 50% cases of Aspergilloma are positive for fungal culture. Life threatening hemoptysis seen in small number of patients and surgical intervention is needed. Our case responded well to the antifungal therapy.

**Conflicts of Interest:** None declared.

**Acknowledgements:** None

### References:

1. Denning DW, Riniotis K, Dobrashian R, Sabatakou H. Chronic cavitory and fibrosing pulmonary and pleural aspergillosis: case series, proposed nomenclature change, and review. *Clin Infect Dis*. 2003;37:S265–80.
2. Ma JE, Yun EY, Kim YE, Lee GD, Cho YJ, Jeong YY, et al. Endobronchial Aspergilloma: Report of 10 Cases and Literature Review. *Yonsei Med J*. 2011;52:787–92.
3. Izidor K, Anton L. Allergic bronchopulmonary aspergillosis with coexistent aspergilloma: A case report. *J Med Case Rep*. 2010;4:309.
4. Kim SJ, Lee EJ, Lee TH, Yoo KH, Lee KY. A case of endobronchial aspergilloma. *Tuberc Respir Dis*. 2006;61:60–4.
5. Henry M, Simon J, Alan W. Chronic pulmonary aspergillosis- long term follow up over 20 years: A case report. *Thorac Radiol*. 2010;4:23–30.