

## Endobronchial Tuberculosis: A case report

Vishal Jhanwar<sup>1</sup>, Surya Kant<sup>2,\*</sup>, Rohit Pathak<sup>3</sup>

<sup>1</sup>Chest Physician, <sup>2</sup>Professor & Head, <sup>3</sup>Junior Resident, <sup>1</sup>Biharilalji Jhanwar Memorial Hospital, <sup>2,3</sup>Department of Respiratory Medicine King George's Medical University

**\*Corresponding Author:**

Email: skantpulmed@gmail.com

---

### Abstract

Pulmonary tuberculosis is one of the major health problems worldwide. Endobronchial tuberculosis (EBTB) is a unique type of pulmonary tuberculosis. About 10-40% of patients with active pulmonary tuberculosis have EBTB as reported in previous studies. It has been defined as tuberculous infection of the tracheobronchial tree with microbial and histopathological evidence. For early diagnosis a high index of clinical suspicion is required and bronchoscopy should be performed as soon as possible in suspected patients. Bronchoscopic sampling has been the key to the diagnosis producing more than 90% yield on smear as well as on culture. Early diagnosis and prompt treatment, before the development of fibrosis is important to prevent complications of endobronchial tuberculosis, such as bronchostenosis. We herein, report a case of endobronchial TB diagnosed by bronchoscopy guided endobronchial biopsy.

**Keywords:** Biopsy; Bronchoscopy; Endobronchial Tuberculosis; Histopathology; Tracheobronchial Tree; Ulcers.

---

### Introduction

Endobroncheal tuberculosis which refers to the involvement of trachea and bronchi, was first described in 1689 by Richard Morton and it occurs in about 10-40% of patients with active tuberculosis [1,2]. Most common age of presentation for endobronchial TB is less than 35 years [3]. The common symptoms of endobronchial TB include cough with expectoration, hemoptysis, breathlessness, and wheeze [4]. The occurrence of an irritable barking cough unresponsive to antitussive medication has also been described as a clinical presentation of endobronchial TB [5]. However, this entity remains a diagnostic challenge even in countries with a high prevalence of TB. It can also present with variety of nonspecific symptoms like nonproductive cough, weight loss and hoarseness of voice. The long term complication of EPTB is bronchostenosis which occur in upto 68% of cases[6,7].

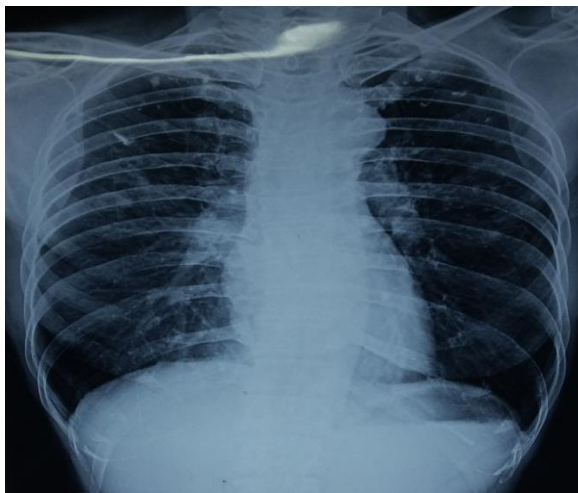
### Case Report

Our patient was a forty eight-year-old non-smoker female who presented with complaints of progressive breathlessness and dry cough for 18 months. Breathlessness was not associated with chest pain and palpitations. She had dry cough which was not associated with seasonal or diurnal variation, post nasal drip, gastro esophageal reflux disease. Patient also had low grade fever with no diurnal variation for 1 month.

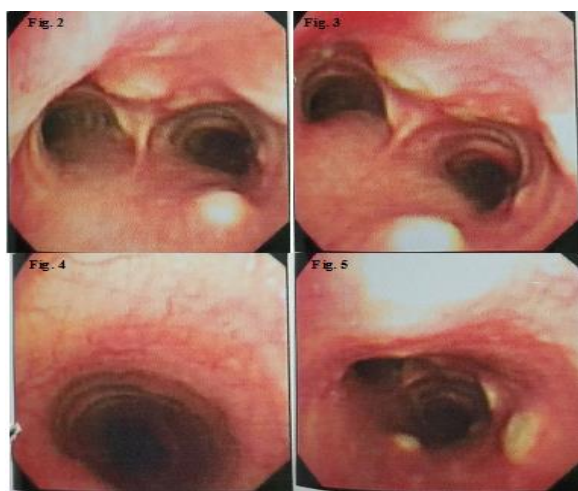
She belonged to a low socio-economic status and had no prior history of anti-tubercular therapy (ATT). She had no history of any immunocompromised states, diabetes and hypertension. No significant family history was present. Her hematological investigations were- hemoglobin (Hb)-9.8gm%, total leucocytes count (TLC)-7200/mm<sup>3</sup>, differential leucocyte counts (DLC)-lymphocytes 46%, polymorph cells 50%, eosinophils 2%, monocytes 2%. Erythrocyte sedimentation rate was

44 mm/hr. Mantoux test was positive (20mm induration). Chest X-ray PA view (Fig. 1) was suggestive of old healed calcified lesion in upper zone.

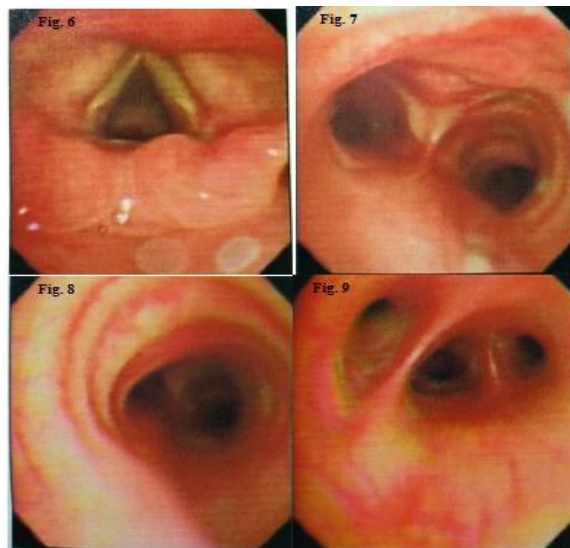
Patient was on inhaled medications and oral bronchodilators for last one year and was not symptomatically improved. Bronchoscopy (Fig. 2,3,4,5) findings included multiple yellowish nodules and ulcers in trachea and carina. Left main, segmental bronchus, right main and segmental bronchus was normal. Endobronchial biopsy was suggestive of tubercular granulation tissue. Anti-tubercular treatment was started with Rifampicin, Isoniazid, Ethambutol and Pyrazinamide as per weight. Patient was symptomatically improved; repeat bronchoscopy (Fig. 6, 7, 8 & 9) was done after 3 months of treatment demonstrating complete healing. Patient continued with Rifampicin, Isoniazid and Ethambutol for 3 more months. Complete resolution of symptoms occurred after 6 months of treatment.



**Fig. 1:** Chest X-ray PA view showing Calcified lesion in bilateral upper zone



**Fig. 2, 3, 4, 5:** Fiberoptic bronchoscopy showing multiple yellowish nodules and ulcers in trachea and carina



**Fig. 6, 7, 8, 9:** Fiberoptic bronchoscopy showing healed ulcers and resolution of pathological lesions after anti-tubercular therapy

## Discussion

Endobronchial TB is commoner in young adults and exhibits a female preponderance [8]. However, about 15% of geriatric patients may also have endobronchial TB [9]. Endobronchial spread of tuberculosis may lead to unexpected outcomes and poor response. The most common sites involved in endobronchial tuberculosis are right upper lobe and right main bronchus. The radiological appearances involve consolidation or loss of volume. However, a normal chest X-ray does not rule out endobronchial pathology. About 20% cases of EBTB have normal chest X-ray. It is known that the prime factor in the diagnosis of endobronchial TB is a performance of diagnostic bronchoscopy. Apart from visualization of bronchial tree abnormalities suggestive of endobronchial TB, fiberoptic bronchoscopy can also provide excellent material for diagnosis of suspected cases of pulmonary TB especially when sputum smears are negative for AFB [10]. To eradicate mycobacteria and prevent complications, early diagnosis should be made and treatment must be initiated. On the basis of fiberoptic bronchoscopic findings endobronchial TB is divided into seven subtypes- (i) actively caseating, (ii) edematous-hyperemic, (iii) stenotic, (iv) tumorous, (v) granular, (vi) ulcerative, and (vii) nonspecific bronchitis [11]. In this patient chest X-ray was only suggestive of old healed lesions. Mantoux test helped in making a provisional diagnosis of tubercular etiology leading to further bronchoscopic investigation. Bronchoscopy revealed nodular and ulcerative growth in trachea and carina which is a common finding in endobronchial TB. Diagnosis was confirmed by histopathology. Patient responded gradually to anti-tubercular therapy which was given for six months.

## Conclusion

EBTB is relatively uncommon manifestation of a common disease. The exact pathogenesis of EBTB is not yet completely understood. The diagnosis of EBTB depends on the presence of specific endobronchial inflammatory lesions and culture of mycobacterium from bronchoscopic samples. The desired therapeutic outcome of EBTB is healing without significant sequelae. Bronchoscopy is mandatory not only for the initial diagnosis but also for follow-up.

**Conflicts of interest:** None declared

**Acknowledgements:** None

**Consent:** A written and informed consent was taken from subject prior to publication of case details and accompanying images.

## References

1. Dye C, Scheele S, Dolin P, et al. Global burden of tuberculosis: Estimated incidence, prevalence, and mortality by country. WHO Global Surveillance and Monitoring Project. *JAMA*. 1999;282:677–86.
2. Millard PS, Cegielski JP, Wing S, et al. Rural and tuberculosis incidence trends in North and South Carolina, 1982 to 1992. *J Rural Health*. 1994;10:226–36.
3. Ip MS, Lam WK, So SY, Mok CK. Endobronchial tuberculosis revisited. *Chest*. 1986;89:727–30.
4. Xue Q, Wang N, Xue X, Wang J. Endobronchial tuberculosis: an overview. *European Journal of Clinical Microbiology and Infectious Diseases*. 2011;30:1039–044.
5. Eloesser L. Bronchial stenosis in pulmonary tuberculosis. *American Review of Tuberculosis*. 1934;30:123–80.
6. Hoheisel G, Chan BK, Chan CH, et al. Endobronchial tuberculosis: Diagnostic features and therapeutic outcome. *Respir Med* 1994;88:593-97.
7. Hudson EH. Respiratory tuberculosis: Clinical diagnosis. In: Heaf ERG, ed. *Symposium on Tuberculosis*. London: Cassell and Co. 1957:321-464.
8. Lee JH, Park SS, Lee DH, Yang SC, Yoo BM. Endobronchial tuberculosis: clinical and bronchoscopic features in 121 cases. *Chest*. 1992;102:990–94.
9. Van Den Brande PM, van de Mierop F, Verbeken EK, Demedts M. Clinical spectrum of endobronchial tuberculosis in elderly patients. *Archives of Internal Medicine*. 1990;150:2105–2108.
10. Bachh AA, Gupta R, Haq I, Varudkar GH. Diagnosing sputum/smear-negative pulmonary tuberculosis: does fiberoptic bronchoscopy play a significant role. *Lung India*, 2010;27:58–62.
11. Chung HS, Lee JH. Bronchoscopic assessment of the evolution of endobronchial tuberculosis. *Chest*. 2000;117:385–392.3.