

Content available at: <https://www.ipinnovative.com/open-access-journals>

IP Indian Journal of Immunology and Respiratory Medicine

Journal homepage: <https://www.ijirm.org/>

## Case Report

# Diagnostic challenges in dyskeratosis congenita: Pulmonary fibrosis and multifaceted manifestations

Jayabharathi Palanivel<sup>1</sup>, Pratap Upadhyaya<sup>1</sup>, Zeenathalam Nadaf<sup>1\*</sup>, Karthik B<sup>1</sup>, Prabhu Manivannan<sup>2</sup>

<sup>1</sup>Dept. of Pulmonary Medicine, Jawaharlal Institute of Postgraduate Medical Education & Research, Pondicherry, India

<sup>2</sup>Dept. of Pathology, Jawaharlal Institute of Postgraduate Medical Education & Research, Pondicherry, India



## ARTICLE INFO

### Article history:

Received 31-07-2024

Accepted 21-09-2024

Available online 17-10-2024

### Keywords:

Dyskeratosis congenita  
Pulmonary fibrosis  
Respiratory failure  
Avascular necrosis  
Aplastic anemia

## ABSTRACT

**Introduction:** Dyskeratosis Congenita (DC) is a rare genetic syndrome characterized by mucocutaneous abnormalities, often complicating into progressive life-threatening systemic manifestations like bone marrow failure, increased rate of malignancy, lung, and liver diseases.

**Case Details:** Here is a case of a man in his 20s presenting with pulmonary fibrosis, who exhibited classic DC skin and nail changes, along with a history of avascular necrosis. Despite the absence of a family history, a thorough evaluation led to a diagnosis of DC.

**Conclusion:** This report sheds light on the urgency for early recognition and intervention. The absence of a definitive treatment protocol for DC-related pulmonary fibrosis emphasizes the need for further research in this area.

This is an Open Access (OA) journal, and articles are distributed under the terms of the [Creative Commons Attribution-NonCommercial-ShareAlike 4.0 License](https://creativecommons.org/licenses/by-nc-sa/4.0/), which allows others to remix, tweak, and build upon the work non-commercially, as long as appropriate credit is given and the new creations are licensed under the identical terms.

For reprints contact: [reprint@ipinnovative.com](mailto:reprint@ipinnovative.com)

## 1. Background

Dyskeratosis Congenita (DC), recognized as Zinsser-Engman-Cole syndrome, is an inherited skin disorder characterized by the hallmark triad of oral leucoplakia, abnormal nails, and delicate reticular skin pigmentation as distinctive skin manifestations. The principal contributors to mortality include bone marrow failure resulting in pancytopenia, heightened susceptibility to malignancies, and life-threatening pulmonary complications.<sup>1</sup> A diverse range of somatic characteristics encompassing pulmonary fibrosis (PF), liver cirrhosis, and premature greying of hair, have been linked to DC. Approximately 20% of individuals with DC experience the development of pulmonary fibrosis.<sup>2</sup> Involvement of the genitourinary, skeletal, and neurological systems is less frequently observed.<sup>3,4</sup> To our understanding, this marks a unique presentation of DC in a

young male due to the coexistence of pulmonary fibrosis, avascular necrosis of the hip joint, and aplastic anemia. This case highlights the need for deeper insights into the pathophysiology of DC, the necessity for early identification and timely intervention. This demonstrates a rare cause of pulmonary fibrosis, emphasizing the importance of including DC as a differential diagnosis when assessing pulmonary fibrosis cases.

## 2. Case Details

A man in his late 20s had a history of smoking five cigarettes per day for the last 10 years. He had difficulty swallowing liquids and pain in the wrist joint and knee joint on and off for the past two years, along with grade III breathlessness as per the Modified Medical Research Council (mMRC) dyspnea scale and dry cough for one year. He presented to our hospital with easy fatigability, increased breathlessness to mMRC grade IV, and increased dry cough over the last 4

\* Corresponding author.

E-mail address: [zeenath.a.alam@gmail.com](mailto:zeenath.a.alam@gmail.com) (Z. Nadaf).

weeks. He denied any history of febrile sensation, chills, or chest pain. He had never been exposed to occupational gas, organic dust, or chemical fumes.

His past medical history was significant for multiple episodes of epistaxis and blood transfusions in his teens and a diagnosis of AVN of the head of the femur in his early 20s. (Figure 2c) and further medical records were not available. Two years back, he was diagnosed clinically with pulmonary tuberculosis and given a 4-drug antitubercular drug for six months.

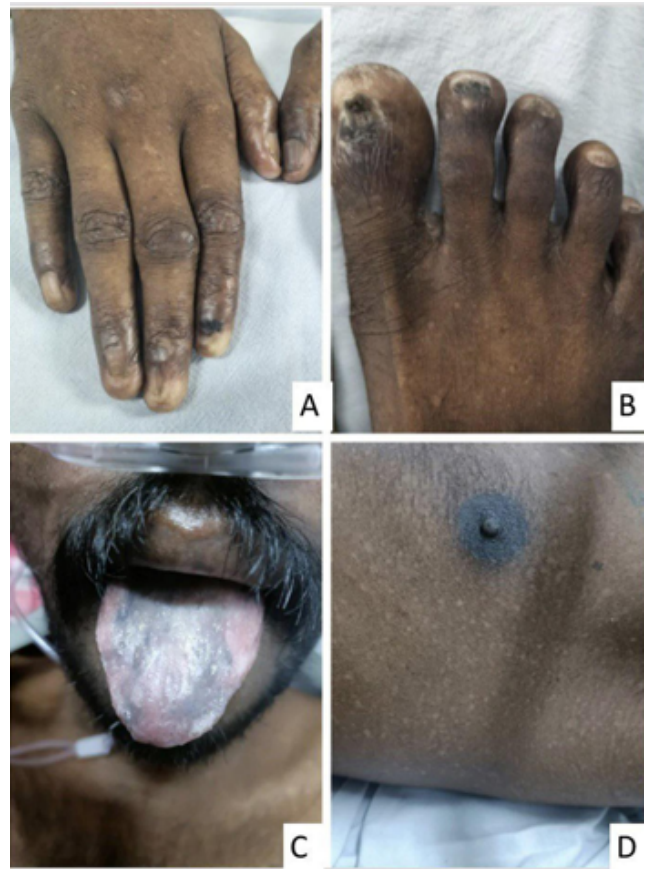
General examination revealed mottled skin with hyperpigmentation on the anterior chest, back of elbows, and neck interspersed with hypo-pigmented macules, but he didn't have a history of photosensitivity or skin allergy or rashes. The oral mucosa and tongue showed grey pigmentation along with significant atrophy and dystrophy in all his fingers and toenails (Figure 1). There were no signs of any joint swelling. On auscultation, bilateral diffuse fine-end inspiratory crepitations were heard predominantly in the lower interscapular and infraaxillary areas. On the day of the visit, his pulse rate was 120/min, blood pressure was 102/54 mm Hg, respiratory rate was 29/min, and room air saturation was 80% at room air by pulse oximetry. ABG showed hypoxemic respiratory failure with a PaO<sub>2</sub>/FiO<sub>2</sub> (P/F) ratio of 267.

Laboratory parameters showed bicytopenia with haemoglobin level of 9.7 g/dL, and a platelet count of 40x10<sup>3</sup>/mcL. His WBC counts were 4500 /mm<sup>3</sup>. Liver and renal function parameters were within the normal range. Viral markers, including HIV (Human Immunodeficiency Virus), Hepatitis B and C, Cytomegalovirus (CMV), and Dengue virus revealed no specific viral infection that could account for the observed bicytopenia. Sputum culture, AFB smear, and GeneXpert tests yielded negative results. Blood culture reports were sterile, and Procalcitonin levels were <0.05 ng/ml, eliminating the possibility of a local infection. His electrocardiogram showed normal sinus rhythm.

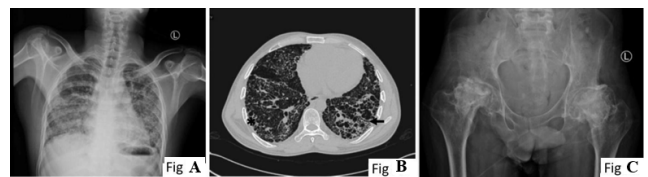A postero-anterior view of the chest radiograph revealed reticulonodular shadows in all zones (Figure 2a). HRCT thorax showed bi-basal sub-pleural predominant reticulations with honeycombing and traction bronchiectasis, suggestive of a definite usual interstitial pattern (UIP) (Figure 2b). As the patient was in hypoxemic respiratory failure, spirometry could not be performed.

Initially, a provisional diagnosis of connective tissue disorder-related interstitial lung disease (CTD-ILD) was made with possibilities of Rheumatoid arthritis or Systemic sclerosis. However, his laboratory findings, such as the Antinuclear antibody (ANA) profile by immunofluorescence (IF) was negative, Rheumatoid factor (RA) and anti-cyclic citrullinated peptide (Anti-CCP) were within the normal range, thus ruling out CTD related ILD.

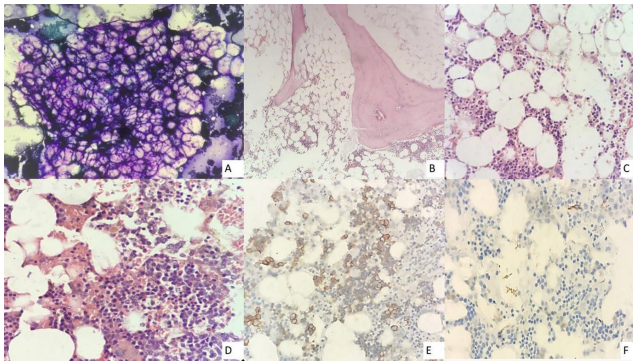
The dermatologist's opinion of the skin lesions revealed DC based on skin pigmentation, nail changes, and



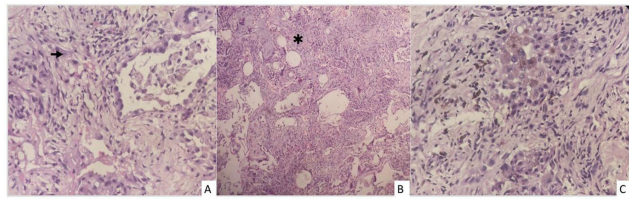
**Figure 1:** Mucocutaneous triad of abnormal skin pigmentation, nail dystrophy, and leukoplakia. (A,B) Markedly dystrophic and atrophic finger and toenails. (C) Leukoplakia on the tongue. (D) Abnormal fine reticular pigmentation around the chest.



**Figure 2:** Chest radiographposteroanterior view showing bilateral reticulonodular opacities in all zones (A), HRCT thorax showing sub-pleural predominant reticulations with honeycombing (marked with an asterisk) with traction bronchiectasis (marked with arrow) suggestive of the usual interstitial pattern (B), Anteroposterior radiograph of pelvis showing the bilateral collapse of the femoral head; Avascular necrosis of the hip (C).



**Figure 3:** Bone marrow biopsy suggestive of aplastic anemia; **A:** Bone marrow aspirate smears show hypocellular particles (400 X, Giemsa stain) **B:** Bone marrow biopsy shows hypocellular areas with 20% cellularity (100x, H and E stain); **C and D:** Interstitium shows erythroid colonies, lymphocytes, and plasma cells (400x, H and E stain) **E:** E-cadherin immunostain highlights early erythroid precursors (400x, IHC); **F:** CD34 immunostain did not highlight any immature cells (400x, IHC)



**Figure 4:** Post-mortem lung biopsy shows septal thickening, fibroblastic proliferation (marked by arrow), and pneumocytic hyperplasia (A). Smooth muscle proliferation is seen in the walls along with diffuse fibrosis (marked with an asterisk) (B). Few hemosiderin-laden macrophages are also seen (C), suggesting usual interstitial pneumonia. [Magnification of A and C x 400; Magnification of B x100]

leukoplakia, the typical triad of mucocutaneous syndrome (Figure 1). His family included two sibling sisters who had neither any skin pigmentation nor nail dystrophy. Given the presence of thrombocytopenia, and anemia, a bone marrow biopsy was performed, which revealed hypocellularity without any blast cells suggesting aplastic anemia (Figure 3). With a background of skin lesions, aplastic anemia, and avascular necrosis of the hip, he was diagnosed with acute exacerbation of fibrotic interstitial lung disease related to DC. Due to financial constraints, genetic analysis was not performed. DC was clinically diagnosed in accordance with the Clinical Utility Gene Card.<sup>5</sup>

Initially, the patient was kept on nasal prongs at 4-litre oxygen to maintain spo<sub>2</sub> of 88-92%. Given respiratory failure and no evidence of infection, he was treated with methylprednisolone 1g/day for 3 days as a treatment for acute exacerbation of interstitial lung diseases. Despite systemic steroids, his respiratory distress

worsened in subsequent days, antifibrotics were not started because of worsening hypoxemia and systemic steroid unresponsiveness. He was shifted to the intensive care unit as his oxygen requirement increased, he was initially kept on 15-litre oxygen on a non-rebreathing mask and planned for invasive mechanical ventilation, but the patient declined consent for intubation. He was kept on non-invasive ventilation which he tolerated for a day.

The patient's arterial blood gas (ABG) results indicated a deteriorating P/F ratio of 101, and unfortunately, the patient succumbed to respiratory failure on the fifth day of admission. Postmortem lung biopsy revealed features suggestive of UIP (Figure 4).

### 3. Discussion

Our case shows the unexpected alliance of pulmonary fibrosis, avascular necrosis, and aplastic anemia in a patient with DC. Classic DC is an inherited disorder of poor telomeroopathy characterized by the triad of atypical skin pigmentation, nail deformities, and mucosal leukoplakia.<sup>1,6,7</sup> An array of extracutaneous abnormalities, including those affecting the teeth, gastrointestinal system, urinary system, nervous system, eyes, lungs, and skeleton, have also been documented and however, the onset of presentation is highly variable.<sup>1,3</sup> Although DC is a genetic disorder, around half of the patients linked to DC had no family history in a systematic review conducted by Wang et al.,<sup>8</sup> which is like our case. This emphasizes the importance of having a high clinical suspicion for DC causing fibrotic interstitial lung disease, especially in patients under 60 years along with typical skin manifestations. It's crucial to carefully assess mucocutaneous changes, blood abnormalities, premature greying of hair, or liver cirrhosis, which could provide clues to underlying telomere biology disorders. In addition to mucocutaneous changes, our patient had blood abnormalities and pulmonary fibrosis.

Two distinct sets of diagnostic criteria for DC have been implemented: The initial set identifies patients with DC based on specific combinations of features.<sup>5</sup> These include the classic triad of abnormal skin pigmentation, nail dystrophy, and leukoplakia (Classic DC presentation), as well as a combination of one mucocutaneous feature plus Bone Marrow Failure (BMF) and at least two additional somatic features associated with DC. This set does not mandate genetic testing for diagnosis when classical mucocutaneous features are evident, as in the case of our patient. Furthermore, our patient met the clinical criteria for a diagnosis of DC without the necessity of genetic testing, as outlined in the provided criteria. The second set of criteria distinguishes between findings indicative of DC and the testing required to diagnose it conclusively.<sup>2</sup> Diagnosis requires patients to exhibit telomere lengths below the first percentile observed in healthy individuals. Telomere length can be measured using three commonly employed methods

such as Southern blot, real-time polymerase chain reaction, and flow cytometry with fluorescence in situ hybridization.<sup>9</sup>

The increased occurrence of PF among DC patients may precede or succeed hematopoietic cell transplantation (HCT).<sup>10,11</sup> As HCT is the ultimate solution for BMF in these individuals, it's advisable to stay vigilant for signs of PF post-HCT. However, in our case, the patient had PF without HCT. PF, a severe complication of DC, often leads to rapid deterioration and limited survival. This case highlights the absence of a definitive treatment protocol for DC-related pulmonary fibrosis. Nintedanib and Pirfenidone are approved in treating idiopathic pulmonary fibrosis but the effect of antifibrotic agents on Pulmonary fibrosis due to DC is still unclear. A study by Justet al.<sup>12</sup> evaluated lung function in TERT/TERC mutation of DC patients treated with pirfenidone, revealing no improvement in either forced vital capacity (FVC) or diffusion lung capacity for carbon monoxide (DLCO) decline in those with lung fibrosis.

In many cases, there's a delay in diagnosing patients with DC-related conditions, similar to what happened in our case. This delay can occur due to the rarity of this congenital disease, particularly in adult patients, and the late identification of complications like avascular necrosis, anemia, or PF in them. Furthermore, individuals with DC who have clinically evident PF often experience rapidly progressing disease with limited survival time.<sup>10,13</sup> Early recognition and intervention remain pivotal, though the prognosis remains guarded due to the rapid progression of end-stage pulmonary disease.

#### 4. Conclusion

In conclusion, this case illuminates the intricate interplay of DC syndrome with pulmonary fibrosis, avascular necrosis, and aplastic anemia. Early recognition, screening, multidisciplinary collaboration, and prospective research are pivotal in addressing the multifaceted challenges posed by DC and its associated complications. The study underscores the urgency for further research and early intervention to improve the prognosis and quality of life for individuals affected by this rare and complex disorder.

#### 5. Source of Funding

None.

#### 6. Conflict of Interest


None.


#### References


1. Dokal I. Dyskeratosis Congenita in All Its Forms. *Br J Haematol*. 2000;110(4):768–79.
2. Ballew BJ, Savage SA. Updates on the Biology and Management of Dyskeratosis Congenita and Related Telomere Biology Disorders.

3. Knight S, Vulliamy T, Copplestone A, Gluckman E, Mason P. Dyskeratosis Congenita (DC) Registry: identification of new features of DC. *Br J Haematol*. 1998;103(4):990–6.
4. Inoue S, Mekanik G, Mahallati M, Zuelzer WW. Dyskeratosis Congenita with Pancytopenia. Another Constitutional Anemia. *Am J Dis Child*. 1973;126(3):389–96.
5. Dokal I, Vulliamy T, Mason P, Bessler M. Clinical utility gene card for: Dyskeratosis congenita - update 2015. *Eur J Hum Genet*. 2015;23(4). doi:10.1038/ejhg.2014.170.
6. Cole HN, Rauschkolb J, Toomey J. Dyskeratosis congenita with pigmentation, dystrophia unguium, and leukokeratosis oris; review of the known cases reported to date and discussion of the disease from various aspects. *Arch Dermatol*. 1955;71(4):451–6.
7. Saez-De-Ocariz M, Orozco-Covarrubias L, Durán-Mckinster C, Ruiz-Maldonado RD. Neurocutaneous Disorders Phakomatoses and Hamartoneoplastic Syndromes. In: Ruggieri M, Pascual-Castroviejo I, Rocco CD, editors. *Dyskeratosis Congenita*. Vienna: Springer; 2008. p. 661–8. doi:10.1007/978-3-211-69500-5\_44.
8. Wang P, Xu Z. Pulmonary Fibrosis in Dyskeratosis Congenita: A Case Report with a PRISMA-Compliant Systematic Review. *BMC Pulm Med*. 2021;21:279. doi:10.1186/s12890-021-01645-w.
9. Ballew BJ, Yeager M, Jacobs K, Giri N, Boland J, Burdett L, et al. Germline Mutations of Regulator of Telomere Elongation Helicase 1, RTEL1, In Dyskeratosis Congenita. *Hum Genet*. 2013;132(4):473–80.
10. Giri N, Ravichandran S, Wang Y, Gadalla SM, Alter BP. Prognostic Significance of Pulmonary Function Tests in Dyskeratosis Congenita, a Telomere Biology Disorder. *ERJ Open Res*. 2019;5(4):209. doi:10.1183/23120541.00209-2019.
11. Barbaro P, Vedi A. Survival after Hematopoietic Stem Cell Transplant in Patients with Dyskeratosis Congenita: Systematic Review of the Literature. *Biol Blood Marrow Transplant*. 2016;22(7):1152–8.
12. Justet A, Thabut G, Manali E, Molina MM, Kannengiesser C, Cadranel J, et al. Safety and Efficacy of Pirfenidone in Patients Carrying Telomerase Complex Mutation. *Eur Respir J*. 2018;51(3):1701875. doi:10.1183/13993003.01875-2017.
13. Mahapatra M, Singh PK, Agarwal M, Prabhu M, Mishra P, Seth T, et al. Clinico-Haematological Profile and Management of Aplastic Anaemia: AIIMS Experience. *J Assoc Physicians India*. 2015;63(3):30–5.


#### Author biography

**Jayabharathi Palanivel**, Senior Resident  <https://orcid.org/0000-0001-6691-3759>

**Pratap Upadhya**, Associate Professor  <https://orcid.org/0000-0001-9303-9008>

**Zeenathalam Nadaf**, Senior Resident  <https://orcid.org/0009-0002-2781-3450>

**Karthik B**, Junior Resident  <https://orcid.org/0009-0000-1660-6830>

**Prabhu Manivannan**, Additional Professor  <https://orcid.org/0000-0001-8247-3343>

**Cite this article:** Palanivel J, Upadhya P, Nadaf Z, Karthik B, Manivannan P. Diagnostic challenges in dyskeratosis congenita: Pulmonary fibrosis and multifaceted manifestations. *IP Indian J Immunol Respir Med* 2024;9(3):110–113.