

Content available at: <https://www.ipinnovative.com/open-access-journals>

IP Indian Journal of Immunology and Respiratory Medicine

Journal homepage: <https://www.ijirm.org/>

Case Report

Common variable immunodeficiency- A delayed diagnosis of an underdiagnosed entity in resource limited setting

Tanya Thakur¹, Korada Vivek Naidu¹, Bikram Shah¹, Manoj Thakur¹,
 Sujeet Raina^{1*}

¹Dept. of Medicine, Dr. Rajendra Prasad Government Medical College, Kangra, Himachal Pradesh, India



ARTICLE INFO

Article history:

Received 14-06-2024

Accepted 03-07-2024

Available online 10-07-2024

Keywords:

Immunoglobulin
 Immunodeficiency
 Rhinosinusitis

ABSTRACT

We report a case of common variable immunodeficiency (CVID) in a 42-year-old female who presented with history of recurrent rhinosinusitis for the last ten years. Patient had developed cough and progressive dyspnoea for last one year. Patient was admitted with community acquired pneumonia and sputum culture was positive for *Pseudomonas aeruginosa*. Common variable immunodeficiency was diagnosed ten years after the onset of symptoms. CVID is an underdiagnosed disorder because of the low index of suspicion, lack of awareness, poor facilities for the investigations and higher prevalence of infectious diseases in developing countries. CVID should be suspected in patients with recurrent rhinosinusitis or pneumonia and evaluation of serum immunoglobulins is advised.

This is an Open Access (OA) journal, and articles are distributed under the terms of the [Creative Commons Attribution-NonCommercial-ShareAlike 4.0 License](https://creativecommons.org/licenses/by-nc-sa/4.0/), which allows others to remix, tweak, and build upon the work non-commercially, as long as appropriate credit is given and the new creations are licensed under the identical terms.

For reprints contact: reprint@ipinnovative.com

1. Introduction

Primary immunodeficiency disorders (PIDs) are a group of rare, genetic defects involving deficiencies or regulatory defects of innate and adaptive immune systems. These disorders result in manifestations like susceptibility to infections, autoimmunity, inflammation, allergy, and malignancy.¹ CVID is a heterogenous PID characterized by a complex syndrome of recurrent infections and autoimmune, inflammatory and neoplastic manifestations as a consequence of defective immunoglobulin production. We report the case of a CVID in a female patient who presented with recurrent rhinosinusitis for last 10 years. The diagnosis of CVID was based on European Society of Primary Immunodeficiency (ESID) Registry criteria as shown in Table 1.² The case is reported for the following reasons. 1. CVID is a rare disease. 2. To generate awareness among clinicians about CVID thus facilitate the diagnosis at

an early stage and institution of appropriate timely therapy

2. Case Report

A 42-year-old female, teacher by profession was admitted in the month of January, 2024 with history of recurrent rhinosinusitis for the last ten years. Patient reported history of cough for the last one year. The cough was associated with mucoid expectoration and for the last one week the expectorant was mucopurulent. Patient reported exertional dyspnoea for the last one year which progressed and was present at rest for the last one week. There was no history of hemoptysis. Patient complained of fever for last four days without chills and rigors. No history of wheeze, chest pain, pedal edema, joint pains, palpitations, epistaxis, rash, oral ulcers was reported by the patient. Treatment history revealed that patient had multiple admissions for her complaints in the past. Patient reported that she had an enlarged spleen for which a bone marrow aspiration was performed six years back. Patient gave history of multiple

* Corresponding author.

E-mail address: sujeetraina@gmail.com (S. Raina).

blood transfusions in the past. The patient did not give history of similar complaints in her family members. At the time of admission patient was afebrile, pulse was 98/min BP was 110/70 mmHg; RR was and SPO2 was 89%. On auscultation of chest, vesicular breath sound with normal intensity were audible. End inspiratory crackles were heard in bilateral infrascapular areas. Spleen was palpable 3 cms below left costal margin. Rest of the examination was normal.

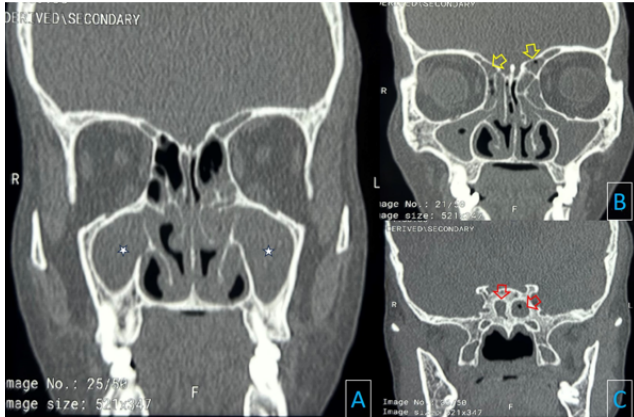


Figure 1: HRCT sinuses showing features of sinusitis of **A:** Maxillary sinuses (star); **B:** Ethmoidal sinuses (arrows); **C:** Sphenoid sinuses (arrows).

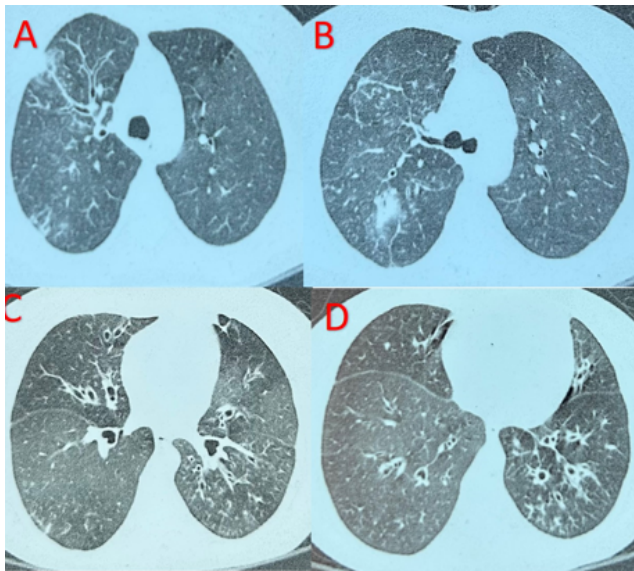


Figure 2: HRCT chest showing; **A:** Patches of consolidation with air bronchogram in lateral segment of right middle lobe; **B:** Patch of consolidation with air bronchogram in posterior segment of right upper lobe; **C & D:** Lower lobe bronchiectasis.

The results of her investigations are shown in Table 2. Sputum culture had growth of *Pseudomonas aeruginosa*. Sputum for acid fast bacillus and fungal stain was negative.

Table 1: Revised European Society of Primary Immunodeficiency (ESID) (2014) diagnostic criteria for CVID

At least one of the following

- Increased susceptibility to infection
- Autoimmune manifestations
- Granulomatous disease
- Unexplained polyclonal lymphoproliferation
- Affected family member with antibody deficiency

AND marked decrease of IgG and marked decrease of IgA with or without low IgM levels (measured at least twice; <2SD of the normal levels for their age)

AND at least one of the following:

- Poor antibody response to vaccines (and/or absent iso-hemagglutinins) i.e., absence of protective levels despite vaccination where defined
- Low switched memory B cells (<70 % of age-related normal value)

AND secondary causes of hypogammaglobulinemia have been excluded

AND diagnosis is established after the fourth year of life (but symptoms may be present before)

AND no evidence of profound T-cell deficiency, defined as two out of the following (y = year of life)

- CD4 numbers/ μ l: 2-6y <300, 6-12y <250, >12 y <200 % Naïve CD4: 2-6y <25 %, 6-16y <20 %, >16y <10 % T cell proliferation absent

RT PCR for COVID 19 and H1N1 was negative. On noncontrast CT of paranasal sinuses, pansinusitis was evident (Figure 1). Nasal endoscopy revealed bilateral grade 1 nasal polyposis and bilateral inferior turbinate hypertrophy. CECT chest showed patches of consolidation with air bronchogram and evidence of bilateral lower lobe bronchiectasis (Figure 2). Bronchoscopy washings were negative for malignancy. Ultrasound abdomen revealed moderate splenomegaly. Upper gastrointestinal endoscopy was normal. Fibroscan of liver was normal. On echocardiogram, mild pulmonary hypertension, mild tricuspid regurgitation and normal left ventricular systolic functions were present.

Flow cytometric immunophenotyping of lymphocyte subset revealed Normal NK lymphocytes, T lymphocytes and reduced proportion of B lymphocytes. Flow cytometric immunophenotyping for B cells subset revealed reduced proportion of switched memory B cells, normal proportion of naïve and unswitched memory cells, reduced percentage of CD19+ B cells and markedly reduced proportion of plasmablasts. Flow cytometric immunophenotyping for T lymphocyte subset revealed normal proportion of CD3+ T cells and CD4+ T cells. Increased proportion of CD8+ T cells and reduced CD4/CD8 ratio.

Table 2: Laboratory characteristics of the patient.

Parameter	Patient value
Haemoglobin (g/dl)	11.4
Total leukocyte count (cells/ μ l)	8.17
Platelet count(per mcl)	99,000
Mean corpuscular volume(fl)	75.7
Peripheral blood smear	N/N
Blood urea(mg/dl)	14
Serum creatinine(mg/dl)	0.5
Total bilirubin (mg/dl)	0.6
Direct bilirubin (mg/dl)	0.4
Total protein (g/dl)	5.4
Serum albumin(g/dl)	3.3
Serum globulin(g/dl)	1.7
AST/ALT(U/L)	35/104
Serum alkaline phosphatase IU	115
Serum sodium mEq/l	137
Serum potassium mEq/l	4
Serum total IgE (IU/ml)	<0.5
Aspergillus IgE(IU/ml)	1.06
IgA levels (normal: 63-484mg/dl)	< 25mg/dl
IgG levels (normal: 552-1631mg/dl)	<320mg/dl
IgM levels (normal:33-293mg/dl)	<5mg/dl
CD3+ T lymphocyte (normal:55-83 %)	88.3
CD19+ B lymphocyte (normal: 6-19%)	3.4
CD16+CD56+ NK lymphocytes (normal:7-13%%)	7.81
Naïve B cell (CD19+CD27+IgD+) (normal: 42.6-82.3% of CD 19+ cells)	81.7
Unswitched Memory B cells(CD19+CD27+IgD+) (normal: 7.4-32.5% of CD 19+ cells)	15.6
Switched memory B cell (CD19+CD27+IgD-) (normal: 6.5-29.1% of CD 19+ cells)	0.7
CD3+CD4+(T _H lymphocytes) (normal: 31-52%)	38.6% of CD3+lymphocytes
CD3+CD8+(T _C lymphocytes) (normal: 18-35%)	54.8% of CD3+lymphocytes
CD4+/CD8+ ratio (normal: 1-3.6)	0.7

Table 3: Showing infectious and non-infectious clinical manifestations and complications of COVID

Complication	Manifestation
Infectious	Otitis/sinusitis
	Pneumonia
	Empyema
	Bronchiectasis
	Arthritis
	Diarrhea
	Meningitis
	Septicemia and/or endocarditis
	Herpes zoster
	Invasive human papillomavirus infection or profuse warts
	H pylori infection

Serum galactomannan levels, procalcitonin, hemoglobin electrophoresis were normal. Antibody tests for human immunodeficiency virus, hepatitis B and C virus were negative. Serology tests for antineutrophilic cytoplasmic antibody (ANCA) C & P, antinuclear antibody, rheumatoid factor were negative.

Patient was treated with intravenous immunoglobulins (IVIg) 400mg/kg over 24 hours. Patient has received 4 doses of IVIg once in a month basis till May,2024.

In addition, patient was prescribed cotrimoxazole once a day for life. Since initiation of this regimen, the patient has required no further hospital admissions or antibiotic treatment, and has reported a significant improvement in quality of life. No change in the size of spleen was observed during followup.

Table 4: Showing infectious and non-infectious clinical manifestations and complications of COVID

Complication	Manifestation
Pulmonary	Asthma/obstructive lung disease Bronchiectasis Sarcoidosis-like disease Interstitial lung disease Neoplasia Pulmonary hypertension Granulomatous lymphocytic interstitial lung disease (GLILD)
Gastrointestina	Eosinophilic esophagitis Gastritis Inflammatory bowel disease Bacterial overgrowth Malabsorption syndrome Nodular lymphoid hyperplasia H pylori infection Neoplastic disease Malnutrition
Liver disease and spleen	Abnormal liver function tests Granulomas Nodular regenerative hyperplasia Cirrhosis and portal hypertension Primary biliary cholangitis Splenomegaly (massive splenomegaly in 30% cases) and hypersplenism
Autoimmunity	Hematological Cytopenias: immune thrombocytopenia, autoimmune hemolytic anemia Evans syndrome Autoimmune neutropenia Pernicious anemia
Rheumatological	Rheumatoid arthritis Sjogren’s syndrome Systemic lupus erythematosus; antiphospholipid syndrome Seronegative rheumatoid arthritis Juvenile rheumatoid arthritis Vasculitis
Gastrointestina	Atrophic gastritis Celiac disease Primary biliary cirrhosis Inflammatory bowel disease
Neurological	Guillain Barre syndrome
Endocrine	Hashimoto’s thyroiditis Type I diabetes mellitus Addison’s disease
Dermatological	Vitiligo, alopecia
Malignancy	Non-Hodgkin lymphoma, Hodgkin’s lymphoma Neuroendocrine tumours Gastric, cervical, breast, and bladder cancers Expansion of BALT and MALT
Skin and lymphoid tissue	Lymphoid hyperplasia Lymphadenopathy and cutaneous granulomas

3. Discussion

CVID is a rare syndrome, characterized by low serum levels of one or more immune globulin (Ig), recurrent sinopulmonary infections, susceptibility to various autoimmune diseases, prone to various malignancies, predominantly lymphoma and leukaemia, lymphocytic and granulomatous interstitial lung disease, nodular lymphoid hyperplasia of gut and splenomegaly.³ The European Society of Primary Immunodeficiency (ESID) Registry (2014) have proposed diagnostic criteria for CVID as given in Table 1. CVID is sporadic in most of the cases. It can be both autosomal dominant and rarely autosomal recessive. A family history is found in 10% of cases. Mutations in the inducible T-cell costimulatory (ICOS) gene, transmembrane activator calcium-modulating cyclophilin ligand interactor (TACI), nuclear factor kappa B subunit 1 (NF- κ B1), lipopolysaccharide (LPS)-responsive beige-like anchor protein (LRBA), cytotoxic T lymphocyte antigen 4 (CTLA4), B cell activating factor of the tumor necrosis family (BAFF) receptor (BAFF-R) have been reported commonly among CVID cohorts. are common/ have been reported in families. Rare cases of hypogammaglobulinemia have been found to be associated with CD19, CD20, CD21, and CD81 deficiencies.⁴

Most of the patients are diagnosed in late adulthood although clinical manifestations can occur earlier in life. Median delay from the first symptom of immunodeficiency to diagnosis has been reported from four to seven years in studies from developed countries.^{5,6} The clinical spectrum of CVID is broadly described as features related to infections and their complications and symptoms and signs of non-infectious complications. The spectrum of clinical manifestations and complications are described in Tables 3 and 4.

Histological lesions suggestive of diffuse parenchymal lung disease include granulomatous and lymphocytic interstitial lung disease. Histological lesions in small intestine biopsies demonstrate lesions like intraepithelial lymphocytosis, villous atrophy/blunting, nodular lymphoid hyperplasia, nonspecific inflammation and granulomas. Histological lesions in large intestine biopsies demonstrate lesions like nodular lymphoid hyperplasia, nonspecific inflammation and granulomas. Histological lesions in stomach biopsies show gastritis, gastropathy, lymphoid aggregates, metaplasia and granulomas. In addition to lung and gastrointestinal tract granuloma lesions have been found in liver, skin, lymph node, eye, brain, gastrointestinal tract, oral, parotid gland, soft tissue, spleen, bone marrow, kidney and mesentery.⁴

The goal of therapy in CVID is to prevent recurrent infections and subsequent long-term complications. Immunoglobulin replacement is the mainstay of the management. Both IVIG and subcutaneous immunoglobulins (SCIG) formulations have been used

successfully for decades for replacement therapy, but patients hospitalized with serious infections should preferably receive IVIG. The dose of IVIG is 400-600 mg/kg every 3-4 weekly and SCIG is 100 mg/kg every weekly. The role of immunoglobulin replacement therapy in the prevention of non-infectious complications is not clear. Non-infectious complications in CVID are therefore emerging as a major challenge, requiring a better understanding of underlying pathogenesis and additional therapeutics. Supportive management like rational antibiotic use, vaccination, nutrition, psychological health, physical activity, and good sleep physiology are the cornerstone of management. Treatment options for granulomatous lymphocytic interstitial lung disease (GLILD) have included immunoglobulin therapy, corticosteroids, and combinations of rituximab and azathioprine.⁷ Recurrent infections (more than three episodes per year), severe breakthrough infections, and declining lung function are indication for antimicrobial prophylaxis. The administration of live vaccinations should be avoided in CVID patients. The antibody response to inactivated vaccines may be poor. Hematopoietic stem cell transplantation has been used for treating complications associated with CVID. In India, ministry of Health and Family Welfare, Government of India launched a national policy for treatment of rare diseases (NPTRD) in 2021.⁸ There are limited centres for advanced research in India with clinical expertise and diagnostic facilities for primary immunodeficiency (PID). As a result, majority of patients with PIDs continue to remain undiagnosed. Access to advanced investigation is a major reason for the underdiagnosis of PID in resource limited settings. Clinicians in India need to suspect, investigate and make the diagnosis of CVID more frequently.

4. Conclusion

Clinicians in India should suspect CVID in patients with recurrent rhino sinusitis or pneumonia. Investigate suspected patients by evaluating serum immunoglobulin levels. Confirm diagnosis by flow cytometry.

5. Source of Funding

None.

6. Conflict of Interest

None.

References

1. Jindal AK, Pilania RK, Rawat A, Singh S. Primary Immunodeficiency Disorders in India—A Situational Review. *Front Immunol.* 2017;8:714. doi:10.3389/fimmu.2017.00714.
2. Seidel MG, Kindle G, Gathmann B, Quinti I, Buckland M, Montfrans J, et al. The European Society for Immuno-deficiencies (ESID) Registry working definitions for the clinical diagnosis of inborn errors

- of immunity. *J Allergy Clin Immunol Pract.* 2019;7(6):1763–70.
3. Saikia B, Gupta S. Common variable immunodeficiency. *Indian J Pediatr.* 2016;83:338–44. doi:10.1007/s12098-016-2038-x.
 4. Ho H, Cunningham-Rundles C. Non-infectious Complications of Common Variable Immunodeficiency: Updated Clinical Spectrum, Sequelae, and Insights to Pathogenesis. *Front Immunol.* 2020;11:149. doi:10.3389/fimmu.2020.00149.
 5. Oksenhendler E, Gerard L, Fieschi C, Malphettes M, Mouillot G, Jaussaud R, et al. Infections in 252 patients with common variable immunodeficiency. *Clin Infect Dis.* 2008;46(10):1547–54.
 6. Gathmann B, Mahlaoui N, Ceredih, Gérard L, Oksenhendler E, Warnatz K, et al. Clinical picture and treatment of 2212 patients with common variable immunodeficiency. *J Allergy Clin Immunol.* 2014;134(1):116–26.
 7. Gupta S, Pattanaik D, Krishnaswamy G. Common variable immunodeficiency and associated complications. *Chest.* 2019;156(3):579–93.
 8. National Policy of rare diases. [accessed May 1st, 2024]. Available from: https://rarediseases.mohfw.gov.in/uploads/Content/1624967837_Final-NPRD-2021.pdf.


Author biography

Tanya Thakur, Post Graduate Student

Korada Vivek Naidu, Post Graduate Student

Bikram Shah, Assistant Professor

Manoj Thakur, Assistant Professor

Sujeet Raina, Professor  <https://orcid.org/0000-0002-6333-2104>

Cite this article: Thakur T, Naidu KV, Shah B, Thakur M, Raina S. Common variable immunodeficiency- A delayed diagnosis of an underdiagnosed entity in resource limited setting. *IP Indian J Immunol Respir Med* 2024;9(2):79-84.