



Case Report

Think beyond TB lymphadenitis - Kikuchi fujimoto lymphadenitis

Aishwarya Alavandar^{1*}, Koushik Muthu Raja Mathivanan²

¹Sree Balaji Medical College and Hospital, Chennai, Tamil Nadu, India

²Sri Ramachandra Institute of Higher Education and Research, Chennai, Tamil Nadu, India



ARTICLE INFO

Article history:

Received 08-06-2024

Accepted 25-06-2024

Available online 10-07-2024

Keywords:

KikuchiFujimoto disease
Cervical lymphadenopathy
Tuberculous lymphadenitis

ABSTRACT

Kikuchi-Fujimoto disease (KFD) is an extremely unusual lymphadenopathy that typically affects females between the ages of 20 and 40, but the aetiology is still unclear. A 28-year-old female presented with right-sided cervical lymph nodes, but there was no history of fever, anorexia, or loss of appetite. Ultrasonography of the patient's neck revealed bilateral cervical lymphadenopathy. Both the acid-fast bacilli smear and GeneXpert tests returned negative results. Histopathology revealed the presence of lymphocytes and histiocytes mixed with karyorrhectic debris. Immunohistochemistry markers support the diagnosis of Kikuchi-Fujimoto lymphadenitis. This case demonstrates that early recognition of KFD reduces unnecessary evaluations and treatments and patient suffering.

Key messages: KFD is a self-limiting disease that requires a systematic approach for a diagnosis; once the diagnosis is made and confirmed by techniques such as immunohistochemistry, symptomatic treatment alone would suffice in the majority of cases. The commonest presentation is an acute or subacute febrile illness associated with cervical lymphadenopathy.

This is an Open Access (OA) journal, and articles are distributed under the terms of the [Creative Commons Attribution-NonCommercial-ShareAlike 4.0 License](https://creativecommons.org/licenses/by-nc-sa/4.0/), which allows others to remix, tweak, and build upon the work non-commercially, as long as appropriate credit is given and the new creations are licensed under the identical terms.

For reprints contact: reprint@ipinnovative.com

1. Introduction

Kikuchi and Fujimoto were the first to describe Kikuchi-Fujimoto disease (KFD) in Japan in 1972.¹ Lymphadenopathy, low-grade fever, and night sweats are common symptoms of this benign disease. The cervical lymph nodes are most commonly affected in young individuals, while other lymph nodes are affected less frequently.² Lymphoma, infections, and autoimmune diseases such as SLE, scleroderma, autoimmune hepatitis, and thyroiditis are frequent mimics in the clinic and laboratory. Lymph node histopathology is able to confirm the diagnosis of KFD.^{1,3,4} Early KFD recognition reduces unnecessary evaluations and treatments and reduces patient suffering, as shown in this case.

* Corresponding author.

E-mail address: aishwaryaalavandar@gmail.com (A. Alavandar).

2. Case Report

A 28-year-old female presented to the pulmonology outpatient department with right-sided cervical lymphadenopathy associated with pain over the swelling. There was no mention of any prior episodes of fever, anorexia, or loss of appetite. A family history of tuberculosis with parents present at the time of diagnosis. Antibiotics were administered for two weeks at a different hospital, but the patient's condition did not improve. On presentation, the patient was hemodynamically stable and afebrile, and vitals were within normal limits. Diffuse, 3 cm in size, right cervical lymphadenopathy was found on physical examination. The lymph nodes were hard and mobile, and they were matted. Left-side nodes were not palpable. Both the upper and lower respiratory tracts were examined, and both revealed no abnormalities. The examination of the other system was unremarkable. A complete blood

count was performed, which included total and differential leukocyte counts as well as an erythrocyte sedimentation rate (ESR). There was an increase in the inflammatory marker ESR as well as a rise in the lymphocyte percentage, which went up to 45% despite the absence of leucocytosis.

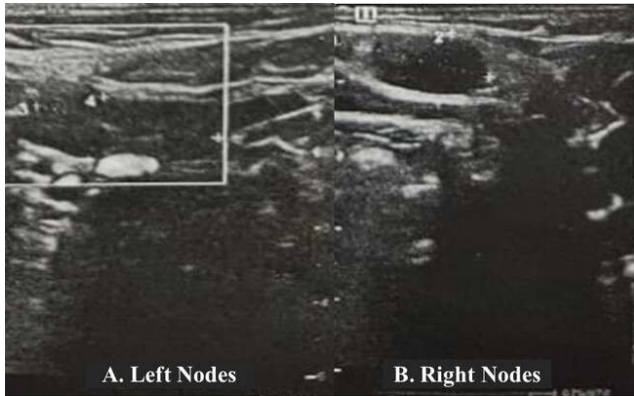


Figure 1: Ultrasonography of the neck revealed that the patient had bilateral cervical lymphadenopathy. The right level 5 nodes measured 2.5x1.0 cm, and the left level 4 node measured 1.9x0.8 cm.

Due to the high prevalence of tuberculosis in India, this patient underwent tuberculosis screening. Chest x-rays were normal. Both the Mantoux skin test and the interferon gamma assay were carried out. Both results were unfavourable. A FNAC from the right cervical node was performed to guarantee a tissue diagnosis, but the results were inconclusive. Both the AFB smear and the GeneXpert results came back negative. A surgical excision biopsy was performed to get an accurate diagnosis.

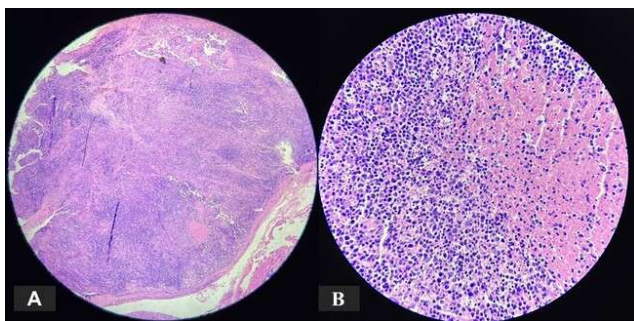


Figure 2: Histopathology showed that the lymph node's structure was partly broken down, and pieces of karyorrhectic debris were mixed in with lymphocytes and histiocytes. There was no sign of a granuloma; **A:** Histology of lymph node with effaced architecture (H&E x 100); **B:** High power showing necrosis and karyorrhectic debris (H&E x 400x)

Kikuchi lymphadenitis and lupus lymphadenitis were both possibilities in our differential diagnosis. No signs of growth were observed in the MGIT culture of the biopsy specimen. The immunohistochemistry markers CD3, CD68,

MPO, CD20, and CD45 were used to confirm the diagnosis. The results of the IHC came back positive, lending support to the diagnosis of Kikuchi-Fujimoto lymphadenitis. An opinion from a haematologist was obtained. The patient continues to receive routine checkups.

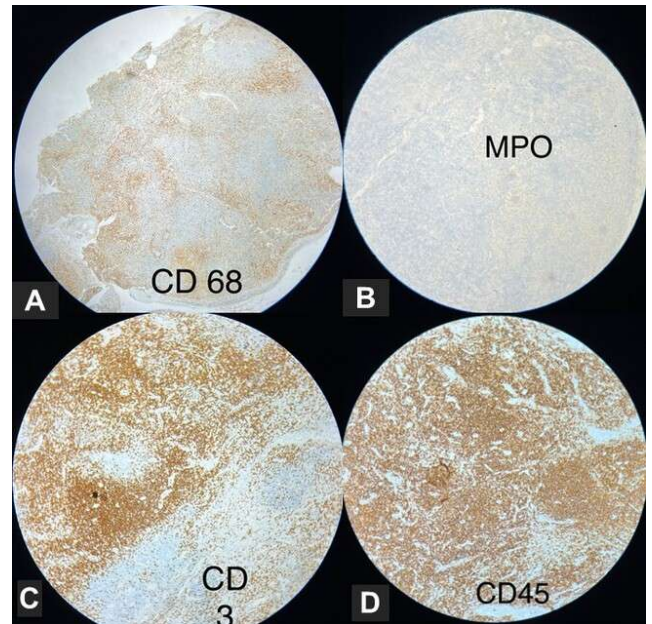


Figure 3: Immunohistochemical staining; **A:** Immunohistochemical staining for CD68 highlighting histiocytes (IHC x 100x); **B:** Immunohistochemical staining for MPO in karyorrhectic debris (IHC x 100x); **C:** Immunohistochemical staining for CD3 highlighting T cells (IHC x 100x); **D:** Immunohistochemical staining for CD45 highlighting lymphocytes (IHC x 100x)

3. Discussion

Kikuchi-Fujimoto disease is an extremely rare lymphadenopathy that typically affects females between the ages of 20 and 40 who are of Southeast Asian ancestry, but its cause is unknown.⁵ The majority of researchers think that viral infection plays a role in the pathogenesis of KFD and that it also mediates the auto-immune response.⁶ Epstein-Barr virus, human herpesvirus 6, human herpesvirus 8, human immunodeficiency virus (HIV), parvovirus B19, paramyxoviruses, and parainfluenza virus are just some of the viruses that have been hypothesised to play a role.⁷ Despite extensive research, no single pathogen has been isolated through either serological or molecular analysis.⁸ The onset of KFD is acute or subacute and develops over the course of two to three weeks. Unilateral cervical lymphadenopathy is the primary clinical feature of KFD. It is uncommon for other lymph node groups to be involved.⁹ Systemic symptoms associated with the disease include night sweats, rashes, and weight loss. Leukopenia,

neutropenia, an elevated lactate dehydrogenase level, transaminitis, and an elevated erythrocyte sedimentation rate are laboratory abnormalities.¹ Our female patient had bilateral cervical lymphedema and an elevated erythrocyte sedimentation rate for one month without any other symptoms.

Due to its similarity in presentation to lymphoma and other lymphoproliferative disorders, as well as other autoimmune diseases, KFD is often misdiagnosed.¹⁰ This is why a diagnosis of KFD cannot be made through non-invasive means alone; rather, invasive procedures such as excisional biopsy and immunohistochemistry are required.⁸ Due to the high degree of similarity between KFD and the above conditions, a comprehensive workup and in-depth investigations are required to make a diagnosis.¹⁰

A definitive diagnosis of KFD necessitates a lymph node biopsy and immunohistochemistry. Myeloperoxidases, CD68+, CD128+, plasmacytoid dendritic cells, or activated CD8+ T lymphocytes are common. A biopsy shows paracortical areas of coagulative necrosis with karyorrhectic debris that changes the nodal architecture.¹¹ Lack of Reed-Sternberg (RD) cells and the presence of a granulomatous infection set KFD apart from lupus, tuberculosis, and Hodgkin's lymphoma. There are many atypical reactive histiocytes and a low mitotic rate, and the nodal architecture is only partially destroyed, leaving the sinuses open.¹¹ Our patient's lymph node had partially disintegrated, and histopathology revealed a mingling of lymphocytes and histiocytes with fragments of karyorrhectic debris.

Immunohistochemistry helped confirm the diagnosis in the present instance. The histological features and immunostaining study confirmed the necrotizing form of KFD and ruled out lymphoma. KFD is typically treated symptomatically because it resolves on its own within a few days to weeks, even without medication, with the exception of steroid use, which has been indicated only in cases that have proven resistant to other treatments.¹²

KFD is a self-limiting disease that needs a careful and systematic approach for a diagnosis; once the diagnosis is made and confirmed by immunohistochemistry techniques, symptomatic treatment alone would suffice in most cases, with a few needing low-dose steroid therapy.²

4. Conclusion

This article describes the clinical manifestations of cervical lymphadenopathy in a female patient. Kikuchi-Fujimoto disease is a benign condition that, due to its symptoms, is often misdiagnosed as something more serious. Some clinical and pathologic features of KFD are shared with those of lupus lymphadenitis. Similar symptoms present in both diseases can make diagnosis challenging. It is of the utmost importance to recognize the disease in its earliest stages if one is interested in reducing the number

of potentially harmful and unnecessary evaluations and treatments.

5. Declaration of Patient Consent

The authors certify that they have obtained all appropriate patient consent forms. In this form, the patient(s) has/have given his/her/their consent for his/her/their images and other clinical information to be reported in the journal. The patients understand that their names and initials will not be published, and due efforts will be made to conceal their identity, but anonymity cannot be guaranteed.

6. Source of Funding

None.


7. Conflicts of Interest

There are no conflicts of interest.

References

- Harrison J, Sukumaran S, Vijayan V, Harrison J, Sukumaran S, Vijayan V, et al. Systemic Lupus Erythematosus Lymphadenopathy Presenting as Kikuchi-Fujimoto Disease in an Adolescent. *Cureus*. 2023;15(2):e35304. doi:10.7759/cureus.35304.
- Vijayaraghavan R, Chandrashekar R, Saraswathi A, Belagavi CS. Kikuchi-Fujimoto's disease involving mesenteric nodes: a report and review of literature. *BMJ Case Rep*. 2011;p. 1020114945. doi:10.1136/bcr.10.2011.4945.
- Kim TY, Ha KS, Kim Y, Lee J, Lee K, Lee J, et al. Characteristics of Kikuchi-Fujimoto disease in children compared with adults. *Eur J Pediatr*. 2014;173(1):111–6.
- Sopeña B, Rivera A, Vázquez-Triñanes C, Fluiters E, González-Carrero J, Pozo MD, et al. Autoimmune Manifestations of Kikuchi Disease. *Semin Arthritis Rheum*. 2012;41(6):900–6.
- Sharma K, Otieno F, Shah R. Case Report of Kikuchi-Fujimoto Disease from Sub-Saharan Africa: An Important Mimic of Tuberculous Lymphadenitis. *Case Rep Med*. 2020;p. 4385286. doi:10.1155/2020/4385286.
- Song Y, Liu S, Song L, Chen H, Bai M, Yan J, et al. Case Report: Histiocytic Necrotizing Lymphadenitis (Kikuchi-Fujimoto Disease) Concurrent With Aseptic Meningitis. *Front Neurol*. 2021;12:565387. doi:10.3389/fneur.2021.565387.
- Kubota M, Tsukamoto R, Kurokawa K, Imai T, Furusho K. Elevated serum interferon γ and interleukin-6 in patients with necrotizing lymphadenitis (Kikuchi's disease). *Br J Haematol*. 1996;95(4):613–5.
- Sarfraz S, Rafique H, Ali H, Hassan SZ. Case Report: Kikuchi-Fujimoto Disease: A case of supraclavicular lymphadenopathy. *F1000Res*. 2021;8:1652. doi:10.12688/f1000research.19981.2.
- Dalugama C, Gawarammana IB. Fever with lymphadenopathy - Kikuchi Fujimoto disease, a great masquerader: a case report. *J Med Case Rep*. 2017;11(1):349. doi:10.1186/s13256-017-1521-y.
- Khan AM, Ahmad M, Muhammad O, Taj S, Shiza ST, Khan AM, et al. Kikuchi-Fujimoto Disease in a Young Female: A Case Report and Literature Review. *Cureus*. 2021;13(11):e19321. doi:10.7759/cureus.19321.
- Bosch X, Guilabert A, Miquel R, Campo E. Enigmatic Kikuchi-Fujimoto disease: a comprehensive review. *Am J Clin Pathol*. 2004;122(1):141–52.
- Perry AM, Choi SM. Kikuchi-Fujimoto Disease: A Review. *Arch Pathol Lab Med*. 2018;142(11):1341–6.

Author biography

Aishwarya Alavandar, Senior Resident  <https://orcid.org/0009-0002-1710-6787>

Koushik Muthu Raja Mathivanan, Professor

Cite this article: Alavandar A, Mathivanan KMR. Think beyond TB lymphadenitis - Kikuchi fujimoto lymphadenitis. *IP Indian J Immunol Respir Med* 2024;9(2):71-74.