

Content available at: <https://www.ipinnovative.com/open-access-journals>

IP Indian Journal of Immunology and Respiratory Medicine

Journal homepage: <https://www.ijirm.org/>

Original Research Article

Cytomegalovirus and Epstein-Barr virus infections in pediatric patients of choledochal cyst

Anil Kumar Ram¹, Prema Menon², Ravi Prakash Kanojia², Alka Bhatia³,
Ranjana Walker Minz⁴, Yashwant Kumar⁴*¹Dept. of Pathology & Laboratory Medicine, University of Kansas Medical Center, Kansas, USA²Dept. of Pediatric Surgery, Post Graduate Institute of Medical Education & Research, Chandigarh, India³Dept. of Experimental Medicine and Biotechnology, Post Graduate Institute of Medical Education & Research, Chandigarh, India⁴Dept. of Immunopathology, Post Graduate Institute of Medical Education & Research, Chandigarh, India

ARTICLE INFO

Article history:

Received 05-06-2024

Accepted 25-06-2024

Available online 10-07-2024

Keywords:

Choledochal cyst

Cholelithiasis

Cytomegalovirus

Epstein Barr Virus

ABSTRACT

Objectives: Association of viral infection with obstructive jaundice is well-known however frequency of cholangiotropic virus infection in pediatric choledochal cyst is not known.**Materials and Methods:** IgG and IgM antibodies against Cytomegalo virus (CMV) and Epstein Barr virus (EBV) in 48 children with choledochal cysts and 26 controls were analysed using ELISA.**Results:** We found significantly higher anti-CMV IgG and IgM in patients (95.8% and 77.1%, respectively) compared to controls (73.1% and 42.3%) and a notable prevalence of anti-EBV antibodies among both groups (83.3% versus 65.4% IgG and 77.1% versus 46.1 for IgM in patients and controls respectively). Moreover, 79.2% of patients were positive for both anti-CMV and anti-EBV IgG, and 62.5% for both IgMs.**Conclusion:** This pilot study suggests that infection with CMV, EBV, or both is frequently seen in pediatric patients with CDC. Molecular screening and follow-up in a larger cohort is therefore required for further validation.This is an Open Access (OA) journal, and articles are distributed under the terms of the [Creative Commons Attribution-NonCommercial-ShareAlike 4.0 License](https://creativecommons.org/licenses/by-nc-sa/4.0/), which allows others to remix, tweak, and build upon the work non-commercially, as long as appropriate credit is given and the new creations are licensed under the identical terms.For reprints contact: reprint@ipinnovative.com

1. Introduction

A choledochal cyst (CDC) is a rare disorder with cystic dilatation of the biliary system due to unknown etiology. It may remain asymptomatic or may present with chronic or intermittent abdominal pain or with biliary cirrhosis.¹ Sometimes complications may occur in the form of recurrent jaundice, cholangitis, pancreatitis, biliary stones, perforation of the common bile duct, right upper quadrant mass, and malignant transformation of the cyst.²⁻⁴ About 80% of CDC cases are detected in preschool children or teenager. Radio imaging (i.e., abdominal

ultrasound, endoscopic ultrasound, computed tomography, magnetic resonance cholangiopancreatography, and endoscopic retrograde cholangiopancreatography) and lab investigations (i.e., abnormal liver enzymes and increased level of biliary amylase) are required to diagnose CDC.^{2,5} The most widely accepted surgical treatment is cyst excision with Roux-en-Y hepaticoenterostomy or hepaticoduodenostomy.^{6,7} Despite a good post-surgery prognosis, patients need lifelong follow-up because of the increased risk of cholangiocarcinoma.⁷⁻¹⁰ It has been observed that cholangiotropic viruses instigate the inflammatory process, which leads to pediatric obstructive cholangiopathies and poor consequences.¹¹ Therefore, this

* Corresponding author.

E-mail address: dryashwant@gmail.com (Y. Kumar).

study aimed to detect the seroprevalence of the most potent cholangiotropic viruses like CMV and EBV among CDC pediatric patients.

2. Materials and Methods

2.1. Requirement of study subjects

In this single-center, prospective, case-control study 48 patients with CDC and 26 age-matched controls (14 children with cholelithiasis and 12 (9 hypospadias and 3 hernia) with minor surgical corrections were recruited. The CDC patients were included after a confirmation of diagnosis which was based on clinical, radiological, and laboratory findings. The exclusion criteria were: cases of neonatal cholestasis i.e., neonatal hepatitis, α -1 antitrypsin deficiency; haemolysed blood samples; and guardians unwilling their child to participate in the study. The power analysis of sample size for the study was carried out

using following calculation:
$$N = \frac{p_0q_0 \left(\left(z_{1-\alpha/2} + z_{1-\beta} \sqrt{\frac{p_1q_1}{p_0q_0}} \right)^2 \right)}{(p_1 - p_0)^2}$$

where p_0 is proportion of population/control group; p_1 is proportion of study group; q_0 is $1-p_0$; q_1 is $1-p_1$; α is probability of type I error, β is probability of type II error; z is critical Z value for a given α or β ; and N is the desired minimum sample size. The $N = \frac{0.1 \times 0.9 \left(\left(1.96 + 0.84 \sqrt{\frac{0.25 \times 0.75}{0.1 \times 0.9}} \right)^2 \right)}{(0.25 - 0.1)^2} = 40$ The study commenced after approval from Institute Human Ethics Committee as per the provisions of the Declaration of Helsinki. Written informed consent was also obtained from parents/guardians of both patients and control subjects.

2.2. Sample collection and processing

About 2ml of plain blood sample was collected just before surgery. The serum was separated after centrifugation at 2000g for 10 minutes at 4 °C, aliquoted in 500 μ l, and stored at -80°C until further use. Commercially available ELISA kits were used for the detection of antiviral IgG and IgM of CMV (Cat # CM027G and Cat # CM028M Calbiotech, USA) and EBV (Cat # EV010G and Cat # EV012M, Calbiotech, USA) in serum samples of study subjects and assays were carried out as per the instructions from the manufacturer. Antigen-coated strips were used with diluted serum samples, incubated for 60-90 minutes. Following incubation, the strips were washed and enzyme conjugate added, with another incubation of 30-60 minutes. After washing off excess conjugate, substrate solution was introduced and incubated for 10 minutes at 37°C. A stop solution halted the reaction before reading the optical density (OD) at 450 nm. Results interpretation was based on the cut-off value: >1.1 indicated positive, <0.9 negative, and 0.9 - 1.1 equivocal positivity.

2.3. Statistical analysis

The comparison of ODs or antibody index of antiviral IgG and IgM among the study subjects was analyzed by nonparametric statistical test, Mann-Whitney U test, and the data were presented in the graph as mean with standard error of the mean. Fisher's exact test analyzed the virus infection positivity, and the graph demonstrated the percentage positivity. The p-value was calculated at 0.05.

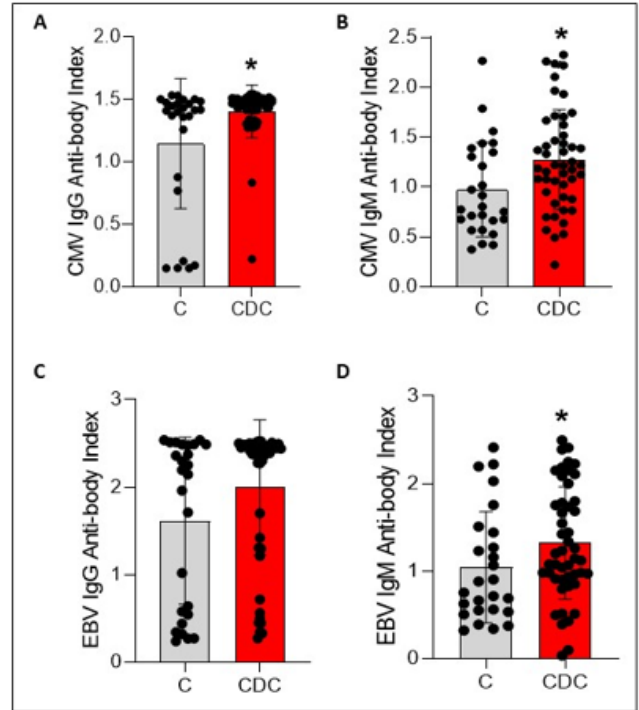


Figure 1: Viral antigen and antiviral antibody titers for CMV and EBV in serum of CDC patients versus controls; **A:** Anti-CMV IgG; **B:** anti-CMV IgM; **C:** Anti-EBV IgG; **D:** and anti-EBV IgM. (Mann-Whitney U test used for the analysis of antibody and Ag ODs. P-value was calculated at 0.05).

3. Results

3.1. Characteristics of study groups

In the patient group, 58.3% (28/48) and 41.7% (20/48) were females and males, respectively. The mean ages of the patients were 59.2 months (ranging from 14 to 148 months). Among the controls, 69.2% (18/26) were males and 30.8% (8/26) were females with age ranging from 27-132 months (mean age 66.5 months).

3.2. Viral infection

In the patient group, 83.3% (46/48) were positive for anti-CMV IgG and 77.0% (37/48) for anti-CMV IgM. In contrast, 73.0% (19/26) controls showed anti-CMV IgG and

Table 1: Antiviral IgG and IgM positivity for CMV and EBV infections.

Virus	Antibodies tested	Positivity in patients(in %) n = 48	Positivity in controls(in %) n = 26	p -value (Fisher's Exact Test)
CMV	IgG	95.8	73.0	0.0074
	IgM	77.0	42.3	0.0046
	IgG + IgM	70.8	30.8	0.0013
EBV	IgG	83.3	65.4	0.0916
	IgM	77.0	46.1	0.0103
	IgG + IgM	83.3	26.9	<0.0001
CMV+EBV	IgG	79.2	50.0	0.0169
	IgM	62.5	34.6	0.0290
	IgG + IgM	47.9	15.4	0.0060

42.3% (11/26) anti-CMV IgM in their blood. Compared to controls more CDC patients showed positivity for both anti-CMV antibodies, i.e., IgG and IgM. Compared to controls, the antiviral IgG and IgM levels against CMV were significantly higher in patients with p-values of 0.031 and 0.013, respectively. However, the percentage positivity of anti-CMV IgG and anti-CMV IgM was non-significant. Also, 83.3% (40/48) patients were positive for anti-EBV IgG and 77.0% (37/48) for anti-EBV IgM. The percentage positivity was much higher in patients compared to controls. Almost 48% of patients and 15% of controls were positive for both anti-EBV IgG and IgM. Even though the difference in anti-EBV IgM levels in patients was significantly higher than in controls ($p = 0.0442$), the percentage positivity of anti-EBV IgG or anti-EBV IgM was not statistically significant. Serological analysis revealed that though the exposure to viruses was quite common in both the study subjects, the number of diseased patients and controls with active infection by CMV and EBV remained lesser. We noticed that 77.0% (37/48) and 47.9% (23/48) of CDC patients were positive for anti-IgG and anti-IgM of both CMV and EBV, respectively. While in the control group, 30.8% (8/26) and 15.4% (4/26) of children were positive for anti-IgG and anti-IgM of both viruses. The Figure 1 and Table 1 give the overall serological findings and statistical association for each virus infection.

4. Discussion

This pilot study is unique, representing the only research endeavor to evaluate the serological prevalence of CMV and EBV among CDC patients. These viruses are ubiquitous human herpesviruses, frequently leading to asymptomatic primary infections or manifesting as infectious mononucleosis syndrome. Their infection generally occurs in individuals of infantile age, in particular those with poor hygienic standards or low socioeconomic position. In general, 80% to 90% of young individuals infected with EBV become carriers of the infection in their 3rd decade of life. The seroprevalence rates of earlier CMV infection progressively increase with age and range between 40% and 100% in the adult population. CMV and EBV can

remain as lifelong latent infections and laterally reactivate in an immune-compromised state of the individuals.¹² Our findings demonstrate that the seroprevalence of CMV and EBV was the most frequent viral infection among the study subjects. The antiviral IgG and IgM antibody levels for both CMV and EBV were significantly increased in CDC than controls. We also observed that the percentage positivity of CMV and EBV exposure (IgG+) or active infection (IgM+) were higher in CDC than in controls but did not achieve a statistically significant value. These findings suggest that CMV and EBV infections are common in this study group, with higher antiviral immune activity in CDC patients than controls. Chronic illness or immune-compromised conditions might be responsible for breaking latency or acquiring environmental/hospital exposure to CMV and EBV, ultimately leading to the higher titer of IgG and IgM in CDC patients. Recently, a case report on co-infection of CDC with EBV infection reported that positive EBV infections unmasked the underlying choledochal cyst, which was previously asymptomatic.¹³ In our country, there is scanty data on the incidence of CDC and their association with CMV and EBV.^{14–17} A few studies reported that CMV and EBV infections or their co-infections are associated with a variety of liver disorders like acute or chronic hepatitis and hematological malignancies and increase the disease severity as well as their poor prognosis and morbidity.^{12,18,19} In our study, a higher frequency of these antiviral antibodies of CMV and EBV or both viruses before surgery may alter disease severity before or after surgery.

5. Conclusion

This preliminary study indicates that infections with CMV, EBV, or both are commonly observed in pediatric patients diagnosed with CDC. Consequently, molecular screening and extended follow-up in a broader patient cohort are essential for further validation and understanding of these associations.

6. Source of Funding

None.

7. Conflict of Interest

None.

References

- Lipsett PA, Pitt HA, Colombani PM, Boitnott JK, Cameron JL. Choledochal Cyst Disease: A Changing Pattern of Presentation. *Ann Surg.* 1994;220(5):644–52.
- Aggarwal S, Kumar A, Roy S, Bandhu S. Massive dilatation of the common bile duct resembling a choledochal cyst. *Trop Gastroenterol.* 2001;22(4):219–20.
- Soares KC, Arnaoutakis DJ, Kamel I, Rastegar N, Anders R, Maithele S, et al. Choledochal Cysts: Presentation, Clinical Differentiation, and Management. *J Am Coll Surg.* 2014;219(6):1167–80.
- Singh S, Kheria L, Puri S, Puri A, Agarwal A. Choledochal cyst with large stone cast and portal hypertension. *Hepatobiliary Pancreat Dis Int.* 2009;8(6):647–9.
- Cha SW, Park MS, Kim KW, Byun JH, Yu JS, Kim MJ, et al. Choledochal cyst and anomalous pancreaticobiliary ductal union in adults: Radiological spectrum and complications. *J Comput Assist Tomogr.* 2008;32(1):17–22.
- Silva-Baez H, Coello-Ramírez P, Ixtabalán-Escalante EM, Sotelo-Anaya E, Gallo-Morales M, Cordero-Estrada E, et al. Treatment of choledochal cyst in a pediatric population. A single institution experience of 15 years. Case series. *Ann Med Surg (Lond).* 2016;5:81–5. doi:10.1016/j.amsu.2015.12.054.
- Tadokoro H, Takase M. Recent advances in choledochal cysts. *Open J Gastroenterol.* 2012;2(4):145–54.
- Voyles RC, Smadja C, Shands C, Blumgart L. Carcinoma in Choledochal Cysts : Age-Related Incidence. *Arch Surg.* 1983;118(8):986–88.
- Gezer HÖ. Pediatric Choledochal Cysts: Unknowns are Decreasing. In: Shehata S, editor. *Pediatric Surgery, Flowcharts, and Clinical Algorithms.* London: IntechOpen; 2019. p. 1–27.
- Soares KC, Kim Y, Spolverato G, Maithele S, Bauer TW, Marques H, et al. Presentation and Clinical Outcomes of Choledochal Cysts in Children and Adults: A Multi-institutional Analysis. *JAMA Surg.* 2015;150(6):577–84.
- Enneth LTK, Sokol RJ, Oberhaus SM, Le M, Karrer FM, Narkewicz MR. Detection of Reovirus RNA in Hepatobiliary Tissues From Patients With Extrahepatic Biliary Atresia and Choledochal Cysts. *Hepatology.* 1998;27(6):1475–82.
- Bunchorntavakul C, Reddy KR. Epstein-Barr Virus and Cytomegalovirus Infections of the Liver. *Gastroenterol Clin North Am.* 2020;49(2):331–46.
- El-Khatib H, Kawtharany B, Mohammad D, Siblini M, El-Rifai N. EBV Infection Unmasking a Choledochal Cyst in an Infant. *Case Rep Pediatr.* 2019;p. 7320109. doi:10.1155/2019/7320109.
- Poddar U, Thapa BR, Chhabra M, Rao KLN, Mitra SK, Dilawari JB, et al. Choledochal cysts in infants and children. *Indian Pediatr.* 1998;35(7):613–8.
- James A, Karunakaran P, Eswaran R, Venkateswaran A. A study of symptomatic choledochal cyst in South India. *Int Arch Integr Med.* 2018;5(6):1–4.
- Kumar S, Chandra A, Chopra N, Rahul, Gupta V, Joshi P, et al. A Single-Center Experience with 73 Patients of Adult Choledochal Cyst: An Indian Perspective. *Trop Gastroenterol.* 2018;39(3):117–76.
- Srinivasan PH, Anbalagan A, Shanmugasundaram R, Lakshmanamoorthy NO. Management of Choledochal Cysts at a Tertiary Care Centre: A Nine-Year Experience from India. *Surg Res Pract.* 2020;p. 1–8. doi:10.1155/2020/8017460.
- Silva JDM, Pinheiro-Silva R, Dhyani A, Pontes GS. Cytomegalovirus and Epstein-Barr Infections: Prevalence and Impact on Patients with Hematological Diseases. *Biomed Res Int.* 2020;p. 1627824. doi:10.1155/2020/1627824.
- Hu J, Zhao H, Lou D, Gao H, Yang M, Zhang X, et al. Human cytomegalovirus and Epstein-Barr virus infections, risk factors, and their influence on the liver function of patients with acute-on-chronic liver failure. *BMC Infect Dis.* 2018;18(1):577. doi:10.1186/s12879-018-3488-8.

Author biography

Anil Kumar Ram, Post Doctoral Fellow

Prema Menon, Professor

Ravi Prakash Kanojia, Professor

Alka Bhatia, Professor

Ranjana Walker Minz, Professor and Head

Yashwant Kumar, Professor

Cite this article: Ram AK, Menon P, Kanojia RP, Bhatia A, Minz RW, Kumar Y. Cytomegalovirus and Epstein-Barr virus infections in pediatric patients of choledochal cyst. *IP Indian J Immunol Respir Med* 2024;9(2):58-61.