

Content available at: <https://www.ipinnovative.com/open-access-journals>

IP Indian Journal of Immunology and Respiratory Medicine

Journal homepage: <https://www.ijirm.org/>

## Case Report

# Tracheobronchopathia osteochondroplastica: Case report of a rare cause for a common symptom

Supriya Adiody<sup>1\*</sup>, Krishnanand Krishnakumar<sup>1</sup>, Sruthi Raghunath<sup>1</sup>, Aravind Thayyil Raman<sup>1</sup>

<sup>1</sup>Dept. of Pulmonary Medicine, Jubilee Mission Medical College, Kerala University of Health Sciences, Thrissur, Kerala, India



### ARTICLE INFO

#### Article history:

Received 20-03-2024

Accepted 12-04-2024

Available online 25-04-2024

#### Keywords:

Tuberculosis

Fibre optic bronchoscopy

Nodular trachea

Tracheobronchopathia

osteochondroplastica

### ABSTRACT

Tracheobronchopathia osteochondroplastica is a rare disease which is characterised by the presence of osseous and/or cartilaginous submucosal nodules projecting into the anterior and lateral walls of the airways. We present the case of a 56-year-old male presenting with chronic cough, dyspnoea and haemoptysis. An initial diagnosis of tuberculosis was kept in mind considering the endemicity of the disease. A fibre optic bronchoscopy, however helped in clinching the diagnosis. As there are no guidelines for the treatment, conservative treatment with inhaled steroids, bronchodilators, antibiotics, and avoidance of the airway irritants, is sufficient for the patient. On follow up after 2 months patient is doing fine with symptomatic improvement.

This is an Open Access (OA) journal, and articles are distributed under the terms of the [Creative Commons Attribution-NonCommercial-ShareAlike 4.0 License](https://creativecommons.org/licenses/by-nc-sa/4.0/), which allows others to remix, tweak, and build upon the work non-commercially, as long as appropriate credit is given and the new creations are licensed under the identical terms.

For reprints contact: [reprint@ipinnovative.com](mailto:reprint@ipinnovative.com)

## 1. Introduction

Tracheobronchopathia osteochondroplastica (TBPO) is an uncommon benign disease, of unknown aetiology, characterized by presence of multiple sessile, bony or cartilaginous, submucosal nodules extending selectively from the anterolateral walls of the tracheobronchial tree and sparing the posterior wall.<sup>1</sup> The exact pathophysiology of TBPO still remains a mystery. The origin of the nodules seen in TBPO is postulated to be from metaplasia of the submucosal connective tissue or ecchondrosis and exostosis of tracheal cartilage originating from a tracheal ring.<sup>2-4</sup>

Some other proposed aetiologies include metabolic abnormalities, ageing related degenerative processes, amyloidosis, malignancy, inheritance, silicosis, chronic irritation, and infection, but these hypotheses lack significant evidence. TBPO presents with variable clinical features with no specific guidelines on the management of

the disease. Diagnosis is often an incidental finding during a bronchoscopy, difficult intubation or an autopsy.

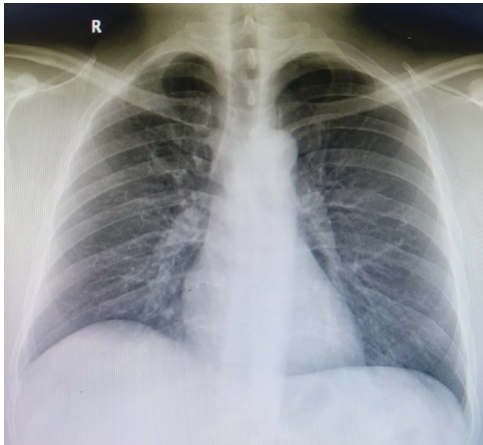
## 2. Case History

We report the case of a 56-year-old male who reported to our department with a 1-month history of dry cough, exertional dyspnoea and occasional haemoptysis with undocumented weight loss. He was a smoker with no past history of Tuberculosis. On examination, vitals were stable, pulse rate of 78/min, BP:130/70 Mm of Hg, Spo2 of 98% on room air. Examination of the Respiratory system revealed coarse crepitations in the right infra scapular area. Other systems were normal on examination. Chest Xray (Figure 1) showed increased broncho vascular markings and CT scan showed (Figure 2) irregular calcifications and small nodules projecting in to tracheal lumen sparing the posterior tracheal wall and also showed centrilobular ground glass density nodules in right lower lobe and left upper lobe. As TB is endemic to our country, we first considered it as our working

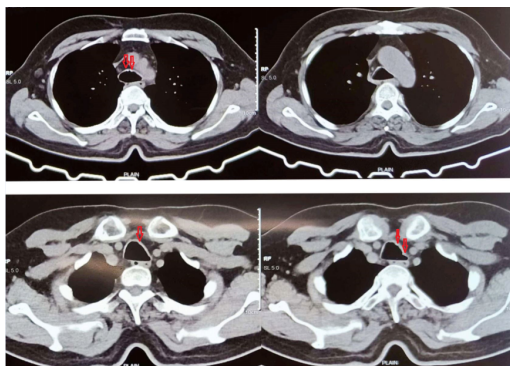
\* Corresponding author.

E-mail address: [adiodysupriya337@gmail.com](mailto:adiodysupriya337@gmail.com) (S. Adiody).

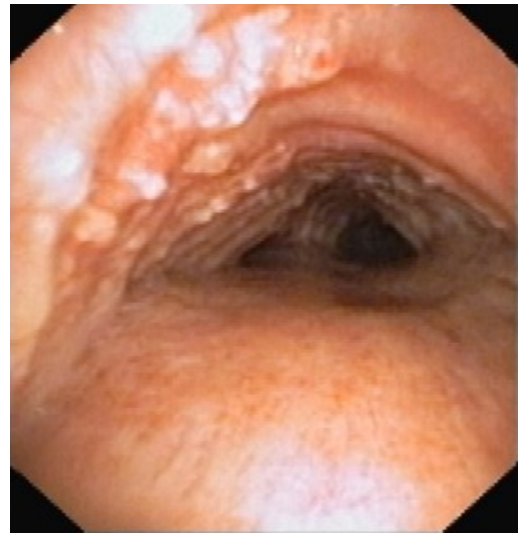
diagnosis. Other differentials like ILD, malignancy were also entertained. However, sputum AFB was negative. ANA profile, C ANCA, S. ACE levels were normal. As CT chest showed consolidation, we subjected him to a fibre optic bronchoscopy which revealed caving of the trachea with multiple nodules involving the anterolateral walls, almost giving it a cobblestoned appearance. The posterior wall was spared (Figure 3). BAL taken from right lower lobe and left upper lobe was sent for gram stain, culture, cytology and CBNAAT for AFB of which all were negative. Bronchial brushings were taken from the trachea as we could not take a biopsy owing to the hard and gritty nature of the lesions. Brushings turned out to be negative for malignancy. Patient was given conservative treatment with inhaled salmeterol and fluticasone metered dose inhaler (50/250ug) which the patient still continues, oral Cefpodoxime and N acetyl cysteine for a week. Patient is on regular follow up and after 2 months of conservative management patient is doing fine with symptomatic improvement.



**Figure 1:** Chest X-ray showing increased broncho vascular markings



**Figure 2:** CT chest showing irregular calcifications and small nodules projecting in to tracheal lumen (red arrow) sparing the posterior tracheal wall



**Figure 3:** Fibre optic bronchoscopy showing nodular anterolateral wall of trachea sparing the posterior wall

### 3. Discussion

TBPO is a rare, benign disease of unknown aetiology. Clinical manifestations of TBPO in patients are diverse, variable and nonspecific where most present with chronic cough and dyspnoea. Occasionally, haemoptysis can also be the presenting complaint. Clinical presentation can vary depending upon the extent of involvement of the tracheobronchial tree. Chest CT scans reported by an experienced radiologist may assist in demonstrating the submucosal calcified nodules, which can help in suspecting a diagnosis of TBPO.

The characteristic bronchoscopic findings are described as a stalactite cave, rock-garden, or cobble-stoned appearance.<sup>5,6</sup> It is reported that biopsies of airway luminal nodules are not usually necessary for the diagnosis of TBPO because the bronchoscopic appearance itself is typical.<sup>7</sup> Indeed, obtaining biopsies of TBPO lesions are usually difficult because of the hardness of the lesions.<sup>8</sup> In our patient, we could not obtain a biopsy because of the gritty nature of the lesions. We managed to take brushings from the lesion which showed chronic inflammation without any malignant features.

There are 3 categories of lesions on bronchoscopy according to the extent of the nodular disease in the mucosa -1) Scattered disease (few nodules with large areas of normal mucosa between them); 2) diffuse disease (numerous nodules covering the entire mucosa, no areas of normal mucosa; and 3) confluent disease (fusion of adjacent lesions). The confluent disease leads to severe respiratory compromise resulting from mechanical obstruction.

There are still no guidelines for the treatment and follow-up management of the disorder. Conservative treatment including inhaler steroids,<sup>9</sup> bronchodilators,

antibiotics, glucocorticoids and avoidance of the airway irritants, is usually sufficient. Patients with severe airway obstruction may require treatment such as bronchoscopic excision of the nodules, laser ablation, surgical resection and radiotherapy.<sup>7,10</sup>

#### 4. Conclusion

Diagnosis of TBPO can be difficult because of its rarity and hence clinicians should be aware of this benign disease. Bronchoscopic appearance is quite characteristic and almost pathognomonic of the disease as was in our case. Being able to characterise the lesions on CT may also help in clinching the diagnosis. BAL to rule out infectious, malignant aetiology may be done. Role of biopsy in diagnosis is controversial as it may be difficult because of the nature of the lesions but wherever feasible should be considered.

#### 5. Abbreviation

TBPO- Tracheo Broncho Pathia Osteochondroplastica; CT- Computerised Tomography; ANA- Antinuclear Antibody; ANCA- Anti Neutrophilic Cytoplasmic Antibody; S.ACE- Serum Angiotensin Converting Enzyme; BAL- Bronchio Alveolar Lavage; CBNAAT- Catridge Based Nucleic Acid Amplification Test; AFB- Acid Fast Bacilli

#### 6. Source of Funding

None.

#### 7. Conflict of Interest

None.

#### References

1. Barthwal MS, Chatterji RS, Mehta A. Tracheobronchopathia osteochondroplastica. *Indian J Chest Dis Allied Sci.* 2004;46(1):43–6.

2. Martin CJ. Tracheobronchopathia osteochondroplastica. *Arch Otolaryngol.* 1960;100(4):290–3.

3. Jindal S, Nath A, Neyaz Z, Jaiswal S. Tracheobronchopathia osteochondroplastica—a rare or an overlooked entity? *J Radiol Case Rep.* 2013;7(3):16–25.

4. Pounder DJ, Pieterse AS. Tracheopathia osteoplastica: A study of the minimal lesion. *J Pathol.* 1982;138(3):235–9.

5. Prakash UB, McCullough AE, Edell ES, Nienhuis DM. Tracheopathia osteoplastica: familial occurrence. *Mayo Clin Proc.* 1989;64(9):1091–6.

6. Doshi H, Thankachen R, Philip MA, Kurien S, Shukla V, Korula RJ, et al. Tracheobronchopathia osteochondroplastica presenting as an isolated nodule in the right upper lobe bronchus with upper lobe collapse. *J Thorac Cardiovasc Surg.* 2005;130(3):901–2.

7. Kırbaç G, Dağlı CE, Tanrikulu AÇ, Yıldız F, Bükte Y, Şenyiğit A, et al. Unusual Combination of Tracheobronchopathia Osteochondroplastica and AA Amyloidosis. *Yonsei Med J.* 2009;50(5):721–4.


8. Leske V, Lazor R, Coetmeur D, Crestani B, Chatté G, Cordier JF, et al. Tracheobronchopathia osteochondroplastica: a study of 41 patients. *Medicine (Baltimore).* 2001;80(6):378–90.

9. Xie BS, Chen YS, Yue WX. Tracheobronchopathia osteochondroplastica: 3 cases treated by inhaling steroid. *J Tuberc Respir Dis.* 2008;31(10):786–8.

10. Tatar D, Senol G, Demir A, Polat G. Tracheobronchopathia osteochondroplastica: four cases. *Chin Med J (Engl).* 2012;125(16):2942–4.

#### Author biography

**Supriya Adiody**, Professor & HOD  <https://orcid.org/0000-0003-1683-9348>

**Krishnanand Krishnakumar**, Senior Resident  <https://orcid.org/0009-0005-9975-7226>

**Sruthi Raghunath**, Assistant Professor

**Aravind Thayyil Raman**, Junior Resident

**Cite this article:** Adiody S, Krishnakumar K, Raghunath S, Raman AT. Tracheobronchopathia osteochondroplastica: Case report of a rare cause for a common symptom. *IP Indian J Immunol Respir Med* 2024;9(1):35-37.