



## Case Report

# A rare rapidly progressive presentation of tuberculous meningitis

Apurva Agarwal<sup>1</sup>, Swapnil Gautam<sup>2,\*</sup>, Mehul Desai<sup>1</sup>

<sup>1</sup>Bombay Hospital Institute of Medical Sciences, Mumbai, Maharashtra, India

<sup>2</sup>Dept. of Medicine, Bombay Hospital, Mumbai, Maharashtra, India



### ARTICLE INFO

#### Article history:

Received 31-05-2022

Accepted 05-12-2022

Available online 23-01-2023

#### Keywords:

Tubercular Meningitis

Dexamethasone

Thalidomide

### ABSTRACT

Tubercular Meningitis (TBM) usually presents as a sub-acute to chronic illness, with duration of symptoms ranging from weeks to months before clinical presentation. The course of disease is divided into 3 clinical stages- the stage of prodrome, phase of neurological symptoms and parietic stage, which usually progresses gradually over a period.

Here we report an unusual case of TB meningitis in young female, which progressed rapidly over a period of 7-10 days from symptom onset, without any prodromal features or previous evidence of Koch's, to reach a non-salvageable stage despite all the available diagnostic and therapeutic modalities.

This is an Open Access (OA) journal, and articles are distributed under the terms of the [Creative Commons Attribution-NonCommercial-ShareAlike 4.0 License](#), which allows others to remix, tweak, and build upon the work non-commercially, as long as appropriate credit is given and the new creations are licensed under the identical terms.

For reprints contact: [reprint@ipinnovative.com](mailto:reprint@ipinnovative.com)

## 1. Introduction

Tuberculosis-the air borne bacterial disease caused by Mycobacterium Tuberculous Bacilli infects lungs primarily, although any organ system might get involved which is referred to as extra pulmonary Koch's. Amongst extra-pulmonary TB, tubercular meningitis is considered to be the most fatal.

Topographic variations in the overall prevalence of tuberculosis, individuals with HIV and age pyramid of community, offers disparity in evaluating absolute incidence of TB meningitis (TBM). What makes it more challenging is the failure to establish microbiologically proven diagnosis in all the suspected cases. Incidence of tuberculosis from India in the recent years is 2.64 million, amongst which the estimated mortality from TBM is 1.5 per 1,00,000.<sup>1</sup>

Brain is protected from the entry of potentially harmful organism by two different vascular barriers namely blood brain barrier (BBB) and blood cerebrospinal fluid barrier (BCSFB). Mycobacterium can cross these barriers either as

free organism or as infected neutrophil/monocytes.<sup>2</sup>

We present a very unique case of TBM in which patient had unusual rapid presentation of illness within few days to eventually succumbing to illness in two weeks.

## 2. Case History

A 26-year-old female, engineer by profession with no known comorbidities, presented with complaints of acute onset irritability, headache, nausea, vomiting and behavioral abnormalities for 2-3 days. During initial evaluation patient was treated for migraine and neuroimaging (MRI) was normal on day 1. However, during next 24 hours, there was rapid worsening of clinical symptoms with onset of fever spikes and fluctuations of sensorium. On clinical examination patient's vitals were stable. Neurological examination was otherwise uncharacteristic to provide any diagnostic clue. In view of high clinical probability of possible CNS infection, CSF studies were done which showed following parameters according to Table 1.

As first CSF exam was suggestive of possible pyogenic meningitis, patient was started on intravenous ceftriaxone,

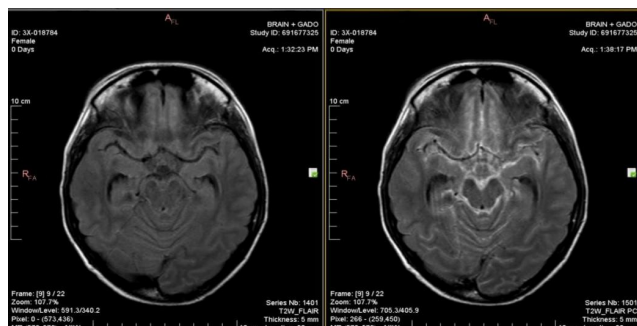
\* Corresponding author.

E-mail address: [drswapngautam@gmail.com](mailto:drswapngautam@gmail.com) (S. Gautam).

**Table 1:** Clinical parameters

CSF	Date 1.12.21	Date 3.12.21
Opening pressure	550 mm of water	330 mmH2O
Total proteins	174	168
Sugar	19/157	68/143
Total cells	615 WBCs; 84% N, 16% L	355 WBCs; 92% L, 7% N
ADA	3	8.9

vancomycin, and dexamethasone. Within 24 hours of starting broad spectrum antibiotics, patient showed early signs of recovery in the form of being conscious, more alert, and oriented. However, despite early signs of clinical recovery, patient continued to have persistent fever spikes, headache and photophobia so urgent CT Brain was done which was within normal limits and CSF studies were repeated which raised possibility of tubercular etiology, so patient was started on empirical first line antitubercular drugs. MRI Brain with contrast study was planned which showed changes of meningeal inflammation along with basal exudates, corroborating findings of CSF examination of likely tubercular etiology. Patient's clinical condition continued to worsen with deteriorating GCS and unstable vitals and hence was intubated and mechanically ventilated.



**Fig. 1:** Extensive leptomeningeal enhancement in the cerebral sulci and cisternal spaces with basal exudates

CSF GeneXpert and pyro sequencing studies for tubercular genome both returned positive results. Over next 24 hours patient further deteriorated with fixed dilated pupils, absent corneal as well as doll's eye response, sluggish cough reflex and no motor response. Considering possibility of acute hydrocephalus, urgent CT Brain was performed which however showed diffuse brain edema and no evidence of hydrocephalus. Aggressive anti-edema measures targeted at raised ICP were started along with ongoing Anti Tubercular Treatment and IV dexamethasone, thalidomide. Despite all our heroic efforts to salvage a young patient with rapidly progressive tubercular meningitis, she eventually succumbed to her illness within two weeks of symptom onset.

### 3. Discussion

Tuberculosis is one of the important causes of morbidity and mortality in developing countries like India. While pulmonary TB is most common, extra-pulmonary manifestations of TB aren't that uncommon. Common sites for extra-pulmonary involvement include brain, abdomen, lymph nodes (scrofula), spine (Pott's disease), genitourinary tract etc. Primary manifestations of CNS TB are in the form of meningitis, though less commonly may present as encephalitis, CNS tuberculoma, tubercular abscess, and spinal arachnoiditis. TBM is one of the most severe manifestations of tuberculosis and its diagnosis is often delayed because of diverse ways of presentations and poor sensitivity of the available diagnostic modalities.

The clinical manifestations of TBM are often not very specific. According to JM Murthy the classical triad of meningitis- fever, headache and vomiting are often not seen in many of the patients.<sup>3</sup> A prodromal period with constitutional symptoms like poor appetite, altered sleep cycle, fatigue, irritability, weight loss which can last from few days to weeks are seen in majority of patients.<sup>4</sup> In study by F.S. Faella et al. over 70% of cases had fever and nuchal rigidity, 44% cranial nerve palsy and 37% tetra/hemiparesis. Four (13%) cases presented with seizures, while 9 (28%) were comatose on admission.<sup>5</sup>

CSF characteristically in TBM demonstrates lymphocytic predominant pleiocytosis, low glucose and elevated proteins. Not very often, but occasionally during the early prodrome it may present with neutrophilic differential only to mimic a pyogenic picture. Yuxin Chen et al. performed a longitudinal csf assessment in a case of TB MENINGITIS, where early CSF picture was suggestive of neutrophilic differential which on further studies on day 6 yielded lymphocytic differential.<sup>6</sup> In all suspected cases, and more importantly in endemic regions GeneXpert and MGIT plays a vital role. Despite being paucibacillary in nature, WHO reports high sensitivity (59-84%) and specificity (73-89%) of GeneXpert for CSF.<sup>7</sup> The advent of GeneXpert Ultra has resulted in a 10- fold improvement in the lower limit of detection of TB.<sup>8</sup> In a study by F.S. Faella et al. diagnosis of TBM was achieved by one or more of the following: isolation of *M. tuberculosis* from CSF in 13 (41%) cases, direct examination of CSF smears in 9 (28%), active TB contacts in 15 (47%) positive Mantoux in 11 (34%). In 2 (6%) patients in absence of previous evidence TBM diagnosis was based on CSF examination and confirmed by response to antituberculosis treatment<sup>5</sup> In a study by Mei-Ling Sharon Tai et al. the cerebrospinal fluid (CSF) was predominantly with high CSF white-cell count, high protein, and low glucose level.<sup>9</sup> Total CSF white cell count can be normal in those with TB meningitis, especially in the people with depressed cell-mediated immunity, such as the elderly and HIV patients.<sup>9</sup> Low CSF white cell counts have been associated with worse outcome.<sup>9</sup>

Talking about Neuroimaging, MRI is superior when compared to CT in diagnosing TBM, by detecting leptomeningeal enhancement, basal exudates in most patients, and giving an aid about prognosis by looking at infarcts and vasculitic changes. Role of CT is mainly limited in acutely deteriorated setting, to look for hydrocephalus and need for surgical intervention. Study by F.S. Faella et al. suggested computed tomographic (CT) and/or nuclear magnetic resonance (NMR) scan findings within 48 hours from admission showed basilar enhancement in 26 (81%) patients, hydrocephalus in 15 (47%), ring or nodular enhancing lesions in 13 (41%) and hypodensities consistent with cerebral infarcts in 5 (16%). Four cases (13%) had no neuroradiological evidence on admission; 1 of these showed basal enhancement and multiple nodular lesions at an NMR routine control performed after 2 months of therapy.<sup>5</sup>

The acutely presented 26-year-old female, despite having a normal initial MRI Brain and pyogenic meningitis like picture, yet owing to high index of suspicion for TBM, was started on antitubercular treatment early in the course of illness. Apart from rapid progression of disease something most surprising about this case was the interval of significant neurological improvement lasting for 36-48 hours, from being disoriented, agitated and restless to a phase of coherence, orientation to time place person, taking oral feeds, only to deteriorate overnight, and become drowsy and eventually getting intubated by morning in view of rapidly worsening GCS.

Host related immune responses are responsible for most of the catastrophic complications. In a case reported by M.T.M. Roberts et al. Thalidomide was introduced as an adjunctive to antitubercular treatment in patients developing neurological complications to the illness. Repeat neuroimaging revealed progressive improvement.<sup>10</sup> Elevated levels of TNF-Alpha, IFN-Gamma, have been studied in CSF, hence Thalidomide, which inhibits TNF-Alpha, was used along with dexamethasone though robust evidence for the same remains lacking.

#### 4. Conclusion

Throughout the world, TB remains a challenging clinical and public health disease. Hence, high index of suspicion, early diagnosis and initiation of treatment together with management of complications associated, remains the cornerstone in management of this illness.

#### 5. Conflicts of Interest

No

#### 6. Source of Funding

No.

#### 7. Human Ethics

Written informed consent was obtained from the next of their kin for publication of case report and accompanying images.

#### Acknowledgments

We thank Dr Satish Khadilkar. Head of Department of Neurology, Bombay Hospital Institute of Medical Sciences. Mumbai. For his guidance.

We thank Family of young female suffering from the illness, for their cooperation and support.

#### References

1. Kaur H, Sharma K, Modi M, Sharma A, Rana S, Khandelwal N, et al. Prospective Analysis of 55 Cases of Tuberculosis Meningitis (TBM) in North India. *J Clin Diagn Res.* 2015;9(1):15–9.
2. Be NA, Kim KS, Bishai WR, Jain SK. Pathogenesis of central nervous system tuberculosis. *Curr Mol Med.* 2009;9(2):94–9.
3. Murthy JM. Tuberculous meningitis: the challenges. *Neurol India.* 2010;58(5):716–22.
4. Gupta G. Tuberculous meningitis; 2021. Available from: <https://emedicine.medscape.com/article/1166190-overview>.
5. Faella FS, Pagliano P, Attanasio V, Rossi M, Rescigno C, Scarano F, et al. Factors influencing the presentation and outcome of tuberculous meningitis in childhood. *In Vivo.* 2006;20(1):187–91.
6. Chen Y, Liu X, Zhang X, Zhang Z, Zhou X, Wang Y, et al. Longitudinal cerebrospinal fluid assessment in a patient with tuberculous meningitis-A case report. *J Clin Lab Anal.* 2020;34(7):e23286.
7. Rai A, Prasad R, Das BK, Anupurba S, Singh UK. Cerebrospinal fluid Gene XPERT (CBNAAT) in children with tuberculous meningitis. *J Clin Tuberc Other Mycobact Dis.* 2021;24:100255. doi:10.1016/j.jctube.2021.100255.
8. Sekyere JO, Maphalala N, Malinga LA, Mbelle NM, Maningi NE. A Comparative Evaluation of the New GeneXpert MTB/RIF Ultra and other Rapid Diagnostic Assays for Detecting Tuberculosis in Pulmonary and Extra Pulmonary Specimens. *Sci Rep.* 2019;9(1):16587.
9. Tai M. Tuberculous Meningitis: Diagnostic and Radiological Features, Pathogenesis and Biomarkers. *Neurosci Med.* 2013;4(2):101–7.
10. Roberts MTM, Mendelson M, Meyer P, Carmichael A, Lever AML. The use of thalidomide in the treatment of intracranial tuberculomas in adults: two case reports. *J Infect.* 2003;47(3):251–5.

#### Author biography

**Apurva Agarwal**, Resident Doctor

**Swapnil Gautam**, Consultant

**Mehul Desai**, Resident Doctor

**Cite this article:** Agarwal A, Gautam S, Desai M. A rare rapidly progressive presentation of tuberculous meningitis. *IP Indian J Immunol Respir Med* 2022;7(4):170-172.