



## Original Research Article

# Clinico-radiological profile of COVID-19 in a tertiary care hospital of western Rajasthan

Laxman Kumar Soni<sup>1</sup>, K.C Agarwal<sup>1</sup>, Priyanka Soni<sup>2,\*</sup><sup>1</sup>Dept. of Pulmonary Medicine, Government Medical College, Pali, Rajasthan, India<sup>2</sup>Dept. of Microbiology, Government Medical College, Pali, Rajasthan, India

## ARTICLE INFO

## Article history:

Received 25-07-2021

Accepted 16-08-2021

Available online 29-09-2021

## Keywords:

Clinico-radiological  
coronavirus disease 2019  
Lymphopenia

## ABSTRACT

**Background:** Coronavirus disease 2019 (COVID-19) is a pandemic infectious disease caused by a novel coronavirus, known as severe acute respiratory syndrome coronavirus 2 (SARS-CoV-2). Infection by COVID-19 can result in a range of clinical outcomes, from asymptomatic to severe life-threatening course or death.

The purpose of our research was to evaluate the presentation of COVID19 disease based on the clinical and radiological characteristics of our population.

**Materials and Methods:** 100 COVID19 patients recorded by RTPCR. Clinical, biochemical and radiological data from April-May, 2021.

**Results:** Of the 100 patients, in our study 66% were males and 26% patients had history of recent travel. Majority of patients were asymptomatic and don't have comorbid illness. Thrombocytopenia and lymphopenia, increased levels of lactate dehydrogenase (LDH) and serum ferritin and C-reactive protein were common in these patients. CT finding were 63% had normal CT chest. Among the 37% patients who had CT chest findings, 25% had bilateral diseases, 8% patients had right lung involvement while 4% patients have left lung involvement.

**Conclusion:** COVID-19 disease has a relatively mild course in this part of the subcontinent. Clinical and laboratory findings are similar to those found in viral diseases. Studies involving larger sample size and interventional trials are need of the hour.

This is an Open Access (OA) journal, and articles are distributed under the terms of the [Creative Commons Attribution-NonCommercial-ShareAlike 4.0 License](https://creativecommons.org/licenses/by-nc-sa/4.0/), which allows others to remix, tweak, and build upon the work non-commercially, as long as appropriate credit is given and the new creations are licensed under the identical terms.

For reprints contact: [reprint@ipinnovative.com](mailto:reprint@ipinnovative.com)

## 1. Introduction

Coronavirus disease 2019 (COVID-19) is a pandemic infectious disease caused by a novel coronavirus, known as severe acute respiratory syndrome coronavirus 2 (SARS-CoV-2). SARS-CoV-2 genome is similar to that of SARS and Middle East respiratory syndrome.<sup>1</sup> Infection by COVID-19 can result in a range of clinical outcomes, from asymptomatic to severe life-threatening course or death. Aim of this study to identify the clinical and radiological characteristics and biochemical variable in study population

of Rajasthan, India.<sup>2</sup>

## 2. Materials and Methods

This Prospective study was conducted at tertiary care centre hospital of western Rajasthan. The data of the 100 RT-PCR positive COVID-19 patients were collected including clinical presentation, laboratory parameters, and CT scan reports. This study has been approved by the institutional ethical committee. Informed consents were taken from the patients.

\* Corresponding author.

E-mail address: [priyanka.soni888@gmail.com](mailto:priyanka.soni888@gmail.com) (P. Soni).

### 2.1. CT acquisition protocol and image interpretation

Chest HRCT was performed on an average 3 days (range 1–9 days) after symptom onset that were performed on a 16-Slice Siemens Somatom, Emotion Multidetector CT using 16 × 0.6 collimation, 100–120 kVp, and 90–130 mAs using low dose radiation as per institutional protocol. Sharp kernel (B70s) algorithm was used. Mediastinal window and lung window films were viewed.

An experienced radiologist evaluated CT images. Assessment of presence, location, extent, and density of lung parenchymal abnormality was made and specifications as per unilaterality/bilaterality, lobar distribution and with regards to anterior and posterior location was noted. Ground glass opacity (GGO) was defined as increase in density of lung with visualization of bronchial and vascular structures through it, whereas consolidation was defined as increased density of lung tissue through which vascular and bronchial structures were not visible. Vascular enlargement was considered to be present when vessel diameter was more than 3 mm.

### 2.2. Confirmation of COVID-19

Nasopharyngeal and oropharyngeal swab specimens from the upper respiratory tract were obtained from all patients as per the standard microbiological protocol. 2019-nCoV was confirmed by real-time RT-PCR.

### 2.3. Statistical analysis

Data was entered in a Microsoft Excel spreadsheet. Continuous variables were summarized as median and inter-quartile range. Data analysis was done using SPSS for windows version 23 (IBM Corp. Released 2012. IBM SPSS Statistics for Windows, Version 23.0. Armonk, NY: IBM Corp.)

## 3. Results

Total number of RT-PCR documented COVID-19 patients included in this study were 100. The demographic details of the patients and their contact and travel history in presented in Table 1. In our study 66% were males. 26% patients had history of recent travel both from international and national destinations; the rest 48% had a history of contact with a SARS-CoV-2 positive patient.

In our study, 52% patients were asymptomatic. Cough was the most common symptom 31%, followed by myalgia 25%. (Chart 1)

In our study 42% patients had no comorbid illness. Some of the study population had more than one comorbid illness showed in Table 2.

The biochemical laboratory values were not available for whole of the study population. 31% of the patients have anaemia on admission, while as thrombocytopenia was

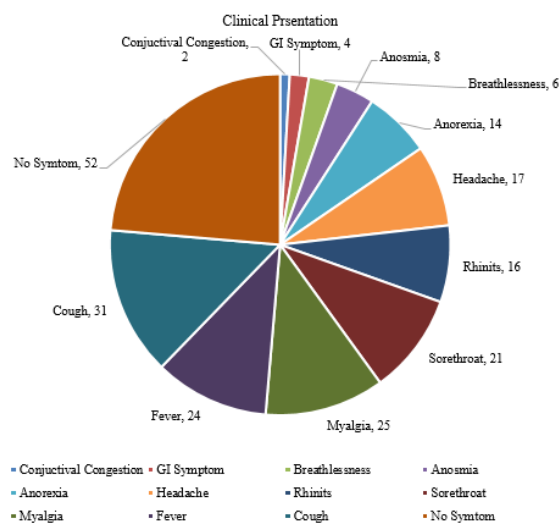
present in 36% of patients. Lymphopenia was present in 58% of patients. Most of the patients had increased levels of lactate dehydrogenase (LDH) and serum ferritin. C-reactive protein was increased in 91% of patients.

In our study CT finding were 63% had normal CT chest. Among the 37% patients who had CT chest findings, 25% had bilateral diseases, 8% patients had right lung involvement while 4% patients had CT chest findings only on left side of the lung. (Table 3)

Right upper lobe was the most common lobe involved in 24% patients, left lower lobe was involved 31% patients, left upper lobe in 22% patients, right lower lobe in 28% patients, and right middle lobe in 18% patients. (Table 4)

**Table 1: Patient characteristic**

Patient characteristics	Percent (n=64)
<b>Age (Years)</b>	
<=10	4
11-20	8
21-30	14
31-40	23
41-50	11
51-60	21
Above 61	19
<b>Gender</b>	
Male	66
Female	34
<b>History of contact</b>	48
<b>History of travel</b>	26



**Chart 1: Clinical Presentation**

### 3.1. Clinical outcome

Out of the 100 patients included in our study, 3 patients developed severe disease with respiratory compromise and

**Table 2:** Comorbid illnesses

Comorbid illnesses	Percent (n=100)
No comorbid illness	42
Hypertension	12
Thyroid disorder	8
Chronic obstructive pulmonary diseases	7
Diabetes mellitus	6
Coronary artery disease	6
Smoker	4
Chronic kidney disease	2

**Table 3:** CT findings in the study patients

<b>Bilateral</b>	25
<b>Right lung</b>	8
<b>Left lung</b>	4
<b>Normal</b>	63

**Table 4:** CT finding-Lobar involvement

Lobar Involvement-	
RUL	24
RML	18
RLL	28
LUL	22
LLL	31

saturation of less than 70% on room air. These patients were subsequently shifted to ICU and managed there. One patient out of the three patients admitted in ICU expired. Expired patients had Diabetes mellitus as comorbid illness.

#### 4. Discussion

COVID-19 infection in our study, males were more suffered as compared to females (66% vs. 34%). Similar results seen by Badawi A. et al. and Channappanavar R. et al.<sup>3,4</sup> Most of the patients in the present study do have a history of contact with a COVID-19 patient, while as a few have history of travel from areas where COVID-19 disease does exist. These findings are in sync with the route of transmission of other coronaviruses via respiratory droplets and direct contact.<sup>5,6</sup>

Majority (52%) of the patients were asymptomatic. Cough and myalgia were the most common symptoms in 31% and 25% of patients, respectively. In a study from Wuhan by Huang et al.,<sup>7</sup> fever and cough was the most common symptom in 98% and 76%, respectively.

Out of 100 patients RT-PCR positive COVID-19, majority of the patients 63% have no radiological findings. 25% patients had bilateral diseases; 8% patients had right lung involvement while 4% patients had CT chest findings only on left side of lung. Bilateral pattern of involvement in COVID-19 patients on CT chest has been reported by various authors. Shi et al.<sup>8</sup> reported that 64 (79%) among 81 patients had bilateral disease.<sup>9</sup>

#### 5. Conclusions

COVID-19 disease has a relatively mild course in this part of the subcontinent. Clinical and laboratory findings are similar to those found in viral diseases. Majority of affected patients were male and asymptomatic and don't have comorbid illness. Thrombocytopenia and lymphopenia, increased levels of lactate dehydrogenase (LDH) and serum ferritin and C-reactive protein were common in study population. Studies involving larger sample size and interventional trials are need of the hour.

#### 6. Acknowledgments

None.

#### 7. Conflict of Interest

The authors declare that there are no conflicts of interest in this paper

#### 8. Source of Funding

None

#### References

- Rothan HA, Byrareddy SN. The epidemiology and pathogenesis of coronavirus disease (COVID-19) outbreak. *J Autoimmun.* 2020;109:102433. doi:10.1016/j.jaut.2020.102433.
- Guan WJ, Ni ZY. China Medical Treatment Expert Group for COVID-19, Clinical Characteristics of Coronavirus Disease 2019 in China. *N Engl J Med.* 2020;30(18):1708–20. doi:10.1056/NEJMoa2002032.
- Badawi A, Ryoo SG. Prevalence of comorbidities in the Middle East respiratory syndrome coronavirus (MERS-CoV): A systematic review and meta-analysis. *Int J Infect Dis.* 2016;49:129–33. doi:10.1016/j.ijid.2016.06.015.
- Channappanavar R, Fett C, Mack M, Eyck PT, Meyerholz DK, Perlman S, et al. Sex-based differences in susceptibility to severe acute respiratory syndrome coronavirus infection. *J Immunol.* 2017;198(10):4046–53. doi:10.4049/jimmunol.1601896.
- Lei H, Li Y, Xiao S, Lin CH, Norris SL, Wei D, et al. Routes of transmission of influenza A H1N1, SARS CoV, and norovirus in air cabin: Comparative analyses. *Indoor Air.* 2018;28(3):394–403. doi:10.1111/ina.12445.
- Otter JA, Donskey C, Yezli S, Douthwaite S, Goldenberg SD, Weber DJ, et al. Transmission of SARS and MERS Coronaviruses and influenza virus in healthcare settings: The possible role of dry surface contamination. *J Hosp Infect.* 2016;92(3):235–50. doi:10.1016/j.jhin.2015.08.027.
- Huang C, Wang Y, Li X, Ren L, Zhao J, Hu Y. Clinical features of patients infected with 2019 novel coronavirus in Wuhan. *China Lancet.* 2020;395:497–506.
- Shi H, Han X, Jiang N, Cao Y, Alwalid O, Gu J, et al. Radiological findings from 81 patients with COVID-19 pneumonia in Wuhan, China: A descriptive study. *Lancet Infect Dis.* 2020;20(4):425–34. doi:10.1016/S1473-3099(20)30086-4.
- Caruso D, Zerunian M, Polici M, Pucciarelli F, Polidori T, Rucci C, et al. Chest CT Features of COVID-19 in Rome, Italy. *Radiology.* 2020;296(2):79–85. doi:10.1148/radiol.202021237.

#### Author biography

Laxman Kumar Soni, Assistant Professor

**K.C Agarwal**, Senior Professor and Head

**Priyanka Soni**, Assistant Professor

**Cite this article:** Soni LK, Agarwal KC, Soni P. Clinico-radiological profile of COVID-19 in a tertiary care hospital of western Rajasthan. *IP Indian J Immunol Respir Med* 2021;6(3):152-155.