

Content available at: <https://www.ipinnovative.com/open-access-journals>

IP Indian Journal of Immunology and Respiratory Medicine

Journal homepage: <https://www.ipinnovative.com/journals/IJIRM>

Case Report

Case of chronic pulmonary aspergillosis, pulmonary tuberculosis, and Klebsiella pneumoniae co-infection in an Indian diabetic male- A first of its type case report in the pandemic of COVID-19 from Asia

Sankalp Yadav^{1,*}, Gautam Rawal²

¹Dept. of Medicine & Tuberculosis, Shri Madan Lal Khurana Chest Clinic, Moti Nagar, NDMC, New Delhi, India

²Dept. of Respiratory Intensive Care, Max Super Specialty Hospital, Saket, New Delhi, India



ARTICLE INFO

Article history:

Received 1-10-2020

Accepted 1-12-2020

Available online 15-12-2020

© This is an open access article distributed under the terms of the Creative Commons Attribution License (<https://creativecommons.org/licenses/by/4.0/>) which permits unrestricted use, distribution, and reproduction in any medium, provided the original author and source are credited.

1. Introduction

In the current pandemic of coronavirus disease 2019 (COVID-19) which has crumbled the healthcare systems globally, other diseases that have been in existence for ages have been receiving less attention.¹ The SARS-CoV-2 pandemic has led to so much loss of life that the clinicians are ruling out the COVID-19 in all the cases reporting to them before proceeding to diagnose and manage any other disease.¹ The diseases which are mostly related to the respiratory system like pulmonary aspergillosis, pulmonary tuberculosis (TB), and pneumonia are still existing and are presenting more profoundly than in the past.¹ These diseases have similar clinical features and thus require a high index of suspicion and judicious use of investigations to finalize a diagnosis. Besides, the occurrence of these diseases in a person with poor immunity as in cases with Diabetes Mellitus (DM) is quite possible.² Herein, the authors present a very rare case of chronic pulmonary aspergillosis (CPA), pulmonary TB, and Klebsiella pneumoniae co-infection in an Indian diabetic male during the ongoing pandemic of COVID-19. Our case is extremely rare and to the best knowledge of the authors, no such case is ever reported from anywhere in the world

except the one from Nigeria.

2. Case Report

A 32 years old Indian male carpenter by occupation reported to us in the outpatient department (OPD) with complaints of cough with blood-tinged sputum for four days, fever for one week, loss of appetite for two weeks, and shortness of breath for two weeks. The cough was regular and was associated with thick blood-tinged sputum. The sputum was non-foul smelling. The fever was low grade and evening rise with no chills and rigor. The fever was relieved after taking Paracetamol. He also complained of breathlessness on walking and sometimes at rest. The breathlessness was aggravated when it was associated with the cough episodes. He also reported a loss of appetite and a weight loss of about five kilograms in the last one month.

In past history, he was a diagnosed case of DM for eight months and was irregularly taking oral antihyperglycemic agents (OAH). There was no history of TB, CPA, pneumonia, etc. in the past. Also, there is no history of any such complaints in the past to him, to his family, or any of his contacts. And there was no history of smoking or any other substance abuse. There were no food or any drug allergies.

* Corresponding author.

E-mail address: drsankalpyadav@gmail.com (S. Yadav).

On general examination, he was afebrile and pale with a body mass index of 20.1 kg/m². There was no clubbing, cyanosis, icterus, lymphadenopathy, or edema. On systemic examination, he had tachypnea with left infraclavicular bronchial breath sounds and coarse crackles in the left upper lobe.

To establish a diagnosis initially he was advised a chest radiograph with sputum for acid fast bacilli (AFB), and RT-PCR for COVID-19. He was negative for COVID-19 but his chest radiograph showed a large oval-shaped thick-walled cavity with infiltration on the left upper lung zone (Figure 1). Ziehl-Neelsen staining of the sputum was positive for acid fast bacilli as 3+. Further, Cepheid Xpert[®] MTB/RIF assay of the sputum detected medium levels of *Mycobacterium tuberculosis* with no resistance to Rifampicin. His Montoux test was 17mmX15mm. Sputum microscopy using potassium hydroxide (KOH) detected some fungal elements, however, no fungi were isolated after two weeks of culture. The Aspergillus precipitin test yielded high *Aspergillus fumigatus* immunoglobulin G (IgG) levels of 152 mcg/mL. Again, the sputum bacterial culture yielded moderate growth of *Klebsiella pneumoniae* after six weeks. The patient was also advised a non-contrast computed tomography (CT) scan of the chest which showed a thick-walled irregular shaped cavitory lesion measuring 4.2 × 3.2 × 3.4 cm in the apical region of the left upper lobe with evidence of intralesional soft tissue density (Figure 2). There was evidence of perilesional ground glass haziness with air space opacities. Also, randomly distributed centrilobular nodular opacities were seen in the left upper lobe and left lingula. Few fibroparenchymal opacities were also seen in the left lingula.

His fasting blood glucose levels were 230mg/dL with an HbA1c of 10.5%. Other relevant blood biochemical parameters were hemoglobin-9 g/L, ESR-110 mm/h, serum urea-1.3 mmol/L, serum creatinine-70 μmol/L, serum bilirubin-4 μmol/L, serum protein-72 g/dL, and serum albumin-30 g/L.

Based on the patient examination and findings of the investigations a diagnosis of CPA with pulmonary TB, and *Klebsiella pneumoniae* co-infection in a diabetic Indian male was established. To begin with, he was started on the four-drug anti-tubercular therapy (ATT) as per his weight with Isoniazid, Rifampicin, Pyrazinamide, and Ethambutol. Later on, with the further diagnosis of concomitant Aspergillosis and *Klebsiella pneumoniae*, he was started on Itraconazole 200 mg 12 hourly for six months and Ceftazidime 1 g given 12 hourly for ten days. For his uncontrolled DM, he was referred to an endocrinologist who started him on a combination of soluble Insulin and Insulin Glargine. Presently patient is on treatment and is advised regular follow-ups in the OPD. His symptoms have improved and his blood sugar levels are also under check. Besides, written informed consent was obtained from the patient to publish

this case report and associated data including the pictures.

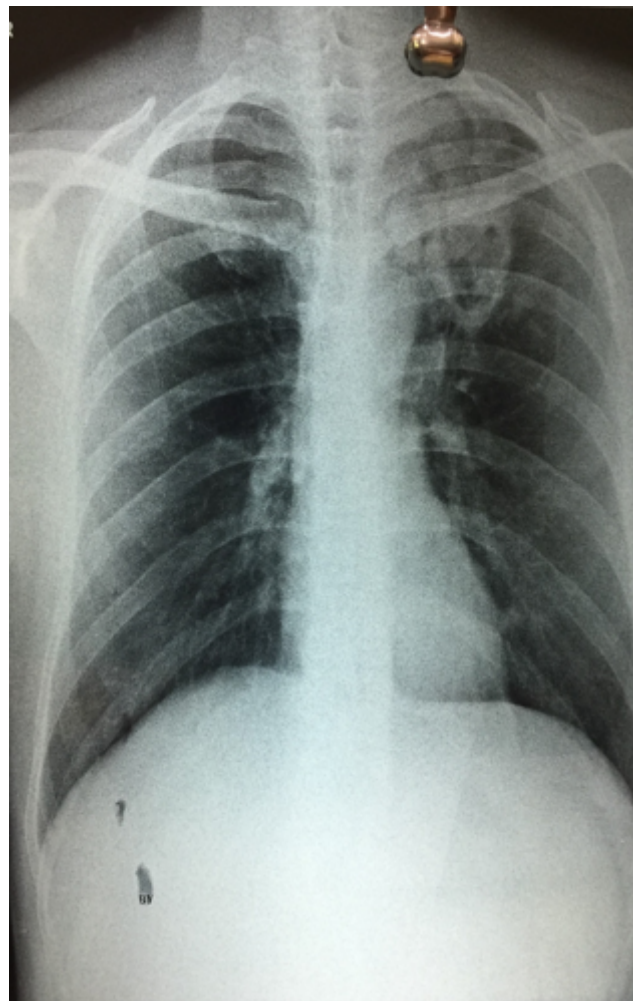


Fig. 1: Chest radiograph showing a large oval shaped thick-walled cavity with infiltration on the left upper lung lobe

3. Discussion

In highly populated countries like India which is having some of the largest numbers of cases of infections like TB and lifestyle diseases like DM.³ The situation becomes even graver when such diseases are associated with other concomitant infections like Aspergillosis and *Klebsiella*. A diabetic individual is highly susceptible to infections by ubiquitous microbes like *Aspergillus*, *Mycobacterium tuberculosis*, and *Klebsiella*.² The fungus *Aspergillus* results in a spectrum of pulmonary diseases ranging from a noninvasive disease to an invasive infection.²

CPA is a rare but problematic pulmonary disease, that can present in cases with the underlying lung diseases thereby complicating the management of these diseases.^{4,5} The commonest form of CPA is chronic cavitory pulmonary aspergillosis (CCPA), which if not treated could

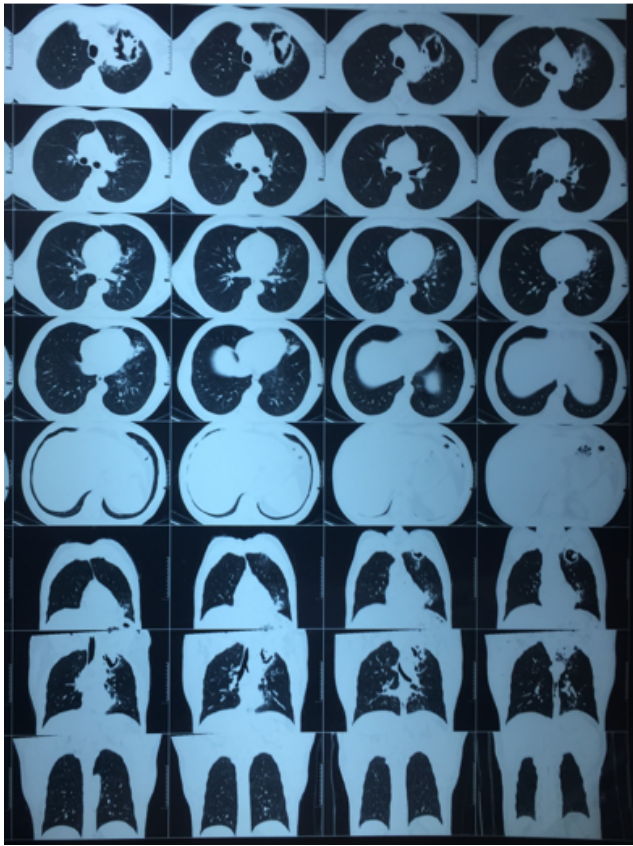


Fig. 2: NCCT scan of the chest showing a thick walled irregular shaped cavitary lesion in the apical region of the left upper lobe with evidence of intra lesional soft tissue density

progress to chronic fibrosing pulmonary aspergillosis.⁴ Less common manifestations include *Aspergillus* nodule and single aspergilloma.⁴ CPA is seen commonly in immunocompetent patients.⁶ Its diagnosis is often missed and is the main factor that accounts for progressive lung destruction and the persistence of symptoms after successful ATT and can mimic smear-negative PTB.^{2,6} Also, in densely populated countries patients with DM are more susceptible to PTB and *Klebsiella pneumoniae* infections.^{2,7}

CPA can complicate pulmonary TB especially when there is pulmonary cavitation which is the hallmark of established PTB and this is often associated with high bacillary load.⁸ This was evident in our case with 3+ reports on Ziehl-Neelsen staining of the sputum and medium levels of *Mycobacterium tuberculosis* detected on Cepheid Xpert[®] MTB/RIF assay of the sputum.

Aspergilloma has a variable natural history.⁹ The most common presentation is hemoptysis, with an incidence of around 80%, which could be fatal in 30%.¹⁰ In the bulk of the cases, the fungal lesion remains stable, however, in approximately 10% of cases, it has the propensity to either reduce in size or resolve spontaneously without treatment.¹¹ Very rarely, the size of aspergilloma increase.¹²

The present case is a rare case wherein a diabetic Indian male was diagnosed with concomitant CPA, pulmonary TB, and *Klebsiella pneumoniae*. The present case is the first of its type case reported from Asia. A similar case was reported in Ekwueme et al. 2016, but our case differs from their case in age, gender, ethnicity, location, and also the bacillary load in our case was higher.² The present case is also unique as the diagnosis of such a case is made in the current pandemic of COVID-19. However, both cases will serve as an important addition to the medical literature and will help clinicians worldwide especially in the current pandemic of the COVID-19.

To summarize the respiratory infections like pulmonary TB, CPA, *Klebsiella*, etc. should always be kept in mind while diagnosing a case with other comorbid conditions like diabetes. The clinical features in these diseases are quite common and thus efforts should be made to rule out these conditions especially in the settings where these diseases are endemic.

4. Acknowledgements

Nil.

5. Source of Funding

Nil.

6. Conflicts of interest

Nil.

References

1. Yadav S, Rawal G. The ramification of COVID-19 on the other diseases- Time for a prompt action. *IP Indian J Immunol Respir Med.* 2020;5(3):135–6.
2. Ekwueme C, Otu AA, Chinenye S, Unachukwu C, Oputa RN, Korubo I, et al. Haemoptysis in a female with diabetes mellitus: a unique presentation of chronic pulmonary aspergillosis, pulmonary tuberculosis, and *Klebsiella pneumoniae* co-infection. *Clin Case Rep.* 2016;4(4):432–6.
3. Restrepo BI. Diabetes and Tuberculosis. *Microbiol Spectr.* 2016;4(6):10.1128/microbiolspec.TNMI7-0023-2016.
4. Denning DW, Cadranell J, Beigelman-Aubry C, Ader F, Chakrabarti A, Blot S, et al. Chronic pulmonary aspergillosis: rationale and clinical guidelines for diagnosis and management. *Eur Respir J.* 2016;47(1):45–68.
5. Schweer KE, Bangard C, Hekmat K, Cornely OA. Chronic pulmonary aspergillosis. *Mycoses.* 2014;57(5):257–70.
6. Restrepo BI. Convergence of the Tuberculosis and Diabetes Epidemics: Renewal of Old Acquaintances. *Clin Infect Dis.* 2007;45(4):436–8.
7. Dutt J, Dabhi L. Study of pneumonia in diabetic patients. *Int J Med Sci Public Health.* 2014;3(8):974–6.
8. Ong CW, Elkington PT, Friedland JS. Tuberculosis, Pulmonary Cavitation, and Matrix Metalloproteinases. *Am J Respir Crit Care Med.* 2014;190(1):9–18.
9. Kumar AA, Shantha GPS, Jeyachandran V, Rajkumar K, Natesan S, Srinivasan D, et al. Multidrug resistant tuberculosis co-existing with aspergilloma and invasive aspergillosis in a 50 year old diabetic woman: a case report. *Cases J.* 2008;1(1):303.

10. Vaideeswar P, Prasad S, Deshpande JR, Pandit SP. Invasive pulmonary aspergillosis: A study of 39 cases at autopsy. *J Postgrad Med.* 2004;50:21–6.
11. Gefter WB. The spectrum of pulmonary aspergillosis. *J Thorac Imaging.* 1992;7(4):56–74.
12. British Tuberculosis Association: Aspergillus in persistent lung cavities after tuberculosis: a report from the Research Committee of

the British Tuberculosis Association. *Tubercle.* 1968;49:1–11.

Cite this article: Yadav S, Rawal G. Case of chronic pulmonary aspergillosis, pulmonary tuberculosis, and *Klebsiella pneumoniae* co-infection in an Indian diabetic male- A first of its type case report in the pandemic of COVID-19 from Asia. *IP Indian J Immunol Respir Med* 2020;5(4):259-262.