



Case Report

A tale of a young boy with recurrent wheezing and uncommon bronchiectasis

Somnath Bhattacharya^{1,*}, Saurabh Karmakar¹

¹Dept. of Pulmonary Medicine, All India Institute of Medical Sciences, Patna, Bihar, India



ARTICLE INFO

Article history:

Received 25-01-2020

Accepted 19-02-2020

Available online 13-04-2020

Keywords:

Common variable immunodeficiency disorder

Cryptogenic Organizing pneumonia

Granulomatous lymphocytic

interstitial lung disease

Tubercular pleural effusion

Immunoglobulin therapy

ABSTRACT

Bronchiectasis in the era of high-resolution computerized tomography scan has become a common respiratory manifestation with varied etiology. Among exhaustive list of etiologies, common variable immunodeficiency disorder (CVID) is an uncommon cause for bronchiectasis. Thereby, leading to under detection, lack of suspicion and eventually delayed treatment. Though the prevalence of bronchiectasis remains high in patients with CVID, it usually presents late. In day to day clinical practice primary immunodeficiency is not suspected usually and hence workup lacks for this cause of bronchiectasis. CVID patients besides recurrent infections also exhibits various extrapulmonary manifestations. So, we report to generate awareness through this case of a young boy who presented with bronchiectasis due to CVID complicated by COP (Cryptogenic Organizing Pneumonia) or GLILD (Granulomatous lymphocytic interstitial lung disease) and Tubercular pleural effusion. He was treated with intravenous immunoglobulin and antitubercular therapy and responded well.

© 2020 Published by Innovative Publication. This is an open access article under the CC BY-NC-ND license (<https://creativecommons.org/licenses/by/4.0/>)

1. Introduction

Common variable immunodeficiency (CVID) as an etiology for bronchiectasis needs clinical suspicion and meticulous work up. In countries with high prevalence of tuberculosis and its sequelae, bronchiectasis is a common consequence. By convention when meticulous work up fails to clinch an etiology, bronchiectasis is considered either to be idiopathic or post infective from past. But nowadays with availability of serum immunoglobulin levels by nephelometry had opened up the spectrum of detection of immunodeficiencies as cause.

CVID is a polygenic, heterogenous primary immunodeficiency characterized by a failure in B-cell differentiation leading to defective immunoglobulin production.^{1,2} CVID patients manifest as clinical syndrome comprising of susceptible recurrent sinopulmonary infections with encapsulated organisms along with inflammatory or autoimmune manifestations.

CVID is the most common clinically significant primary immunodeficiency disease.³ Bronchiectasis in CVID is common but has a late presentation. But the age of onset of CVID being variable range from 20–40 years. However up to 20% may present before the age of 20 years.¹ So early diagnosis and treatment can make a difference in outcome and increase productivity in lifetime. As estimated from literatures 1 in 25,000–50,000 subjects develop CVID hence a very rare manifestation to detect.^{2–4} Due to under diagnosis a common delay in detection followed by treatment can occur up to 5–10 years.⁵

Hence, we report here this rare case for early detection of an uncommon etiology of bronchiectasis that is CVID along with its complications, whose proper management can make a difference to future morbidity and mortality of the patients.

2. Case Report

A 16-year-old young boy presented with complain for fever (on & off), cough with mucoid expectoration, wheezing for 1 month. He also complained of increased exertional breathless ness and left sided chest pain for last 10

* Corresponding author.

E-mail address: drsnbhattacharya@gmail.com (S. Bhattacharya).

days. He often suffered from recurrent allergic rhinitis and chest infections since childhood which increased over last 3 years. He was treated by local doctors as per his symptoms over the years. He was treated with antitubercular therapy for a period of 9 months in 2018 as sputum negative pulmonary tuberculosis from local doctors. He was initially examined and managed in the OPD of the Department of Pulmonary Medicine at AIIMS, Patna. He was emaciated, with pallor, clubbing but no lymphadenopathy. His vitals were stable with pulse oximetry showing SpO₂ = 98% room air. Respiratory system examination findings had bilateral diffuse coarse crepitations and rhonchi on auscultation. His routine blood investigations showed mild anemia. Sputum examinations for mycobacterium-acid fast bacilli and Gene Xpert were negative. USG abdomen had no organomegaly or abdominal lymphadenopathy. Cultures of blood, and sputum were sterile all throughout our investigations. Chest radiograph showed consolidation in left lower zone and evidence were suggestive of bronchiectasis [Figure 1]. Spirometry was suggestive of reversible airway obstruction. Hence total Serum IgE and Aspergillus specific IgE was advised which eventually was negative. His HIV report was non-reactive and HBV and HCV were negative. ANA screening, ANCA, and rheumatoid factor were also negative. High resolution computed tomography (HRCT) chest was done which confirmed presence of bilateral diffuse cystic bronchiectasis with consolidation in the left lower lobe. [Figure 2 a and b]. Considering the possibility of immunodeficiency disorder, serum IgG, IgM, IgE and IgA was done. His serum Ig levels were low- Ig G <270mg/dl (Level 700-1600mg/dl), Ig M < 15mg/dl (Level 40-230mg/dl, IgA 13mg/dl (Level 70-400mg/dl) and IgE 2.1KU/L (Level 0-113KU/L) by Nephelometry. He was admitted for further evaluation. Primary isolated hypogammaglobulinemia and secondary (drugs and nephrotic syndrome) immunodeficiency was excluded. Hence bronchoscopy and BAL (Bronchoalveolar lavage) was performed for evaluation of consolidation. BAL sample was sterile (negative AFB smear and BACTEC culture and Gene Xpert, negative for Gram stain and culture) with lymphocyte predominance (>25%).

He was treated empirically with antibiotics piperacillin tazobactam with aminoglycoside and macrolide along with bronchodilators for 10 days. Considering the spectrum of evidences, CVID complicated with COP (Cryptogenic Organizing Pneumonia) or GLILD (Granulomatous lymphocytic interstitial lung disease) was diagnosed and treated with intravenous IgG 400mg/kg per month with target serum Ig G trough level >500mg/dl. He was vaccinated with Pneumococcal vaccine during discharge. His pneumonic consolidation resolved spontaneously (thereby no lung biopsy attempted) but developed right sided pleural effusion. (Figure 3). Pleural fluid study was suggestive of tubercular etiology (exudative, lymphocytic, ADA 45 U/L)

and was started on ATT. He responded well with resolution of symptoms and is on continuation of ATT treatment. Hence, we presented this case as an unusual etiology of bronchiectasis – CVID complicated with left lower lobe COP/GLILD and right sided tubercular pleural effusion.

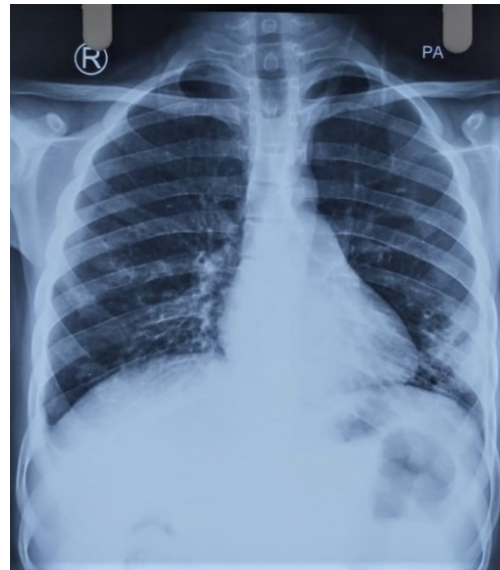

Fig. 1: Left lower zone pneumonia with cystic bronchiectasis

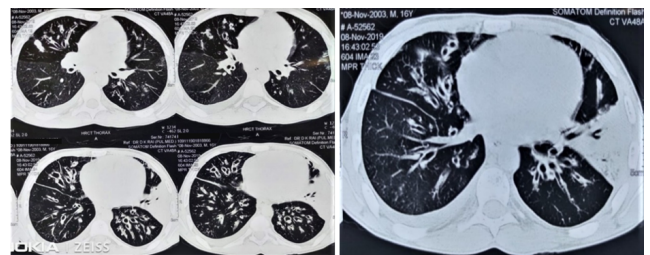


Fig. 2: A & B: HRCT thorax showing diffuse cystic and traction bronchiectasis with left lower lobe consolidation (COP or GLILD)

3. Discussion

CVID as a primary immunodeficiency can be diagnosed after proper exclusion of etiologies leading to immunodeficiency like genetic defects, malignancy, nephrotic syndrome or use of immunosuppressant.⁶ Accurate diagnosis of immune deficiency is difficult at times and lacks proper work-up.^{6,7} A detailed investigation of past medical history like presence of recurrent allergic sinopulmonary diseases is needful to understand the immunodeficiency, as seen in our case. Possible family history of immunodeficiency in relatives or sibling must be noted, though in our case there was no such history. Maternal antibodies impart immunity to children up to 6 months of age, therefore according to European Society for the Immunodeficiency's (ESID)

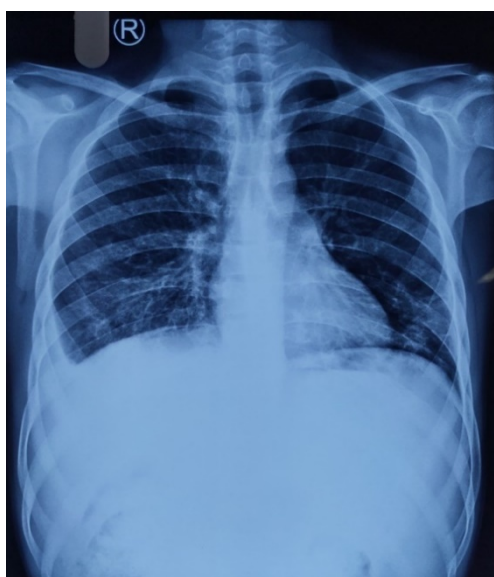

Fig. 3: Chest X-ray showing left lower zone resolving consolidation and right pleural effusion

criteria CVID is usually detected after 2 years of age. ESID criteria needs decreased (< 2 standard deviations of the mean) levels of IgG with reduced IgA and/or IgM, together with failure to mount a significant antibody response to vaccination, in the absence of a known cause.^{6,8} Here we were able to diagnose him at 16 years of age, that too only 20% cases are diagnosed < 20 years of age.¹ His serum Ig levels were lower, showing IgG < 270 mg/dl (level 700–1600mg/dl), IgE 2.1KU/L (level 0–113KU/L), IgM < 15 mg/dl (level 40–230mg/dl), and IgA 13mg/dl (level 70–400mg/dl) done by Nephelometry.

Nutritional status of the patient should be evaluated. Unexplained weight loss and failure to growth is relatively common symptom in CVID as seen in our case too.

In CVID patients there is recurrent upper and lower respiratory tract infections commonly by encapsulated organisms and atypical organisms. Respiratory tract infections comprised mostly of rhinitis, sinusitis, otitis media and pneumonia. Capsulated organisms mostly included *Streptococcus pneumoniae* and *H influenzae*.^{1,6,8} Whereas atypical organisms in CVID patients were mostly *Mycoplasma*, *Ureaplasma* species. Gram-negative rods should also be considered, in particular in patients with impaired cellular immunity or prolonged sufferer of CVID.^{6,9} Hence the antibiotic policy to treat must cover these spectra to get early control over infection and stop the sequelae of changes that occurs post repetitive infection and healing.⁷ Empirical antimicrobial therapy thereby must include drugs such as macrolides or fluoroquinolones because they cover both encapsulated and atypical organisms. Hence our choice of empirical antibiotics covered the same for left lower lobe consolidation, though his sputum and BAL sample cultures

were sterile all throughout the hospitalization.

Opportunistic infections occurred in around 10% of patients with CVID.^{1,6,10} T-cell abnormalities with CVID had more variable clinical manifestations. Gastrointestinal infection with *C. jejuni*, *Salmonella* sp, and *Giardia lamblia*, Hepatitis C (12%), liver disease such as nodular regenerative hyperplasia, splenomegaly. Non-caseating Sarcoid like granulomatous disease (20%), and NH lymphomas were some of the atypical extra pulmonary manifestations.^{10–14} They are also at risk of developing autoimmune features like neutropenia, thrombocytopenic purpura or hemolytic anemia.^{15,16} However, we did not encounter such manifestations in our case. There was no organomegaly or lymphadenopathy or hepatitis.

Among the list of complications recurrent pneumonia and chest infections leading to late bronchiectasis in CVID was reported to be present in up to 17 to 76% (avg 20%) of patients.^{16,17} In our case also search for etiology of bronchiectasis lead to CVID.

CVID patients may present with complication of restrictive interstitial lung disease with parenchymal lesions on HRCT thorax scan. Lung biopsy on histopathological examination shows granulomatous and lymphoproliferative patterns like lymphocytic interstitial pneumonitis or follicular bronchiolitis or lymphoid hyperplasia. Hence the term granulomatous lymphocytic interstitial lung disease (GLILD) was coined to describe it with prevalence around 10–25% of patients with CVID.^{18–24} GLILD can be progressive with limitation in lung function leading to morbidity and mortality with shortening of median survival from 28 years to 14 years.¹⁹ However, in our case we could not get a lung biopsy done as the focal consolidation resolved on treatment spontaneously despite culture reports being sterile. His BAL cytology report was lymphocyte predominant ($> 25\%$). Hence, we considered the possibility of left lower lobe patchy consolidation to be COP or GLILD that resolved during ongoing IgG therapy and antibiotics.

More over during recovery he also developed right sided pleural effusion which was exudative, lymphocyte predominant with ADA 45 U/L favoring Tubercular etiology. Though his sputum and BAL cultures were negative for AFB and Gene xpert. Probably this is the first case we are presenting with CVID complicating with COP or GLILD and Tubercular pleural effusion as per our reference searches.

CVID patients can be classified into 5 types based on phenotype- 1. Autoimmunity 2. Polyclonal lymphocytic infiltration 3. Enteropathy 4. Lymphoid malignancy 5. No complication. This was highlighted in CVID registry in Europe by the European Society for Immunodeficiency.²⁵ Significant overlap exists between these phenotypes. Common overlap is seen among lymphoproliferative phenotype (GLILD, splenomegaly, and adenopathy) with autoimmune cytopenias, gastrointestinal,

and hepatic disease.^{11–13,23,24} However in our case we did not encounter any autoimmune cytopenia or evidence of any malignancy in this 16-year-old boy.

Initiation of early appropriate management is the clinical corner stone in CVID patients to prevent delay and its inevitable consequences. The baseline treatment of CVID based on pathology is replacement of antibody by either an intravenous or subcutaneous route. Conventional recommended doses is 400 to 600 mg/kg body weight every month based on monitoring of serum immunoglobulin level.¹ Our patient is receiving a dose (400mg/kg) based on consultation from the Department of Pediatrics. Dosing regime is every 2 weeks (subcutaneous route) or every 3 to 4 weeks (intravenous route). Besides treating him with empirical antibiotics for a duration of 10 days, he is also on Antitubercular therapy for his pleural effusion. Clinically he improved with gain in weight, wheezing subsided, resolution of chest pain and patchy consolidation. He was vaccinated with Influenza & Pneumococcal vaccine 23 serotype during discharge. He will be followed up for prolonged IVIG therapy based on serum level of IgG and ATT therapy.

4. Conclusion

Quest for etiology of bronchiectasis is important, mere detection is not enough. Hence high degree of suspicion for immunodeficiency as cause and its work up is needed for patient's better good and future productive life. In this case search for etiology of bronchiectasis, negative Aspergillus work up and low level of IgG, IgE, IgA & IgM clinched the diagnosis. Though IVIG therapy can provide significant improvement in these patients, early diagnosis always prevents morbidity and mortality with improved future prognosis.

5. Source of Funding

None.

6. Conflicts of Interest

None declared.

7. Acknowledgment

Nil.

References

- Resnick ES, Moshier EL, Godbold JH, Cunningham-Rundles C. Morbidity and mortality in common variable immune deficiency over 4 decades. *Blood*. 2012;119(7):1650–7.
- Chapel H, Lucas M, Lee M. Common variable immunodeficiency disorders: division into distinct clinical phenotypes. *Blood*. 2008;112:277–86.
- Stray-Pedersen A, Abrahamsen TG, Ss F. Primary immunodeficiency diseases in Norway. *J Clin Immunol*. 2000;20:477–85.
- Fasth A. Primary immunodeficiency disorders in Sweden: Cases among children, 1974?1979. *J Clin Immunol*. 1982;2(2):86–92.
- Urschel S, Kayikci L, Wintergerst U, Notheis G, Jansson A, Belohradsky BH. Common Variable Immunodeficiency Disorders in Children: Delayed Diagnosis Despite Typical Clinical Presentation. *J Pediatr*. 2009;154(6):888–94.
- Cunningham-Rundles C. How I treat common variable immune deficiency. *Blood*. 2010;116(1):7–15.
- Agarwal S, Cunningham-Rundles C. Autoimmunity in common variable immunodeficiency. *Curr Allergy Asthma Rep*. 2009;9(5):347–52.
- Geha RS, Notarangelo LD, Casanova JL, Chapel H, Conley ME, et al. Primary immunodeficiency diseases: An update from the International Union of Immunological Societies Primary Immunodeficiency Diseases Classification Committee. *J Allergy Clin Immunol*. 2007;120:776–94.
- Gelfand EW. Unique susceptibility of patients with antibody deficiency to mycoplasma infection. *Clin Infect Dis*. 1993;17(1):250–3.
- Yong PFK, Thaventhiran JED, Grimbacher B. A rose is a rose is a rose," but CVID is not CVID: Common variable immune deficiency (CVID), what do we know in 2011? In: WA F, editor. *Advances in Immunology*. Academic Press; 2011. p. 47–107.
- Khodadad A, Aghamohammadi A, Parvaneh N. Gastrointestinal manifestations in patients with common variable immunodeficiency. *Dig Dis Sci*. 2007;52:2977–983.
- Park JH, Levinson AI. Granulomatous-lymphocytic interstitial lung disease (GLILD) in common variable immunodeficiency (CVID). *Clin Immunol*. 2010;134(2):97–103.
- Malamut G, Ziol M, Suarez F, Beaugrand M, Viallard JF, et al. Nodular regenerative hyperplasia: The main liver disease in patients with primary hypogammaglobulinemia and hepatic abnormalities. *J Hepatol*. 2008;48(1):74–82.
- Sander CA, Medeiros LJ, Weiss LM, Yano T, Sneller MC, Jaffe ES. Lymphoproliferative Lesions in Patients with Common Variable Immunodeficiency Syndrome. *Am J Surg Pathol*. 1992;16(12):1170–82.
- Roifman CM, Rao CP, Lederman HM, Lavi S, Quinn P, Gelfand EW. Increased susceptibility to mycoplasma infection in patients with hypogammaglobulinemia. *Am J Med*. 1986;80(4):590–94.
- Busse PJ, Farzan S, Cunningham-Rundles C. Pulmonary complications of common variable immunodeficiency. *Ann Allergy Asthma Immunol*. 2007;98(1):1–8.
- Bates CA, Ellison MC, Lynch DA, Cool CD, Brown KK, Routes JM. Granulomatous-lymphocytic lung disease shortens survival in common variable immunodeficiency. *J Allergy Clin Immunol*. 2004;114(2):415–21.
- Arnold DF, Wiggins J, Cunningham-Rundles C, Misbah SA, Chapel HM. Granulomatous disease: Distinguishing primary antibody disease from sarcoidosis. *Clin Immunol*. 2008;128(1):18–22.
- Buckley RH. Pulmonary complications of primary immunodeficiencies. *Paediatr Respir Rev*. 2004;5:S225–S33.
- Mechanic LJ, Dikman S, Cunningham-Rundles C. Granulomatous disease in common variable immunodeficiency. *Ann Intern Med*. 1997;127(1):613–7.
- Popa V. Lymphocytic interstitial pneumonia of common variable immunodeficiency. *Ann Allergy*. 1988;60:203–6.
- Chapel H, Lucas M, Patel S, Lee M, Cunningham-Rundles C, et al. Confirmation and improvement of criteria for clinical phenotyping in common variable immunodeficiency disorders in replicate cohorts. *J Allergy Clin Immunol*. 2012;130(5):1197–8.
- Morimoto Y, Routes JM. Granulomatous disease in common variable immunodeficiency. *Curr Allergy Asthma Rep*. 2005;5(5):370–5.
- Daniels JA, Lederman HM, Maitra A, Montgomery EA. Gastrointestinal Tract Pathology in Patients With Common Variable Immunodeficiency (CVID). *Am J Surg Pathol*. 2007;31(12):1800–12.
- Wehr C, Kivioja T, Schmitt C. The EUROclass trial: Defining subgroups in common variable immunodeficiency. *Blood*. 2008;111:77–85.

Author biography

Somnath Bhattacharya Senior Resident

Saurabh Karmakar Associate Professor

Cite this article: Bhattacharya S, Karmakar S. A tale of a young boy with recurrent wheezing and uncommon bronchiectasis. *IP Indian J Immunol Respir Med* 2020;5(1):60-64.