



Original Research Article

Evaluation of Bronchial washings vs Bronchial biopsy in diagnosing lung disorders- A clinical study at Konaseema area of Andhra Pradesh in 2018-19

Bhargav Prasad Bathula^{1,*}, Ravi Kumar Pentakota¹, Vijender Malloth¹,
Bhima Sankar Duvvuri¹, Subba Rao Polamati¹

¹Dept. of Pulmonary Medicine, Konaseema Institute of Medical Sciences & Research, Amalapuram, Andhra Pradesh, India



ARTICLE INFO

Article history:

Received 07-02-2020

Accepted 19-02-2020

Available online 13-04-2020

Keywords:

Bronchial washings

BAL

Bronchial biopsy

ABSTRACT

Introduction: Patients with bronchopulmonary disorders generally present with cardinal respiratory symptoms, an abnormality on a chest X-ray, or both clinical and radiological findings often lead to diagnostic possibilities. Physical examination, pulmonary function tests, other imaging studies, and bronchoscopic examination are done to refine the differential diagnosis. The diagnostic methods available for evaluating the patient with the suspected or known bronchopulmonary disease and involve direct visualization of part of the tracheobronchial tree. Flexible type is the most common type of bronchoscopy, visualizes the trachea, proximal airways, and segmental airways out to the third generation of branching and bronchial collections.

This study aimed at interpretation of bronchial washings 'obtained from the lungs in various bronchopulmonary disorders and correlation with bronchoscopic biopsy.

Objectives: In many bronchopulmonary disorders, diagnosis is not possible despite consideration of the clinico-radiological results, it is often necessary to obtain cells and tissue for cytologic and pathologic examination for definitive diagnosis.

Materials and Methods: We did routine FOB and obtained bronchial washings and bronchial biopsy to know which is more useful in clinching diagnosis.

Results: No significant correlation has been observed between BAL and bronchoscopic biopsy results.

Conclusions: Bronchoalveolar lavage is a useful diagnostic tool in diagnosing bacterial pneumonia, tuberculosis lesions, fungal infections, and malignancies.

© 2020 Published by Innovative Publication. This is an open access article under the CC BY-NC-ND license (<https://creativecommons.org/licenses/by/4.0/>)

1. Introduction

Physical examination, pulmonary function tests, other imaging studies, and bronchoscopic examination are done to refine the differential diagnosis in bronchopulmonary disorders.¹ The diagnostic methods available for evaluating the patient with the suspected or known bronchopulmonary disease and involve direct visualization of part of the tracheobronchial tree.² Flexible type is the most common type of bronchoscopy,³ visualizes the trachea, proximal airways, and segmental airways out to the third generation of branching and bronchial collections.

In many bronchopulmonary disorders, diagnosis is not possible despite consideration of the clinico-radiological results, it is often necessary to obtain cells and tissue for cytological and pathologic examination for definitive diagnosis.⁴

With increasing recognition of bronchogenic carcinoma early in this century, the examination of sputum and bronchial washings for malignant cells became an essential investigative technique.⁵ Bronchoalveolar lavage (BAL) is one among various procedures which provide sequential access to well-preserved cells to study the natural history of disease processes.⁵ Dr. Shigeto Ikeda, introduced the first commercially available flexible fiberoptic bronchoscope in 1967. The technique was quickly adapted for use

* Corresponding author.

E-mail address: bathula1961@gmail.com (B. P. Bathula).

in sampling the contents of the lower respiratory tract utilizing subsegmental BAL, and it became a major tool of clinical investigators.^{6,7} FOB has a major role in the diagnosis of bronchopulmonary disorders, by bronchial washings and BAL for cytological examination, as well as a bronchoscopic biopsy for histopathological diagnosis.⁸ FOB with BAL, usually called liquid biopsy, when appropriately used, can provide the patient and clinician with a safe and potentially excellent means for diagnosis.⁹

This study aims at understanding the uses and interpretation of bronchial washings/bronchoalveolar lavage samples obtained from the lungs in various bronchopulmonary disorders and correlation with bronchoscopic biopsy. Therefore an attempt was made to correlate cytological techniques and histopathological techniques to improve accuracy in diagnosis and evaluation of bronchopulmonary disorders.

2. Aims and objectives

The present prospective study of bronchoalveolar lavage (BAL) was undertaken with the following aims and objectives:

1. To compare and correlate clinico-radiological diagnosis with cytology of bronchial washings/bronchoalveolar lavage and histopathological findings of bronchoscopic biopsy in patients with bronchopulmonary disorders
2. To study the utility of bronchial cytology in diagnosing bronchopulmonary lesions.
3. To determine the sensitivity, specificity, and diagnostic accuracy of bronchial cytology in detecting neoplastic and non-neoplastic bronchopulmonary disorders.

3. Materials and Methods

The present prospective study was undertaken post ethical committee clearance and after obtaining consent of study subjects, in the Department of Pulmonology, Konaseema institute of medical sciences, and research foundation, Amalapuram, India between January 2018 to July 2019.

The material consisted of 100 BAL and bronchoscopic biopsy samples from adult patients. They all presented with respiratory symptoms and bronchopulmonary lesions on the clinico-radiological examination, which was confirmed by chest radiographs and computed tomography of the chest. A bronchoscopic examination followed by bronchial washings/bronchoalveolar lavage followed by a bronchoscopic biopsy, which was done by alligator biopsy forceps (Figure 2), was advocated in all of them for further evaluation.

The procedure was done using a flexible fiberoptic video bronchoscope (Olympus Bf Type 1T150 model) (Figure 1) in a well-equipped bronchoendoscopy room.



Fig. 1: Flexible fiberoptic video bronchoscope (OLYMPUS BF TYPE 1T150 model)

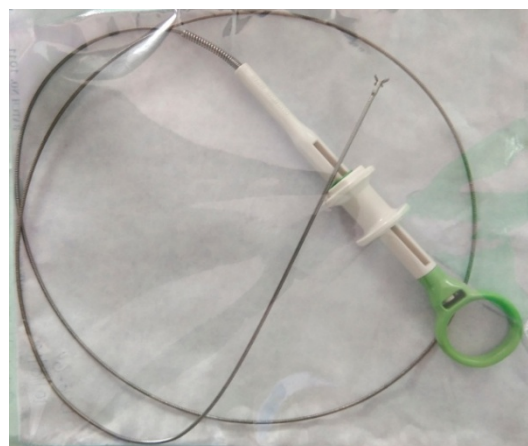


Fig. 2: Alligator biopsy forceps

3.1. Inclusion criteria

1. Age \geq 15 years
2. Both sexes
3. Patients were clinical, and routine laboratory investigations did not clinch a diagnosis
4. Undiagnosed opacities on chest radiography like collapse, consolidation, hilar mass, pleural effusion, and cavity.
5. Hemodynamically stable patients.

3.2. Exclusion criteria

1. Patients not willing to participate in the study,
2. Age $<$ 15 years,
3. Normal CT findings
4. Patients with recent cardiac arrhythmias, recent myocardial infarction, Uncorrectable hypoxia, uncorrectable thrombocytopenia, dearranged coagulation

profile.

3.3. Selection of the patient for the procedure

Prior to the procedure of bronchoscopy, the clinical details, along with the descriptions of other relevant investigations like radiological, hematological, and biochemical parameters, were done. Further investigations like pulmonary function tests (PFTs), arterial blood gas (ABG) analysis were also done in conditions that involved an increased risk of complications from the procedure.

Based on the above parameters, the fitness of the patient for the procedure was assessed.

3.4. Patient preparation and premedication

The pre-bronchoscopy screening was done with history, physical examination, BT, CT, PT, platelet count, fresh X-ray chest PA, and lateral views and ECG, sputum smear for AFB on three consecutive days, xylocaine sensitivity test. Injection atropine 0.6 mg intramuscularly was given 30 minutes prior to the procedure to control secretions, minimize bronchospasm, and block the vasovagal reflex. All the patients were nebulized with 5 ml of 4% xylocaine for 15 minutes to anesthetize the respiratory mucosa. Local anesthesia was achieved by spraying the oropharynx with 4-5 ml of 4% xylocaine. The total dose of xylocaine never exceeded 400mg. A small amount of additional 2% lignocaine was used during bronchoscopy to suppress coughing.

3.5. Methods

After obtaining well-informed written consent, all the bronchoscopies were performed as an elective procedure. Food and drinks were withheld at least 6 hours prior to bronchoscopy. On the day of bronchoscopy, the level of oxygenation was assessed by pulse oximetry and also monitored throughout the procedure.

3.6. Localization

The lesions were accurately localized with posteroanterior, lateral chest Radiographs, and CT Chest before bronchoscopy.

3.7. Position

The patient was made to lie in a supine position, and both nostrils were examined. The more patent nostril was chosen for a bronchoscopy.

3.8. Procedure

The flexible fiberoptic video bronchoscope (Olympus Bf Type 1T150 model) was treated with a suitable lubricant and antifogging agent. Its tip was introduced into patent nostril

or mouth (in case of difficult nasal intubation).

Under direct vision, the bronchoscope was advanced slowly, and the nasopharynx carefully inspected. After the uvula and base of the tongue were seen and passed, the epiglottis was identified, and the flexible tip directed posteriorly. With slight advancement, both the arytenoids and the vocal cords were visualized, and further local anesthetic was instilled in this area. If the cords and larynx were normal, the fiberscope was introduced into the trachea.

A thorough systematic inspection of accessible airways and segments was done. The lung opposite the one with radiographic abnormality was examined first to ensure a complete evaluation. Then the bronchoscope was wedged into a distal segment of the identified area with lesion and sterile normal saline (0.9%) at room temperature or warmed to 27°C was instilled (about 100-150ml) as 20 ml aliquots. The instilled saline was aspirated through the suction channel of the bronchoscope and collected directly into a sterile container without any fixative. The total amount of fluid introduced and aspirated was noted.

The aspirated bronchial washing/bronchoalveolar lavage (BAL) sample was divided into aliquots in sterile labeled containers without adding any fixative and sent immediately for cytological examination.

For lesions that were visible through the bronchoscope and located straight ahead, the tip of the bronchoscope was flexed as far as possible so that opened forceps could be jammed against the surface of the lesion. 3 or 4 biopsies were taken in each visible lesion. The biopsy material obtained by forceps was transferred to a test tube/jar containing 10% formalin and sent for histopathological examination.

3.9. Statistical analysis

Statistical analysis was performed using SPSS (statistical package for social sciences) statistics, Version 23 (BM SPSS statistics, Somers NY, USA)

A probability value of less than 0.05 was considered significant.

The following statistical methods were applied in the present study.

3.10. Chi-Square Test

The Chi-Square Test procedure tabulates a variable into categories and computes a chi-square statistic. This goodness-of-fit test compares the observed and expected frequencies in each category to test either that all categories contain the same proportion of values or that each category contains a user-specified proportion of values.

True positive + true negative

Diagnostic accuracy was calculated as = $\frac{\text{True positive} + \text{true negative}}{\text{True positive} + \text{false positive} + \text{True negative} + \text{false negative}} \times 100$

True positive + false positive +

True negative + false negative

4. Result

The study was undertaken in adult patients only, who presented with respiratory symptoms and radiologically visible pulmonary lesions in whom other diagnostic modalities did not lead to a definitive diagnosis.

Out of 100 cases, 61(61%) were males, and 39(39%) were females. The male to female ratio was 1.56:1.

Table 1: Sex distribution of all cases

S. No	Sex	No of cases	Percentage
1	Male	61	61 %
2	Female	39	39 %
	Total	100	100%

From Table 1, it is observed that there were a greater number of males in the present study.

Table 2: Age distribution of all cases

Age group (in years)	No. of cases		Total
	Male	Female	
11-20	3	0	3
21-30	1	3	4
31-40	7	10	17
41-50	10	8	18
51-60	21	12	33
61-70	12	5	17
71-80	6	1	7
81-90	1	0	1
Total	61	39	100

Chi-square value = 5.01 ; P = 0.1714 (NS)

Table 2 show that the maximum number of cases was found in the age group of 51 to 60 years, comprising a total of 33% (33 cases) of the study population. No significant association was observed between the age and sex of the patients. However, the least number of cases were seen in the age group of 81 to 90 years among males comprising only 1% of the study population. Among females, no cases were found in the age groups of 11 to 20 years and 81 to 90 years.

Table 3: Showing mean age and standard deviation of the cases according to sex

	Male	Female	Both
Mean (years)	54.74	48.64	52.36
SD (years)	14.76	12.9	14.37

t=2.1544; P = 0.0339 (S) < 0.05

From Table 3 it is observed that the mean age for males was 54.74 years with a standard deviation (SD) of 14.76 years, and the mean age for females was 48.64 years with an SD of 12.9 years. The difference was observed between male and female patients in their mean age. The mean age for both the sexes was 52.36 years, with an SD of 14.37

years. The youngest patient among males was 17 years old, and the oldest patient was 85 years old. The youngest patient among females was 24 years old, and the oldest patient was 72 years old.

Table 4: Smoking habit distribution of all cases

Habit	Male	Female	Total
Smoker	49(80.33%)	3(7.69%)	52(52%)
Non-smoker	12(19.67%)	36(92.31%)	48(48%)
Total	61	39	100

Chi-square = 50.29; P = 0.0000 (HS)

Table 4 show that a significantly higher number of smokers (49 cases) were present among the male population (80.33 %), contributing to a higher percentage among the study population. Among female patients, 36 are Non-smokers, and 3 were smokers.

Out of 100 cases, the cytologic diagnosis of malignancy was given in 14 cases, and 48 cases were diagnosed as non-neoplastic lesions.

Among 48 cases of non-neoplastic lesions, 39 cases were infective lesions, and 9 cases were inflammatory lesions. The sample was inconclusive to evaluate in 38 cases.

In our study, the majority of BAL samples showed features of infective lesions comprising of 39 cases (39%) followed by 14 cases (14%) of malignancy and 9 cases (9%) of inflammatory lesions. The sample was inconclusive in 38 cases (38%). The infective lesion and malignant lesions were more in males (Table 7).

From the Table 8, it is observed that among males, no malignant lesion was seen in the age groups of 11-20, 21-30, and 81-90 years. Malignant lesions were seen only in the 3rd to 7th decades. Whereas in females, no malignant lesion was seen in the age groups of 11-20, 21-30, 71-80, and 81-90 years. Malignant lesions were seen only in the 3rd to 6th decades. And it is observed that among males, infective lesions seen in all age groups. Whereas in females, no infective lesions were seen in the age groups of 11-20, 71-80 and 81-90 years. Infective lesions were seen only in the 2nd to 6th decades.

The maximum number of infective lesions, inflammatory lesions, and malignant lesions were seen in the age group of 51-60 years.

In our study, the majority of biopsy samples (69 cases) are inadequate, and there are 15 cases (15%) of malignant lesions followed by 8 cases (8%) each of infective lesions and interstitial lung disease. Malignant lesions were more in males (Table 9).

From the Table 8, it is observed that 45 cases are suspected clinico-radiologically as infective lesions of that only BAL positive are 31 cases, zero cases of only Biopsy positive, both BAL & Biopsy positive are 8 cases and 6 cases of both BAL & Biopsy inconclusive.

Twenty-seven cases are suspected clinico-radiologically as malignant lesions of that only BAL positive are 8 cases, 9

Table 5: Cytological diagnosis in 100 BAL samples

S. No.	Lesion	No. of cases		Total
		Male	Female	
1	Malignant	8 (13.11%)	6(15.38%)	14
2	Infective	24(39.34%)	15(38.46%)	39
3	Inflammatory	4(6.56%)	5(12.82%)	9
4	Inconclusive	25(40.98%)	13(33.33%)	38
	Total	61	39	100

Chi-square =1.50; P =0.6832 (NS)

Table 6: Age and sex-wise distribution of lesions diagnosed in BAL

S. No.	Age group (in years)	Infective lesions		Inflammatory lesions		Malignant lesions	
		Male	Female	Male	Female	Male	Female
1	11-20	1(4.17%)	-	-	-	-	-
2	21-30	3(12.5%)	4(26.6%)	-	-	-	-
3	31-40	2(8.33%)	4(26.6%)	1(25%)	1(20%)	1(12.5%)	2(33.33%)
4	41-50	3(12.5%)	4(26.6%)	-	1(20%)	2(25%)	1(16.67%)
5	51-60	8(33.3%)	2(13.3%)	3(75%)	3(60%)	3(37.5%)	2(33.33%)
6	61-70	4(16.6%)	1(6.67%)	-	-	1(12.5%)	1(16.67%)
7	71-80	2(8.33%)	-	-	-	1(12.5%)	-
8	81-90	1(4.17%)	-	-	-	-	-
Total		24	15	4	5	8	6
	CC.	8.74		1.83		1.61	
	P value	0.2718(NS)		0.6786(NS)		0.8063(NS)	

Table 7: Histopathological diagnosis in 100 biopsy samples

S. No.	Type of Lesion	No. of cases		Total
		Male	Female	
1	Malignant	13(21.31%)	2(5.13%)	15(15%)
2	Infective	5(8.2%)	3(7.69%)	8(8%)
3	ILD	4(6.56%)	4(10.26%)	8(8%)
4	Inadequate	39(63.93%)	30(76.92%)	69(69%)
	Total	61(100%)	39(100%)	100(100%)

Chi-square value=5.15; p=0.1611 (NS)

Table 8: Comparison of clinicoradiological diagnosis, cytologic diagnosis of BAL with histopathological diagnosis

Lesion	Clinico radiological diagnosis	BAL positive	Biopsy positive	Both BAL and biopsy positive	Both inconclusive
Infective	45	31	0	8	6
Malignant	27	8	9	6	4
Inflammatory	24	4	5	3	12
Nonspecific	4	2	0	0	2
Total	100	45	14	17	24

Chi-square value=38.68; P=0.0000 (HS)

cases of only Biopsy positive, both BAL & Biopsy positive are 6 cases and 4 cases of both BAL & Biopsy inconclusive.

Twenty-four cases are suspected clinico-radiologically as inflammatory lesions of that only BAL positive are 4 cases, 5 cases of only Biopsy positive, both BAL & TBLB positive are 3 cases and 12 cases of both BAL & Biopsy inconclusive.

Four cases are a nonspecific diagnosis of that only BAL positive are 2 cases, zero cases of only Biopsy positive, and

both BAL & Biopsy positive and 2 cases of both BAL & Biopsy inconclusive.

4.1. Infective lesions

In the present study, the maximum number of cases (39 cases) were diagnosed cytologically as infective lesions. This included 24 cases of males and 15 cases of females.

The Table 9 shows that out of the total 39 cases, 20 cases (51.28%) were positive in Zn stain/CBNAAT and diagnosed

Table 9: Clinical subgroup distribution of Infective lesions

S. No	Type of infective lesion	No of cases		Total
		Male	Female	
1	Zn stain/CBNAAT Positive	15(62.5%)	5(33.33%)	20(51.28%)
2	Bacterial culture positive	8(33.33%)	9(60%)	17(43.59%)
3	KOH mount positive	1(4.17%)	1(6.67%)	2(5.13%)
	Total	24(100%)	15(100%)	39(100%)

Chi-square value=3.14; P=0.0762 (NS)

as pulmonary tuberculosis, 17 cases (43.59%) are positive in bacterial culture, and 2 cases (5.13%) came out as positive in KOH mount diagnosed as aspergillus infection.

4.2. Aspergillosis

In the present study, 2 cases of aspergillosis were diagnosed cytologically by bronchial washings.

4.3. Inflammatory lesions

In the present study, 9 cases were diagnosed cytologically as inflammatory lesions. This included 4 cases (6.56%) of males and 5 cases (12.82%) of females.

4.4. Interstitial Lung Disease (ILD)

In a total of 100 cases, 8 cases were clinically diagnosed as having ILD.

The Table 11 shows that there was no significant association between the distribution of the lesion and sex of the patient. The majority of the cases (40%) were squamous cell carcinoma (6 cases), 4 cases were Adenocarcinoma, and 2 cases of poorly differentiated carcinoma. There was one case each of pulmonary maltoma, Large cell carcinoma, and small cell carcinoma.

In the present study, cytohistopathological correlation could be performed in 100 cases. In 41% of cases, a good cytohistopathological correlation was achieved, while 59% of cases showed discordance. Overall sensitivity and specificity of cytology in the evaluation of lung diseases were found to be 54.84% and 34.78%, respectively. Cytological accuracy achieved in our study was 41%. The positive predictive and negative predictive values were 27.42% and 63.16%, respectively.

The sensitivity, specificity, and diagnostic accuracy of different pulmonary lesions on BAL cytology were calculated with histopathology as the gold standard.

5. Discussion

A total of 100 cases of bronchoalveolar lavage samples undertaken, out of these, 61 cases (61%) were males, and 39 cases (39%) were females showing a male to female ratio of 1.56:1. The majority of the patients 33 cases (33%) in the present study were within the age group of 51-60 years, indicating the higher prevalence of the respiratory disease in

the elderly population group. History regarding the smoking habit revealed that a significant number of 52 cases (52%) were smokers. This implies that smoking is a major risk factor in the development of pulmonary disease mostly in males.

5.1. Pulmonary tuberculosis

Patients with positive tuberculin test and abnormal chest radiographs pose a diagnostic dilemma to clinicians. Bronchoscopy is useful in such cases to obtain lavage, where other modalities are not contributory. In a study by Baughman et al.,¹⁰ 87% of bronchoscopy specimens were positive for tuberculosis. In our series, 69.2% of the infective cases were diagnosed as tuberculosis. De Gracia J et al., in 1988, after a study on 222 cases of suspected pulmonary tuberculosis, concluded that BAL is an extremely useful procedure to diagnose pulmonary tuberculosis.¹¹ In the present study, out of 100 cases, 13 cases were clinically diagnosed as having tuberculosis. Jain et al.¹² in their study, suggested that the diagnostic yield of fiberoptic bronchoscopy was 70% in suspected cases of pulmonary TB with sputum for AFB negative. Neutrophilic predominance in BAL fluid of clinically suspected pneumonia was 62.5% in our study compared with 100% by Thorpe et al.¹³ Fungal infections: In the present study, 2 cases of aspergillosis were diagnosed cytologically by bronchial washings, one of which is Invasive Aspergillosis 35 year/male who is immunocompromised.

5.2. Malignant lesions

In our study, 14 cases were cytologically diagnosed as malignant, in which only 6 cases are diagnosed as malignant histopathologically.

The prospective study by de Gracia et al., in 1993¹⁴ showed that BAL was positive for lung cancer in 24 cases (43.6%) out of 55 cases found to have the malignant disease of the lung. Debeljek et al., in 1994¹⁵ reported that in their study of 61 patients with lung malignancies, BAL fluid showed malignant cells in 17 patients (27.87%). After a prospective study of 30 patients with lung cancer, Wongsurakiat et al., in 1998¹⁶ reported that BAL was positive for malignant cells in 14 patients (46.7%).

Table 10: Clinical subgroup distribution of ILD

S. No	Type of ILD	No of cases		Total
		Male	Female	
1	Sarcoidosis	1(25%)	2(50%)	3(37.5%)
2	HP	1(25%)	0(0%)	1(12.5%)
3	NSIP	0(0%)	2(50%)	2(25%)
4	RBILD	1(25%)	0(0%)	1(12.5%)
5	COP	1(25%)	0(0%)	1(12.5%)
	Total	4(100%)	4(100%)	8(100%)

Chi-square= 5.33; P=0.2548 (NS).

Table 11: Distribution of malignant lesions on histopathology

S. No	Type of malignancy	No of cases		Total
		Male	Female	
1	Squamous cell carcinoma (SCC)	6(46.15%)	0(0%)	6(40%)
2	Adeno carcinoma (Adeno CA)	2(15.38%)	2(100%)	4(26.67%)
3	PDCC	2(15.38%)	0(0%)	2(13.33%)
4	Pulmonary maltoma	1(7.69%)	0(0%)	1(6.67%)
5	Large cell carcinoma (LCC)	1(7.69%)	0(0%)	1(6.67%)
6	Small cell carcinoma(SmCC)	1(7.69%)	0(0%)	1(6.67%)
	Total	13(100%)	2(0%)	15(100%)

Chi-square Value=6.35; P=0.2739 (NS)

Table 12: Showing histopathological correlation of BAL cases

Lesions	Total	C	NC	Diagnostic Accuracy (%)
Malignant	27	10	17	37.04
Inflammatory	24	15	9	62.5
Infective	45	14	31	31.11
Non specific	4	2	2	0
Total	100	41	59	41

C= correlated; NC = Not correlated

Table 13: 2 X 2 Table for comparison of BAL cytology with histopathology of biopsy for total lesions

Lesions	Total	C	NC	Diagnostic Accuracy (%)
Malignant	27	10	17	37.04
Inflammatory	24	15	9	62.5
Infective	45	14	31	31.11
Non specific	4	2	2	0
Total	100	41	59	41

Table 14: Sensitivity, specificity, and diagnostic accuracy of total lesions

Statistic	Value	95% CI
Sensitivity	54.84%	36.03% to 72.68%
Specificity	34.78 %	23.71% to 47.21%
Positive Likelihood Ratio	0.84	0.58 to 1.21
Negative Likelihood Ratio	1.30	0.78 to 2.15
Disease prevalence	31.00% (*)	22.13% to 41.03%
Positive Predictive Value	27.42% (*)	20.81% to 35.19%
Negative Predictive Value	63.16 % (*)	50.85% to 73.96%
Accuracy	41.00% (*)	31.26% to 51.29%

In the present study, out of the 15 cases of malignant lesions diagnosed in the biopsy, only 6 cases (40%) had shown malignant cells in BAL. It is observed that the diagnostic accuracy for malignancy by BAL study was highest in the study by Linder et al.,¹⁷ (68.6%) and a lower accuracy rate of 27.9% was noted in a study by Debeljek A et al.¹⁸ However in the present study the diagnostic accuracy was 40% and had a near correlation with the study by de Gracia et al.,¹⁹ (43.6%).

In the present study, it was noted that 14 cases showed malignant cells in BAL fluid in which 6 cases showed malignant lesion also in bronchoscopic biopsy specimens.

Most of the patients with carcinoma in the study by Linder et al.,¹⁷ were smokers, and they had neutrophils predominantly in the background of malignant cells obtained by BAL fluid. In the present study, all the male patients with BAL diagnosis of malignancy were smokers and showed neutrophilic predominance in the background of malignant cells in BAL smears.

5.3. Interstitial lung disease

In the present study, a total of clinically diagnosed 24 ILD cases were present. Of these cytologically 9 cases are inflammatory 3 cases are diagnosed as ILD and remaining 17 cases are inconclusive, and histopathologically 3 cases were of sarcoidosis shows non-caseating granuloma, 2 cases were diagnosed as NSIP, 1 case each of COP, RB-ILD, HP, and remaining 16 cases were not specified. In the present study involving 3 cases of sarcoidosis both of them showed significantly increased number of lymphocytes in BAL fluid. The present study included a case of COP, which showed the only predominance of lymphocytes in BAL fluid. The same case showed characteristic features of COP in bronchoscopic biopsy as stated by Rosai et al.,²⁰ The combined use of the CD4/CD8 ratio and the CD 103/CD4 ratio to assess lymphocytes in BAL is a promising new tool for the diagnosis of sarcoidosis.²¹

Cytology of pulmonary lesions is a reasonably accurate diagnostic tool with a sensitivity of 54.84% and specificity of 34.78% for both neoplastic and non-neoplastic lesions, if the sample obtained is appropriate, adequate, and representative.

6. Conclusion

Bronchoalveolar lavage is a useful diagnostic tool in diagnosing bacterial pneumonia, tuberculosis lesions, fungal infections, and malignancies. Its role is limited in diagnosing and prognosticating ILDs. In present study, No significant correlation has been observed between BAL and Bronchoscopic biopsy result, the cytological diagnosis by BAL has a higher specificity rate for malignant and infective lesions. The number of lesions with a definite diagnosis outnumber the lesions that cannot be diagnosed; hence, we opine that BAL is a useful diagnostic modality not only

for routine diagnosis but also for ancillary techniques and research purposes.

A multimodality approach is the best for diagnosing pulmonary lesions, and the experience of bronchoscopist is a very crucial factor in the diagnostic yield of bronchoscopy. The yield can improve more with the help of newer technologies like EBUS, fluoroscopic guidance.

7. Source of Funding

None.

8. Conflict of Interest

None.

9. Acknowledgment

None.

References

1. Drajen JM, Weinberger SE. Approach to the patient with disease of the respiratory system. In: Kasper DL, Fauci AS, Longo DL, Braunwald E, Hauser SL, Jameson JL, editors. Harrison's Principles of Internal Medicine. vol. II. New York: Mc Graw Hill; 2005.
2. Weinberger SE, Drazen JM. Diagnostic procedures in respiratory disease. In: Kasper DL, Fauci AS, Longo DL, Braunwald E, Hanser SL, Jameson JL, editors. Harrison's Principles of Internal Medicine. vol. II. New York: McGraw Hill; 2005.
3. Ikeda S. Atlas of flexible bronchoscopy. Baltimore London University park press; 1974.
4. Fraser RS, Colman N, Müller NL, Pare PD. Methods of Pathologic Investigation. In: Fraser and Pare's Diagnosis of Diseases of the Chest. vol. 1;.
5. Gray W. Normal respiratory tract and inflammatory conditions. In: W G, GT M, editors. Diagnostic cytopathology. Edinburgh: Churchill Livingstone; 2003.
6. Sackner MA, Wanner A, Landa J. Applications of Broncho fiber scope. Chest. 1972;62(2):70–8.
7. Cantrell ET, Warr GA, Busbee DL, Martin RR. Introduction of aryl hydrocarbon hydroxylase in human pulmonary alveolar macrophages by cigarette smoking. J Clin Invest. 1973;52:1881–4.
8. Dobler CC, Crawford ABH. Bronchoscopic diagnosis of endoscopically visible lung malignancies: should cytological examinations be carried out routinely? Internal Med J. 2009;39(12):806–11.
9. Goldstein RA, Rohatgi PK, Bergofsky EH, Block ER, Daniele RP, et al. Clinical role of bronchoalveolar lavage in adults with pulmonary disease. Am Rev Respir Dis. 1990;142:481–6.
10. Baughman RP, Dohn MN, Loudon RG, Frame PT. Bronchoscopy with Bronchoalveolar Lavage in Tuberculosis and Fungal Infections. Chest. 1991;99(1):92–7.
11. de Gracia J, Curull V, Vidal R, Riba A, Orriols R, et al. Diagnostic Value of Bronchoalveolar Lavage in Suspected Pulmonary Tuberculosis. Chest. 1988;93(2):329–32.
12. S RKJ, J AB, K PG. Role of fiberoptic bronchoscopy in patients with sputum smear negative for acid fast bacilli and chest X-Ray suggestive of pulmonary tuberculosis. J Evid Based Med Healthc. 2015;2(2):155–64.
13. Thorpe JE, Baughman RP, Frame PT, Wesseler TA, Staneck JL. Bronchoalveolar Lavage for Diagnosing Acute Bacterial Pneumonia. J Infect Dis. 1987;155(5):855–61.
14. Gracia JD, Bravo C, Miravittles M, Tallada N, Orriols R, et al. Diagnostic Value of Bronchoalveolar Lavage in Peripheral Lung Cancer. Am Rev Respir Dis. 1993;147(3):649–52.

15. Debeljak A, Mermolja M, Šorli J, Zupančič M, Zornan M, Remškar J. Bronchoalveolar Lavage in the Diagnosis of Peripheral Primary and Secondary Malignant Lung Tumors. *Respiration*. 1994;61(4):226-30.
16. Wongsurakiat P, Wongbunnate S, Dejsomritrutai W, Charoenratanakul S, Tscheikuna J, et al. Diagnostic value of bronchoalveolar lavage and postbronchoscopic sputum cytology in peripheral lung cancer. *Respirol*. 1998;3(2):131-7.
17. Linder J, Radio SJ, Robbins RA, Ghafouri M, Rennard SI. Bronchoalveolar lavage in the cytologic diagnosis of carcinoma of the lung. *Acta Cytol*. 1987;31:796-801.
18. Debeljak A, Mermolja M, Šorli J, Zupančič M, Zornan M, Remškar J. Bronchoalveolar Lavage in the Diagnosis of Peripheral Primary and Secondary Malignant Lung Tumors. *Respiration*. 1994;61(4):226-30.
19. Shreiber G, Mccrory D. Performance Characteristics of Different Modalities for Diagnosis of Suspected Lung Cancer. *Chest*. 2003;123:115-28.
20. Rosai J. Respiratory tract. In: Rosai and Ackerman's Surgical Pathology, vol. 1. St. Louis: Mosby, Elsevier Inc; 2004.
21. Shidham VB. Respiratory tract cytopathology. In: BF A, editor. Atlas of diagnostic cytopathology. Philadelphia: Saunders: Elsevier Inc; 2004.

Author biography

Bhargav Prasad Bathula Associate Professor

Ravi Kumar Pentakota PG Student

Vijender Malloth Senior Resident

Bhima Sankar Duvvuri Assistant Professor

Subba Rao Polamati Professor and HOD

Cite this article: Bathula BP, Pentakota RK, Malloth V, Duvvuri BS, Polamati SR. **Evaluation of Bronchial washings vs Bronchial biopsy in diagnosing lung disorders- A clinical study at Konaseema area of Andhra Pradesh in 2018-19.** *IP Indian J Immunol Respir Med* 2020;5(1):13-21.